

Common skin conditions affecting the scalp: Tinea Capitis, Pediculosis Capitis, Seborrhoeic Dermatitis, Dandruff, Psoriasis

Jacyk WK, MD

Department of Dermatology, University of Pretoria

Introduction

The structure of the skin and its function varies in the different regions of the body. The scalp with its high density of large hair follicles and abundance of sebaceous glands constitutes a unique area. The scalp is apparently less prone to inflammation. Some dermatological conditions of the scalp will be discussed: dermatophytic infection (tinea capitis) as a common infectious process affecting both the skin and hair; pediculosis capitis, the unique parasitic infestation; and inflammatory diseases, seborrhoeic dermatitis, dandruff and psoriasis.

SA Fam Pract 2003;45(8):54-57

TINEA CAPITIS

Epidemiology

Tinea capitis is caused by a variety of dermatophytes in the genera *Microsporum* and *Trichophyton*. In South Africa it is caused mainly by *Microsporum canis* (white children) and *Trichophyton violaceum* (black children).

Tinea capitis affects mostly children of primary school age. The increased incidence of tinea among prepubertal children has been attributed to reduced fungistatic properties of the child's sebum. However, comparison studies of sebum in prepubertal versus postpubertal children failed to reveal real fungistatic differences. Children contaminate each other with combs, hats, hair care items and the spread of some anthropophilic species like *Trichophyton violaceum* in this way is more common in African children. An infected cat or dog usually serves as the source of infection with *Microsporum canis* in white children. In family outbreaks of this zoophilic species postpubertal individuals are also occasionally affected. Tinea capitis in adults is rare. It must, however, be considered when patients present with atypical scalp lesions. This is of particular significance in the elderly. Whether this increase in frequency in the elderly is secondary to differences in the sebum is speculative.

Clinical picture (Figures 1-4)

The clinical picture of tinea capitis varies greatly and depends mainly on the type of offending agent. In general, zoophilic species produce much more severe inflammation than those which are confined to humans (anthropophilic). In some cases, the inflammation can be minimal with delicate scaling and inappreciable hair loss resembling seborrhoeic dermatitis or atopic dermatitis. In some individuals an asymptomatic carrier state occurs. Most often scalp dermatophytic infection manifests a characteristic loss of hair with "black dots" – which reflects the hair shafts broken within follicular canals (mainly in *Trichophyton violaceum* infection). *Microsporum canis* can cause more severely inflamed lesions with pustules – kerion. This represents an immune reaction to a zoophilic fungus and is not a sign of bacterial superinfection.

Differential diagnosis

The differential diagnosis of tinea capitis includes seborrhoeic dermatitis, pityriasis capitis, atopic dermatitis, psoriasis, furunculosis, alopecia areata and trichotillomania.

Diagnosis

The diagnosis of tinea capitis is based on typical clinical picture – patchy alopecia, broken hairs, scaling, cervical

adenopathy. Confirmation of tinea capitis may be made by direct microscopic examination of an infected hair and by fungal culture. Only culture identifies the species.

Treatment

Tinea capitis needs to be treated with an oral agent because the antifungal remedy has to penetrate into the hair follicle. Sole therapy with topical antimycotic agents is usually ineffective.

Griseofulvin taken orally at a dose of 15-25 mg/kg/day is still the treatment of choice for tinea capitis. As a fatty meal enhances griseofulvin absorption it should be taken during a meal or directly after food. Treatment for 6-8 weeks usually suffices but it is recommended to perform cultures every few weeks and to continue the treatment until the culture is negative.

The main cause of tinea capitis in South African white children, *Microsporum canis*, appears to be highly sensitive to griseofulvin. Griseofulvin is a safe medication and the routine monitoring of hepatic and haemopoietic parameters is rarely necessary in healthy children.

Itraconazole (Sporanox®) has been found to be very effective in tinea capitis. Itraconazole should be dosed according to body weight at about 3 to 5 mg/kg/day. A continuous therapy with itraconazole (100mg/day) for 4-6 weeks

has been reported as very effective.^{1,2} Availability of itraconazole in a liquid formula (Sporanox® oral solution) permits the administration of a more precise dose than using the non divisible capsules. Gupta et al.³ used intermittent pulse therapy, 5mg/kg/day; each pulse lasted one week, with two weeks off the drug between the first and second pulses and three weeks off between the second and third pulses. The third pulse was not necessary in every patient. In this study, itraconazole was found to be effective and resulted in both clinical and mycologic cure. In itraconazole pulse therapy the drug is largely eliminated from the plasma within 7 to 10 days, thereby reducing the potential for adverse effects. Itraconazole should not be used with terfenadine or other nonsedating antihistamines owing to potential combined cardiac toxicity.

Fluconazole (Diflucan®), another azole antifungal, was also found to be a promising drug for tinea capitis.⁴ A continuous treatment with a dose of 5 mg/kg/day for 4 weeks was found effective in cases of tinea capitis caused by *Trichophyton* species. Availability of fluconazole in oral suspension (Diflucan® susp.) makes it a useful alternative in paediatric patients.

Terbinafine (Lamisil®), a member of the allylamine family, is also a useful agent in tinea capitis. It appears very effective in infections with *Trichophyton violaceum*. The dose of 62,5-250 mg/kg/day for 4-6 weeks, depending on body weight, is usually required in infections caused by this fungus. *Microsporum canis* usually requires higher doses and a longer period of administration, 10 to 12 weeks. Terbinafine, initially considered free of any side-effect potential, lost a bit of its innocuous image since with wide use several unwanted effects have been reported (most often blood dyscrasias and hepatotoxicity). It is nevertheless a safe drug and there do not seem to be any absolute contraindications.

PEDICULOSIS CAPITIS (HEAD LICE)

Head lice (*Pediculus humanus capitis*) are transmitted among persons living in unhealthy, crowded conditions and

sharing hats, brushes and combs. Long hair and elaborate styles of hairdressing which prevent frequent washing increase the susceptibility. Head lice is most common in children but no age is immune. The eggs are attached to the hair and when they hatch, numerous nits, resembling dandruff, are left behind. These are seen mainly in the occipital and postauricular regions. Pruritus is the most characteristic manifestation. Scratching often leads to secondary infection and the occipital lymph nodes are frequently enlarged. The diagnosis is often missed when the possibility is not considered. Nits firmly attached to the hair shafts are not easily pulled off. This differentiates them from dandruff scales.

The treatment of choice is to apply Permethrin 1% cream rinse. Application of Permethrin should be preceded by a regular shampooing and towel drying. Permethrin has to be applied to the hair and scalp for 10 minutes and then rinsed off with water. A single treatment is usually sufficient. Permethrin is safe for children over 2 years of age.

An alternative therapy is to apply 10% Crotamiton cream (Eurax). It is left on the scalp for 24 hours and then shampooed. This treatment can be repeated in 7-10 days, if necessary.

SEBORRHOEIC DERMATITIS OF THE SCALP (FIGURES 5 AND 6)

Seborrhoeic dermatitis is a common inflammatory condition presenting clinically as erythematous, scaling eruption, localized to the scalp, eyebrows, postauricular areas, central face, central chest and back and flexural areas, the so-called seborrhoeic areas. Although these lesions are common and are clinically quite distinctive the cause of seborrhoeic dermatitis remains elusive. The seborrhoeic state is associated with increased susceptibility to pyogenic infections and invasion by *Pityrosporum ovale*. Whether *Pityrosporum ovale* causes seborrhoeic dermatitis is not clear. Scalp scales produced by seborrhoeic dermatitis provide a good nutrient for the growth of this lipophilic yeast and increased

presence of *Pityrosporum ovale* may well be a secondary and not primary event.

Clinically seborrhoeic dermatitis of the scalp presents as areas of erythema covered by yellow, greasy scales. Lesions often extend beyond the margins of the hair onto the forehead and behind the ears. Seborrhoeic dermatitis may be associated with transient alopecia.

Treatment

The seborrhoeic state is probably genetically determined and eradication (complete prevention of relapses) in the predisposed individuals is rather unlikely. What can be done is to reduce both scaling and the inflammation.

The scalp should be shampooed frequently, daily or every other day in severe acute phase, less often later on.

There are several medicated shampoos to choose from: selenium sulfide (Selsun®), tar (Polytar®, Alphosyl®), ketoconazole (Nizshampoo®). Alternating different types of medicated shampoos often increases their efficacy. Shampoos should be rubbed into the scalp and left for 5-10 minutes before rinsed out. The length of time the shampoo stays on the scalp appears less important than the frequency of shampooing. In more resistant cases, topical corticosteroids are recommended (Procutane® lotion, Betnovate® scalp application, Diprolene® scalp lotion, Elocon® lotion and others). The degree of scalp inflammation will dictate the potency of the topical corticosteroid used.

The treatment of seborrhoeic dermatitis of the scalp in people of African descent will differ from the above general recommendation. Daily shampooing is too drying for black people hair and rather impractical for many African females with hot-pressed hair. The medicated shampoo should be applied less often, once a week, but for a longer time, 20 to 30 minutes. This shampoo should be followed by a nonmedicated shampoo and the usual moisturizers or conditioners. When the scalp is considerably inflamed or there is no response to the shampoos topical steroids should be applied. Often more fatty vehicles should be used, ointments

rather than lotions and gels, particularly in females with hot-pressed hair.

DANDRUFF (PITYRIASIS CAPITIS)

In dandruff there is desquamation of small, flaky scales from an otherwise normal scalp. The aetiology of dandruff is not clear and the literature is confusing.⁵ It is usually accepted that dandruff and seborrhoeic dermatitis represents two ends of a disease spectrum. Similar remedies, medicated shampoos, were found equally effective in the treatment of both conditions. As in seborrhoeic dermatitis shampoos containing tar, salicylic acid, selenium sulfide and ketoconazole are recommended. Usually twice weekly usage controls the scaling.

PSORIASIS OF THE SCALP (FIGURES 7 AND 8)

Psoriasis affects approximately 2% of the world population and scalp is involved in about 50% of all psoriatics. Usually there are psoriatic lesions elsewhere but the disease can be limited to the scalp.

Psoriasis of the scalp presents as well demarcated erythematous-squamous plaques covered by thick silvery scales. In severe involvement the plaques cover

the entire scalp. Frequently the psoriatic lesions extend beyond the hairline, most often to the forehead and into postauricular regions. Hair loss is not common but does occur especially in severe erythrodermic and pustular psoriasis. It is usually transient as resulting from increased shedding of telogen hairs. If there are no psoriatic lesions elsewhere, it may be very difficult to distinguish psoriasis from seborrhoeic dermatitis. Taking a biopsy does not help.

Treatment⁶

In a patient with extensive psoriasis involving several other than scalp regions systemic treatment with well-established modalities, i.e. methotrexate, cyclosporine, acitretin, leads to clearance of the scalp lesions as well.

Local treatment includes usage of medicated shampoos containing tar, salicylic acid, corticosteroids in lotions or gels and Vit. D analogues.

Firstly, the excess of scales has to be removed. Salicylic acid 5 to 10% exerts a good keratolytic effect. It is formulated in an ointment that can be washed off easily. Patients should apply the formulation overnight, preferably under a bathing or shower cap to enhance the absorption of the medication.

After the removal of the scales topical corticosteroids in lotions, gels

or foams should be applied. The usual application schedule consists of intermittent applications 3 to 4 times weekly. Vitamin D3 analogue calcipotriol (Dovonex®) has a substantial antipsoriatic effect. It is available in a lotion formulation for the treatment of the scalp lesions. It has to be noted that maximum efficacy of calcipotriol lotion is reached after 8 weeks, whereas maximal efficacy of a topical corticosteroid is reached after 2 to 3 weeks treatment. Calcipotriol can be combined with a topical corticosteroid formulation, after descaling, appears at the moment, optimal therapeutic approach for scalp psoriasis. □

References


1. Legendre R, Esola-Macré J. Itraconazole in the treatment of tinea capitis. *J Am Acad Dermatol* 1990, 23:559-560.
2. Greer DL. Treatment of tinea capitis with itraconazole. *J Am Acad Dermatol* 1996, 35:637-638.
3. Gupta AK, Adam P, De Doncker P. Itraconazole pulse therapy for tinea capitis: A new treatment schedule. *Pediatric Dermatol* 1998, 15:225-228.
4. Mercurico MG, Silverman RA, Elewski BE. Tinea capitis: Fluconazole in Trichophyton tonsurans infection. *Pediatric Dermatol* 1998, 15:229-232.
5. Shuster S. The aetiology of dandruff and the mode of action of therapeutic agents. *Brit J Dermatol* 1984, 111:235-242.
6. Van de Kerkhof PC, Franssen ME. Psoriasis of the scalp. Diagnosis and management. *Am J Clin Dermatol* 2001, 2:159-165.

Product News

Zaditen Eye Drops

Adcock Ingram is pleased to announce the launch of Zaditen Eye Drops into the Novartis Ophthalmics range of eye drops from the 20 August 2003.

Each 1 ml of Zaditen Eye Drops contains Ketotifen fumarate 0,345mg equivalent to ketotifen 0,25 mg. Ketotifen has multiple mechanisms of action: It has an antihistaminic effect, a mast cell stabilizing effect and it inhibits eosinophil infiltration, activation and degranulation. This gives Zaditen actions on both the acute early and the late phases of the allergic response treating the signs and symptoms of the allergic response and protection from their recurrence. Zaditen gives symptom relief of allergic conjunctivitis with-



in minutes and lasts for up to 12 hours giving it a convenient BD dosing for adults and children over three years old.

For more information contact Marjolein Bench on 011 709 9300 or marjolein.bench@tigerbrands.com.

S2 Zaditen Eye Drops.Reg. No. 35/15.4/0076. Each 1 ml contains: Ketotifen fumarate 0.345 mg equivalent to Ketotifen 0.25 mg. Preservative: Benzalkonium chloride 0.01% m/v

Adcock Ingram Limited, 1949/034385/06.
PBag X69, Bryanston, 2021. Tel: (011) 709-9300.
Under license from Novartis Pharma Ltd.

Figures 1-4: Various clinical presentations of tinea capitis.

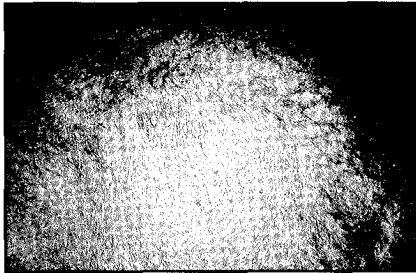


Figure 1: Mildly inflamed, loss of hair, follicular accentuation. Infection caused by *Trichophyton* species.




Figure 2: Small patch of alopecia with scaling caused by *Microsporum canis*.




Figure 5: Seborrhoeic dermatitis. Small, fine scales, no infiltration.

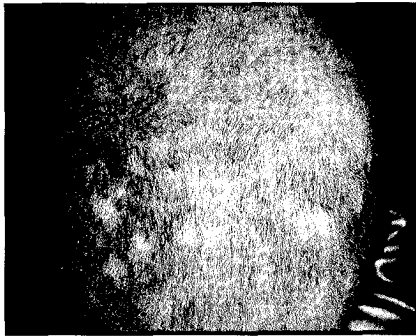


Figure 3: Numerous more inflamed lesions caused by *Microsporum canis*.

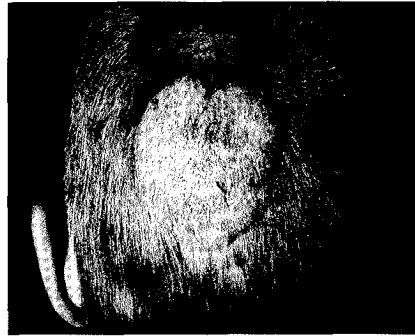

Figure 4: Kerion (*Microsporum canis*)

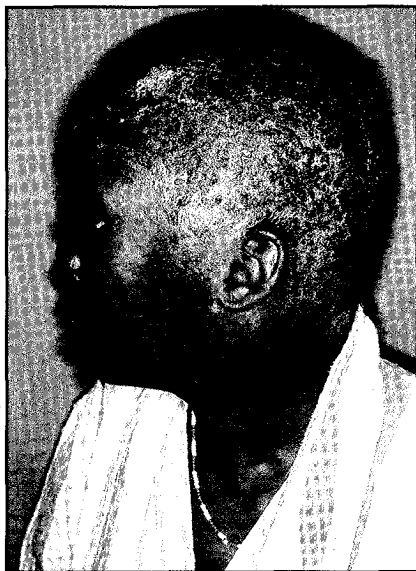

Figure 6: Seborrhoeic dermatitis. Severe involvement, pyogenic superinfection.

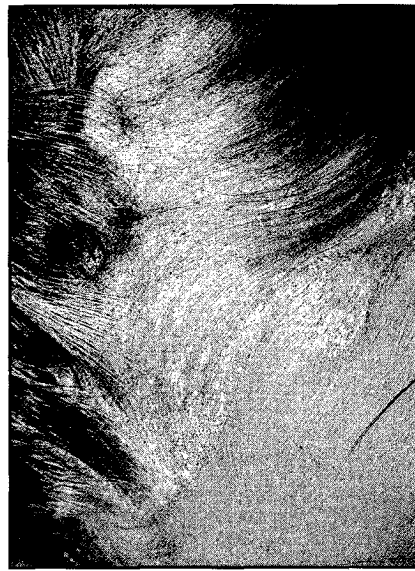

Figure 7: Psoriasis. Clearly defined infiltrated patches with white scales.



Figure 8: Psoriasis. Lesions extend beyond the hair line.