

# Diagnosing Rheumatoid Arthritis

Dr David Gotlieb

Rheumatologist, Constantia Arthritis Clinic, Plumstead, Cape Town

Correspondence: [www.arthritis.co.za](http://www.arthritis.co.za)

## Introduction

- How to make a clinical diagnosis of rheumatoid arthritis.
- Which special investigations should be ordered to confirm the diagnosis?
- In the next issue an article on the diagnosis of osteoarthritis will be presented. In a third article, in July, the treatment differences between these two conditions will be illustrated.
- Hoe om 'n kliniese diagnose van rumatoïede artritis te maak.
- Watter spesiale ondersoeke moet aangevra word om die diagnose te bevestig?
- In die volgende uitgawe gaan die diagnose van osteoarthritis bespreek word. In 'n derde artikel, in Julie, sal die verskille in die behandeling van OA en RA uitgelig word.

SA Fam Pract 2003;45(4):25-30

## INTRODUCTION

Rheumatoid Arthritis (RA) is a **chronic relapsing disease** characterised by **general ill health, chronic synovial inflammation of joint and tendons, and systemic disease**.

It is common - affecting 2% of the female population - with 2.4 million cases estimated in the USA. The Annual incidence of new cases is 48 / 100000 of the population.

There is a definite familial tendency and a female dominance. The mean age at onset is 35-55 years. Onset is acute in 30%, and insidious onset in 70%.

The synovium is the centre of the abnormality in the musculoskeletal manifestations of rheumatoid arthritis. The body loses its ability to differentiate self from non self, and an immune reaction is mounted against self - an autoimmune reaction with resulting inflammation. Erosion of the subchondral bone follows with joint and tendon damage.

The illness usually presents with stiffness and swelling of joints in a polyarticular and symmetrical distribution. However, with time, the disease becomes chronic, and there is erosion and damage to the underlying cartilage and bone. The damage is NOT reversible once the cartilage has been lost, and progression with mechanical

change occurs. Over years, the inflammation will then start to subside, and the symptoms change - to pain later in the day, and less morning stiffness, reflecting mechanical problems. The joints are deformed and function deteriorates due to this deformity.

The basic clinical assessment remains the cornerstone of diagnosis, and the laboratory tests and radiological assessment are adjuncts to this assessment, largely helping to confirm the clinical assessment. The laboratory and radiology are NOT the first line of the diagnostic process.

## THE ASSESSMENT OF THE RA PATIENT

### A. The History

1. Evaluation of the history including onset, duration and distribution of joint disease.
2. Assessment of pain, stiffness and function.
3. A full systematic history, as the condition is a systemic disease.
4. A genetic history may be useful in view of the hereditary aspects of disease.
5. Impact of the disease on daily life.

In fact for a quick assessment four key questions require answering. These are

extremely helpful to differentiate inflammatory versus non-inflammatory symptoms.

1. Is the patient stiff generally in the body?
2. Is the stiffness predominately in the morning? If so, how long does the patient remain stiff?
3. Is there midday fatigue - a strong sign of inflammatory disease.
4. Does the patient get swelling or heat in the joints?

Patients with inflammatory arthritis, typically, are very stiff and this lasts longer than 1 hour after waking. The pain and stiffness in these patients gets better with mobilisation and as the day progresses. In contrast osteoarthritis patients tend to be transiently stiff for seconds to minutes after waking and problems are worse through the day and on activity. Post rest stiffness called gelling is typical lasting seconds to minutes in osteoarthritis patients. Similarly, fatigue and soft tissue swelling are typical of inflammation.

### B. A full comprehensive General, System, and Musculoskeletal examination.

This includes an examination of ALL the joints in the body, and regional

tendon and bursal sites. An assessment of deformity in each joint should also be made. A rheumatological examination should include each joint. Use the 'look, feel and move' technique of examination.

1. **LOOK** for obvious swelling or deformity.
2. **FEEL** for synovitis. This examination technique is not complex, but does require experience. One wants to be able to detect even subtle swelling, a finding in early disease. It is considered unnecessarily late to diagnose only once there is gross swelling, or even worse, when there is already deformity. Feel, therefore, in the joint lining for a soft tissue, almost spongy 'feel' to the joint. The same technique is followed to all joints.
3. **MOVE** the joint. This is to establish tenderness and range of movement. It must be realised that joint pain

might result either from within the joint – capsular, versus soft tissue involvement i.e. muscles or tendons - outside the joint. The differentiation between joint versus soft tissue disease is not complicated. It is based on the simple principle that muscle or tendon disease will not be painful on passive movement, but rather on contracting the involved tendon. This can be done by testing movement against resistance. However joint disease itself can be diagnosed by testing for tenderness on passive movement of the joint. Restriction of joint range of movement, in the so-called capsular pattern, for that particular joint is an indication of previous age indeterminate disease.

By doing this to all the joints, a picture of involved joints and soft tissues can be formulated and by assessing the type

of joint involvement and the distribution of disease, a diagnosis can be made, **AT AN EARLY STAGE**, and therapy instituted.

In the case of rheumatoid arthritis, the articular disease starts early on, as an inflammatory disease characterised by:

- Pain.
- Morning stiffness.
- Inflammatory symptoms are more typically felt in the morning.
- Midday fatigue
- Heat and swelling in the joints.

It is typically a **BILATERAL SYMMETRICAL POLY-ARTHRITIS**, affecting nearly any joint, especially hands, wrists, feet, cervical spine and large joints. The lumbar spine is not involved. Further investigations may be done, but it is important to realise they are **NOT** necessary for diagnosis, and in fact may be **NORMAL**. In fact, we want to see **NORMAL X-RAYS**, with **NO** erosions.

### Clinical guide

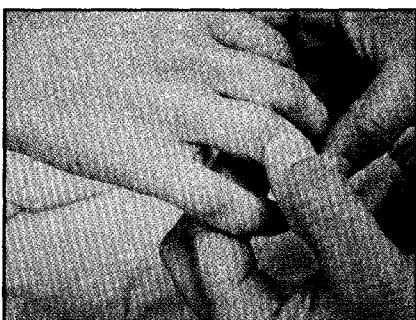

Figure 1: Examination of the joints. Each joint is carefully inspected and palpated for swelling. Here the examiner feels the proximal interphalangeal joints.

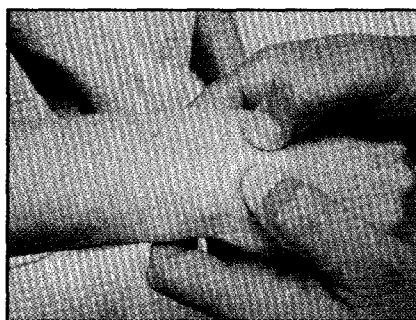


Figure 2: Examination of the joints. The wrists are examined by palpating the joint lining and checking for restriction in range of movement.

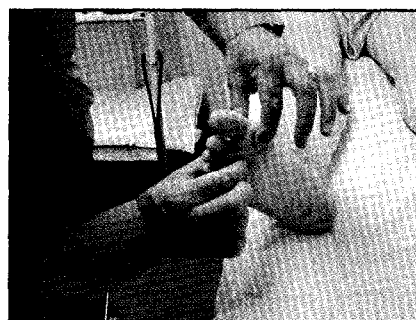

Figure 3: Examination of the joints: The joints in the feet, in particular the metatarsophalangeal joints are palpated for tenderness and swelling.

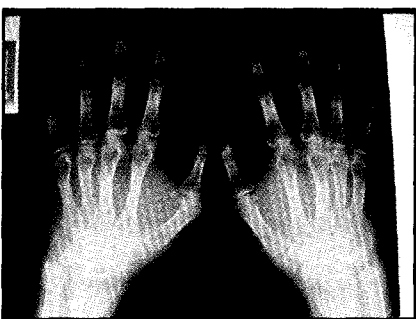


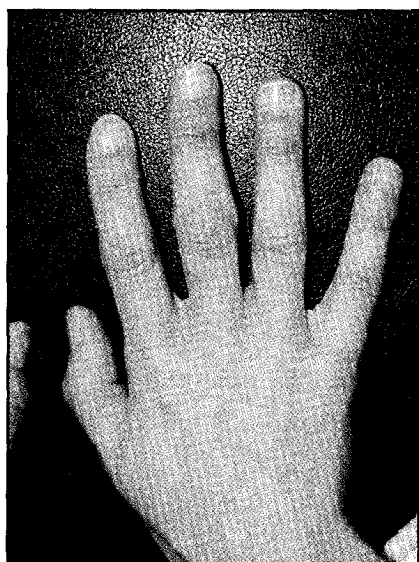
Figure 4: X-rays of the hands in Rheumatoid arthritis. Demonstrates periarticular porosis, joint space narrowing of the proximal interphalangeal joints, and erosions. Note erosion of the ulnar styloid, and narrowing of the wrists. (See Fig 5)

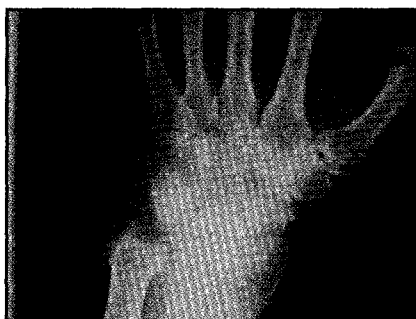

Figure 5: X-rays of the wrist demonstrating joint space narrowing and erosion of the ulnar styloid. Note also mid-carpal erosions.

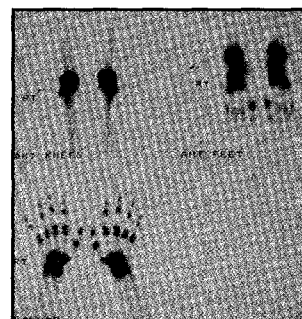

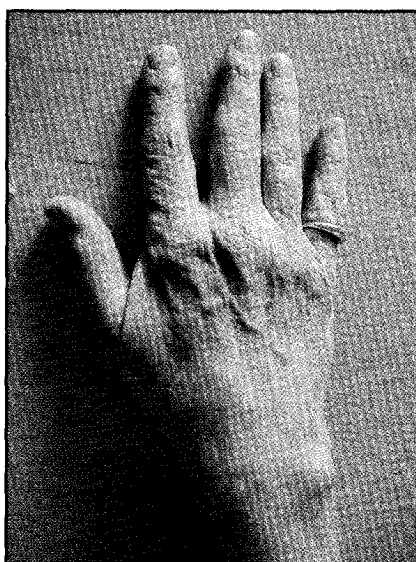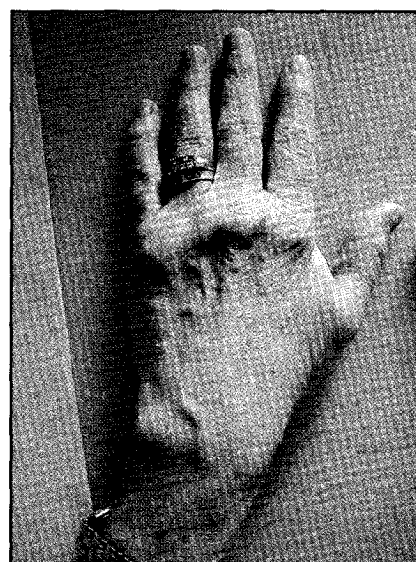
Figure 6: Technetium-99 bone scan in a patient complaining of stiffness and painful joints but a **NORMAL** examination, showing uptake of technetium in sub clinical inflammation of joints. Note symmetrical, polyarticular uptake pattern (hands, feet and knees demonstrated) – typical of Rheumatoid arthritis.



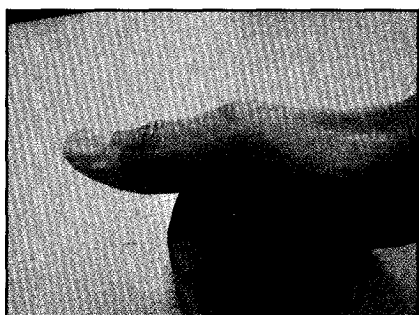**Figure 7:** Early swelling of Rheumatoid arthritis. Note the fleshy swelling of the tissue around the proximal interphalangeal joints of the hand.



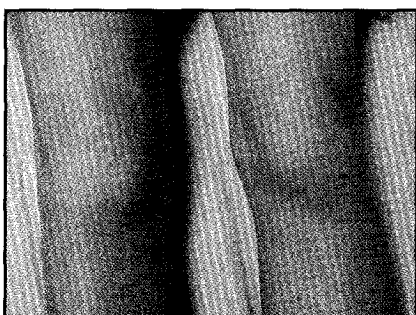
**Figure 8:** Mild early swelling of the metacarpal joints and the wrist in Rheumatoid arthritis.



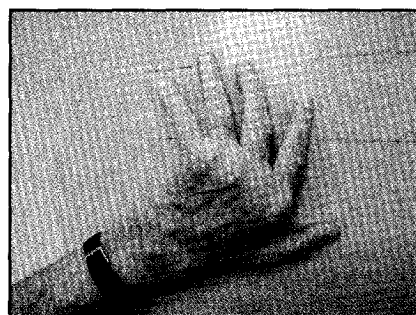**Figure 9:** Moderate early swelling of the metacarpal joints and the wrist in Rheumatoid Arthritis.



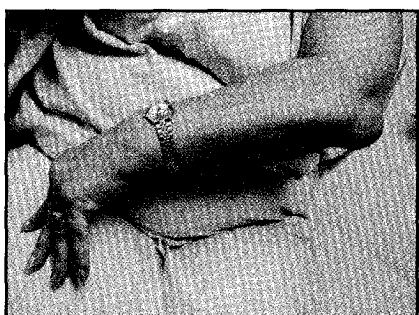
**Figure 10:** Soft tissue swelling of the carpometacarpal, metacarpal and interphalangeal joint of the thumb in early Rheumatoid arthritis.



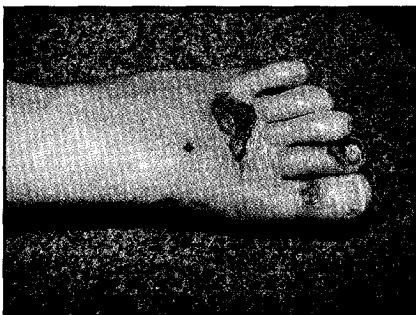
**Figure 11:** Swelling of the knees in Rheumatoid arthritis.



**Figure 12:** Late Rheumatoid arthritis, with deformity. Note the subluxation of the metacarpophalangeal joints and ulnar deviation of the fingers. The subluxation gives a false impression of swelling. In fact individual examination in this case reveals NO soft tissue swelling on palpation. The ends of the metacarpal bones are palpated and felt as bony prominence.



**Figure 13:** Extra-articular involvement. Rheumatoid nodule, at the extensor aspect of the elbow. Note also the deformity in the hands with ulnar deviation.



**Figure 14:** Extra-articular involvement. Rheumatoid vasculitis with skin ulceration on the dorsum of the foot.

Visit [www.arthritis.co.za](http://www.arthritis.co.za) today!

**BLOOD TESTS AND THE LABORATORY**

This assists not only in diagnosis, but also in quantifying active disease.

The blood tests are an adjunct to the clinical assessment. They do not replace it.

The Tests must ALWAYS be interpreted in the clinical context, and NOT in isolation.

*Useful investigations:*

- FBC - full blood count.
- ESR - sedimentation rate - this is useful as a screen for inflammation in the body, but is non specific and not infallible.
- CRP - C-Reactive protein. This is increasingly being used as a marker of inflammation, and activity of the disease. It is produced in the liver as a response to inflammation.
- RHEUMATOID FACTOR. The rheumatoid factors are ANTI-BODIES TO a part (Fc PORTION) of HUMAN Immunoglobulin (IgG). They are detected by AGGLUTINATION TESTS. Of note is that 1-5% of NORMAL people in the population are positive (NB this increases with AGE ) Only 75-85 % of RA patients are positive. Therefore they are not absolutely necessary for the diagnosis. However a high Rheumatoid factor is a marker of more severe disease. False positive Rheumatoid factor can also occur. (Table 1).

*Radiology*

One generally asks for X-Rays of the hands and feet. Changes include soft tissue thickening, osteopenia, joint space narrowing and erosive changes. Erosions in general, commence within the first 2 years. If clinically indicated, ask for a Chest X-ray and if there are cervical spine symptoms - ask for a cervical XRAY - including flexion and

Table 1: Rheumatoid factor
1. True positive: In Rheumatoid Arthritis.
2. False positive: In several Rheumatic and autoimmune diseases <ul style="list-style-type: none"> <li>• Sjogren</li> <li>• SLE/Scleroderma</li> <li>• Polymyositis</li> <li>• Coeliac disease</li> <li>• Chronic Active hepatitis</li> <li>• Interstitial pulmonary fibrosis</li> <li>• Waldenstrom's macroglobulinaemia.</li> </ul>
3. False positive: General medical disorders - including: <ul style="list-style-type: none"> <li>• Endocarditis</li> <li>• TB</li> <li>• Syphilis</li> <li>• Leprosy</li> <li>• Schistosomiasis - Bilharzia</li> </ul>

extension views.

Technetium bone scanning is also potentially useful to detect sub-clinical disease. Early erosive or bone changes can also be visualised using MRI of joints.

Ultrasound of joints to detect early synovitis is also increasingly used.

*Extra-articular involvement*

It is vital to understand that RA is NOT just a joint disease and that many organs can be involved. Therefore a full organ/systemic detailed examination is essential.

The disease is not necessarily benign and the practitioner needs to be able to assess articular as well as extraarticular disease.

Classification criteria are defined, (Table 2), but this does NOT mean that therapy should be delayed until all criteria are present, as they can develop over time. A strong suspicion for the diagnosis is sufficient for commencement of therapy.

In the context of the full patient evaluation, safe and effective therapy

Table 2: Classification criteria (American College of Rheumatology.)
One requires 4 out of the 7 criteria for diagnosis.
1. Morning stiffness greater than 1 hour.
2. Soft tissue swelling in a hand joint.
3. Soft tissue swelling in 3 out of 14 joint groups - PIP'S, MCP'S, wrists, elbows, knees, ankles, MTP's
4. Symmetrical swelling in one joint area.
5. Rheumatoid nodule.
6. Rheumatoid factors.
7. Radiographic changes in the wrist or hands. (Porosis/erosion).
<i>The American Rheumatism Association 1987 revised criteria for the classification of rheumatoid arthritis. Arthritis Rheum 1988 Mar; 31(3):315-24. Arnett FC, Edworthy SM, Bloch DA, McShane DJ, Fries JF, Cooper NS, Healey LA, Kaplan SR, Liang MH, Luthra HS, et al.</i>

can be instituted to the short and long term benefit of the patient. This minimises deformity, preserves function and improves both morbidity and mortality. It is the early diagnosis and access to appropriate therapy that determines the outcome of the patient. There is considerable evidence that early exposure to disease modifying therapy improves outcome. Antiinflammatories do NOTHING to treat the disease process itself and therefore treat only the symptoms with no influence on outcome.

In the next issue the diagnosis of Osteoarthritis will be discussed. It is imperative that the GP has a clear understanding of the differences between the treatment of RA and OA and this will be discussed in a third article. □

Please refer to the CPD questionnaire on page 53.