

Diagnosis and management of common non-viral oral ulcerations

Van Heerden WFP, BChD, MChD (Oral Path), FC Path(SA) Oral Path, PhD, DSc
Department of Oral Pathology, University of Pretoria
Boy SC, BChD, MChD (Oral Path)
Department of Oral Pathology, University of Pretoria

Correspondence to: Prof Willie van Heerden, e-mail: vwheerd@medic.up.ac.za

Abstract

Oral ulcerations are common lesions encountered in private practice. Oral ulcers can have a localised aetiology or be a manifestation of a variety of systemic conditions or disorders. Appropriate management depends on the correct diagnosis which can at times be difficult due to similar clinical features. The aetiology, diagnosis and management of the most common non-viral ulcerative disorders of the oral mucosa are discussed. These include traumatic ulcers, recurrent aphthous stomatitis, malignancy as well as oral ulceration associated with cutaneous pathology.

SA Fam Pract 2007;49(8): 20-26

Introduction

Oral ulcerations are common lesions encountered in private practice. Oral ulcers can have a localised aetiology or be a manifestation of a variety of systemic conditions or disorders (see Table I). Appropriate management depends on the correct diagnosis, which at times can be difficult due to similar clinical features. Viral infections, many of which present as ulcerative lesions, have been discussed in a previous edition.¹ The aetiology, diagnosis and management of the most common non-viral ulcerative disorders of the oral mucosa are discussed. These include traumatic ulcers, recurrent aphthous stomatitis, malignancy, as well as oral ulceration associated with cutaneous pathology.

Table I: Classification of the more frequent oral ulcers based on aetiology and appearance

1. Solitary ulcers

- **Traumatic ulcerations**
- **Malignant neoplasms**
Squamous cell carcinoma
Extranodal non-Hodgkins lymphoma
Metastatic tumours
- **Infections**
Tuberculosis
Syphilis
Deep fungal infections

2. Recurrent ulcers that heal spontaneously

- Recurrent aphthous stomatitis
- Beçhet's syndrome
- Reiter's syndrome
- Erythema multiforme

2. Persistent ulcers without vesicle formation

- **Gastrointestinal disease**
Crohn's disease
Ulcerative colitis
- **Haematological disorders**
Leukaemia
Neutropaenia
- **Rheumatoid Diseases**
DLE
- **Cutaneous disease**
Ulcerative lichen planus
- **Drug reactions (may be preceded by vesicles)**

3. Ulcers with preceding vesicle formation

- **Cutaneous disease**
Mucous membrane pemphigoid
Pemphigus vulgaris
- **Viral disease**
Herpes simplex infections
Varicella zoster infections
Herpangina
Hand foot-and-mouth disease
Measles

cally-associated ulcers is aspirin burns, where acetylsalicylic acid-containing tablets or powders are placed directly on the mucosa next to a carious tooth, resulting in various degrees of epithelial necrosis. Thermal burns, as seen with hot food, especially cheese (pizzas) and tomatoes, are often seen on the palate and tongue. Local radiotherapy and certain chemotherapy regimens can cause oral mucositis, which presents as multiple areas of painful erythema, ulceration and even epithelial sloughing.²

Diagnosis

Traumatic ulcers, especially acute ulcers, present with various degrees of pain and other signs of acute inflammation. Chronic ulcers are usually painless. Patients are often aware of traumatic ulcers and can reflect the episode of trauma when questioned about it. These ulcers are usually solitary in nature.

Management

When the clinical suspicion of a traumatic aetiology exists for an oral ulcer, the cause should be determined and, if applicable, be removed. The patient should be followed up for a maximum of two weeks and if no clinical sign of improvement is present, a biopsy to exclude more serious possible aetiology is indicated. Sucking of ice at the time of receiving chemotherapy is effective as a prophylactic treatment, as it reduces the blood flow to the oral mucosa during the time of peak serum concentration. Antiseptic mouth washes (chlorhexidine)

Traumatic ulceration

Aetiology

Acute and chronic traumatic injury to the oral mucosa is common and frequently results in ulceration. Mechanical trauma is the most common cause. These may be caused by dentures, accidental trauma, when soft tissue gets trapped between the teeth, or physiological trauma, where the patient has a habit of cheek or lip biting (morsicatio buccalis or labialis). It may also be iatrogenically induced by rotary instruments, removal of dried cotton rolls from the mucosa or negative pressure from the saliva ejector. The most common cause of chemi-

or anti-inflammatory washes (benzydamine) are often used as a treatment for oral mucositis in cancer patients.³

Recurrent aphthous stomatitis (RAS)

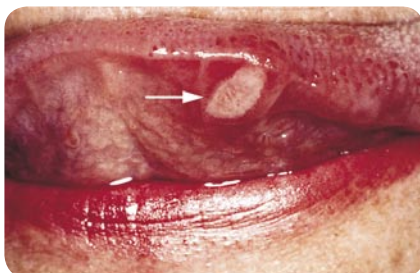
Aetiology

Recurrent aphthous stomatitis is one of the most common conditions leading to recurrent oral ulceration. The aetiology for RAS is basically unknown. Several aetiological factors, including genetic predisposition, local trauma, hormonal changes, infective agents, gastrointestinal disorders, stress, immunological abnormalities and haematological deficiencies (vitamin B₁₂, red cell folate, iron), have been proposed.⁴ The majority of patients, however, are healthy. Systemic conditions, including Beçhet's syndrome, and chronic malabsorption conditions, such as Crohn's disease, ulcerative colitis and celiac disease, may be associated with RAS.

Diagnosis

RAS affects between 15 to 25% of the healthy population. Males and females are equally affected, with a peak in early adult life. It is more common in professional and semi-professional people and is rarely seen in smokers. The ulcers can arise every four to 12 weeks and may be classified as minor, major and herpetiform, affecting approximately 80%, 10% and 5 to 10% of RAS patients respectively. The diagnosis of RAS is based on the history of recurrences of painful, self-healing ulcers at regular intervals on non-keratinised mucosa (labial, buccal, soft palate, ventral surface of the tongue, floor of mouth and oro-pharynx) (see Figure 1). A biopsy is rarely indicated. The most important differential diagnosis is with herpes simplex infection-associated ulceration (see Table II).⁵

Figure 1: Minor aphthous ulcer (arrow) on the ventral aspect of the tongue.



Management

About 20% of patients may have vitamin B₁₂, red cell folate or iron deficiency, and it is therefore best to exclude these potential causes. These conditions are

Table II: Clinical features of RAS and comparison with herpes simplex ulceration

	Minor aphthous	Major aphthous	Herpetiform aphthous	Primary herpes simplex ulceration	Recurrent herpes simplex ulceration
Age of onset	10–19 yrs	10–19 yrs	20–29 yrs	<10 yrs, childhood	adulthood
Site	Non-keratinised mucosa, especially labial/buccal mucosa, dorsum and lateral borders of tongue	Keratinised plus non-keratinised mucosa of particularly soft palate and lip	Non-keratinised mucosa, but particularly floor of mouth and ventral surface of tongue	Keratinised non-movable bound mucosa, hard palate and gingiva	Keratinised mucosa, most common on vermillion, occasional gingiva and hard palate
Size	3–5 mm	5–15 mm	1–2 mm	1–2 mm, preceded by vesicles	1–2 mm, preceded by vesicles
Number	1–5	1–10	>10, which may coalesce	>10, which may coalesce	often only a few
Duration	7–14 days	>30 days	10–30 days	5–7 days	5–7 days

Table III: Treatment options for RAS

No treatment	<p>Reassure the patient that:</p> <ul style="list-style-type: none"> It's a common condition, it's not malignant, it has no malignant potential and it's not contagious or infectious <p>Self-medication:</p> <ul style="list-style-type: none"> Covering agents like orabase Antiseptic mouthwashes (Corsodyl, Chlorhexidine) <p>Avoid sharp and spicy foods and acidic or carbonated drinks</p>
Mild ulceration (ulcer-free period of one month or more)	<p>Kenalog in orabase (triamcinolone)</p> <ul style="list-style-type: none"> Apply to dried ulcer with ear bud or moistened finger. Allow to become wet before contact with uninvolved mucosa. Four times daily, one application before going to bed. For use where ulcers are accessible
Moderately severe ulceration (2–4 week ulcer-free period)	<p>Betamethasone mouthwash (Celestone 0.5 mg tab in 5–10 ml warmish water)</p> <ul style="list-style-type: none"> Four times daily. Hold in mouth for 3 min and spit out <p>Prednisone mouthwash (Meticorten 5 mg in 15 ml warmish water)</p> <ul style="list-style-type: none"> Four times daily. Hold in mouth for 3 min and spit out. It may also be applied to a small piece of cotton wool and this held over the lesion for longer <p>0.05% Fluocinonide in orabase (50/50)</p> <ul style="list-style-type: none"> Applied 6x pd to early ulcers <p>Beclomethasone dipropionate aerosol (Beconase spray)</p> <p>2 puffs (100 microgram) onto affected area. Maximum of 8 puffs/day</p>
Severe ulceration (ulcer-free less than two weeks, all major RAS)	<p>Systemic corticosteroids</p> <ul style="list-style-type: none"> 30–60 mg daily for a week, followed by a one-week taper <p>Thalidomide (50–200 mg daily for four to eight weeks) has been used successfully in selected cases, but is rarely indicated due to severe side effects</p> <p>Referral is indicated</p>
Herpetiforme RAS	<p>Tetracycline 250 mg caps dissolved in 10 ml of warmish water as mouthwash</p> <ul style="list-style-type: none"> Hold in mouth for 3 min and then spit out. Three times daily. Not for children under 12. Evaluate patients for Candida overgrowth
Children with RAS	<p>Reassure parents</p> <p>Ensure correct diagnosis</p> <p>Ensure eating and hydration (parents)</p> <p>Local anaesthetic preparation on ulcer before eating</p> <p>More severe – Kenalog in orabase (children may need help with application)</p>

more likely to be present in older patients whose ulceration starts or worsens in middle age. Correcting the deficiency has been shown to bring rapid relief for these patients. Treatment is mostly symptomatic, aimed mainly at pain relief, reducing the frequency of ulceration and preventing secondary infection. The choice of therapy depends on the severity and frequency of ulceration (see Table III).

Malignant ulcers

Aetiology

A range of malignant neoplasms may present as an ulcerative lesion, of which oral squamous cell carcinoma is by far the most common. Oral cancer is a life-threatening disease in most countries, especially in developing countries. The severity of oral cancer in South Africa is demonstrated by the fact that it is one of the most common malignancies in South African males, a fact that is not often appreciated.⁶ One of the reasons may be that oral cancer is not registered as a single entity in the local cancer registry, but separated into cancers originating from the mouth, tongue or gums. Oral cancer is largely a preventable disease, as the primary aetiological agents are tobacco products, heavy use of alcohol, and especially the combination of these two.⁷ More than 90% of oral cancer patients give a history of tobacco use. All forms of tobacco use are implicated, including smokeless tobacco (chewing tobacco and snuff dipping).⁸

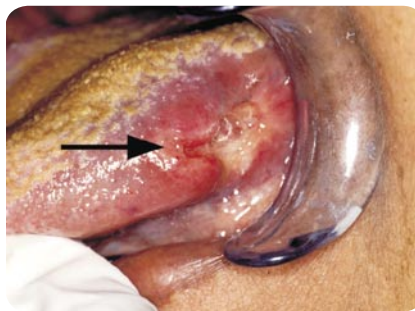Diagnosis

Early detection of oral cancer allows for a five-year survival rate of close to 90%. However, most oral cancers are diagnosed at an advanced stage, with a five-year survival rate of about 20%, which is one of the worst prognoses of all major cancers. This is a tragic situation because no specialised techniques are required to examine the oral cavity for the presence of precursor lesions or early oral cancers. Prevention and early diagnosis are therefore of the utmost importance.

Early cancerous lesions are usually painless and may appear as small, apparently harmless areas of induration, erosion or keratosis, often deceiving the unsuspecting clinician into a false sense of security. The advanced oral cancerous lesion usually consists of a persistent painless ulcer with indurated, rolled margins. In most cases the ulcer

has a characteristic appearance that may serve as a diagnostic aid (see Figure 2). It may be fixed to underlying soft tissues and bone, and regional lymphadenopathy may be present. Malignant ulcers are usually painless unless secondarily infected. In advanced cases, patients may present with trismus or impaired tongue movement. Cancers of the tongue may also present with ear pain due to involvement of n. *glossopharyngeus*.

Figure 2: Squamous cell carcinoma presenting as an indurated ulcer (arrow) on the lateral border of the tongue.



Management

Any suspicious-looking oral mucosal lesion, including any ulcer not healing within two weeks after conservative treatment, must be biopsied to establish the diagnosis. The biopsy should be sufficiently large to include enough abnormal and clinically normal tissue, enabling the pathologist to make a diagnosis without requesting additional material. After the diagnosis of oral cancer has been confirmed, the patient should be referred to a head and neck surgeon for further management and treatment, which may vary from a localised excision to extensive surgery with adjuvant chemo- and radiotherapy.

Cutaneous disease

Aetiology

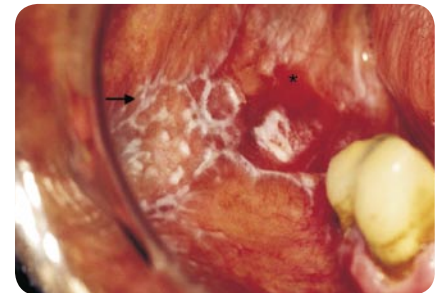
Ulcers may be a manifestation of several skin diseases, the most common being lichen planus, pemphigus vulgaris erythema multiforme and mucous membrane pemphigoid.

Diagnosis

Lichen planus (LP) is a chronic mucocutaneous disease in which skin and oral lesions are seen simultaneously in almost 40% of patients. Isolated skin (35%) and mucosal (25%) lesions may also be seen. LP presents with three distinct clinical patterns: reticular, erosive

and plaques.⁹ It is common for patients to have a mixture of these three patterns. Reticular LP is the most common form and consists of bilateral, raised, delicate thin white lines that produce a lace-like pattern set on an erythematous background. These lesions are commonly seen on the buccal mucosa and are usually asymptomatic. Erosive LP presents with atrophic and erosive areas on an erythematous background. Faint white striae can often be identified at the margin of the ulcers (see Figure 3). These lesions are painful and may be difficult to differentiate clinically from other erosive oral conditions, such as mucous membrane pemphigoid and pemphigus vulgaris. Plaque LP presents as white, flat to slightly raised areas, indistinguishable from leukoplakia. It is most commonly seen on the tongue. Patients may have other features of lichen planus in the mouth that may help to differentiate this lesion. It is usually asymptomatic. The clinical picture of LP is often characteristic, but the diagnosis should always be confirmed with an incisional biopsy.

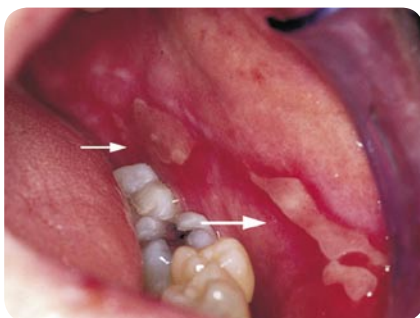Figure 3: Lichen planus presenting with white striae (arrow) on the buccal mucosa that are combined with erosive red areas of ulceration (asterisk).



Pemphigus vulgaris (PV) is an autoimmune disease characterised by an antigenic attack and destruction of the desmosomal attachment (intracellular cohesive system) of epithelial cells. This results in epithelial separation above the basal cell layer, causing bullae on the skin and mucosae.¹⁰ The oral lesions precede cutaneous involvement in 75% of affected patients. Although lesions may be confined to the oral cavity, the skin lesions usually develop in the subsequent months. Failure to recognise the early oral lesion leads to a substantial delay in the diagnosis of this serious and life-threatening systemic disorder. Large and painful oral ulcerations are

most commonly seen. Although these lesions start as bullae, they are soon lost due to trauma during normal mastication. All mucosal surfaces may be affected, but the soft palate is most commonly involved, followed in order of frequency by the buccal mucosa, tongue and gingiva (see Figure 4). The use of a blunt instrument will cause the epithelial tissue to form a bulla and to separate, in both the skin and oral mucosa. This is called the Nikolsky sign. Although this sign is seen in other desquamative conditions, it is more commonly seen in PV. The diagnosis should be confirmed with an incisional biopsy of an intact bulla, with inclusion of the adjacent normal mucosa in order to evaluate the transitional zone.

Figure 4: Ulcerations with surrounding erythema on the buccal mucosa (arrows) in a patient with pemphigus vulgaris.



Erythema multiforme (EM) is an inflammatory disease of immune origin affecting the skin and mucosa. It arises due to immune complexes binding to vessel walls, with a subsequent inflammatory process that leads to tissue loss. The specific aetiology in a given patient is often unknown, although herpes simplex virus and certain drugs may be involved. EM is characterised by the rapid onset of oral, cutaneous and ocular lesions. The skin lesions are discrete, asymptomatic, erythematous macules or sometimes vesicles that are distributed in a symmetrical manner on the hands, arms, legs, face and neck. These lesions are known as bull's-eye or target lesions, appearing as a concentric erythematous patch with a peripheral thin pale zone and a surrounding larger erythematous zone (Figure 5). The central small papule or bulla soon ruptures, but heals rapidly, often leaving the red zone behind for a longer period. Skin lesions are pathognomonic for EM. Oral lesions are seen in 30 to 60% of cases,

and may be confined to the oral cavity. The oral lesions are areas of painful erythema, bullae and ulcers, as well as areas of bleeding and crusting (Figure 6). The buccal mucosa, lips, soft palate and tongue are the most commonly involved sites. The clinical course of erythema multiforme is usually over a period of three to four weeks. Recurrences are common, usually at intervals of several months over a period of years. Progression to more severe forms of EM (Steven Johnson Syndrome and toxic epidermal necrolysis) sometimes occurs, with extensive systemic involvement.

Figure 5: Characteristic target lesions (arrows) of erythema multiforme on the dorsum of the hand.

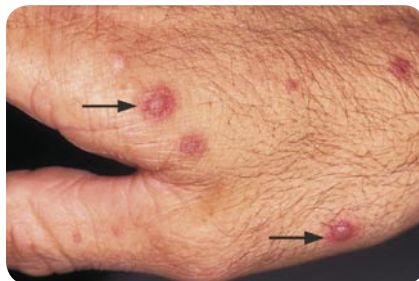
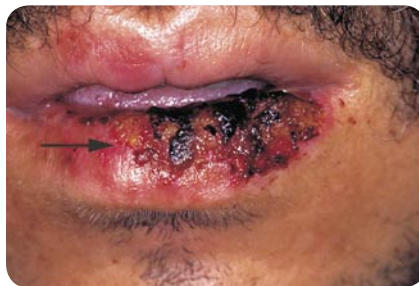
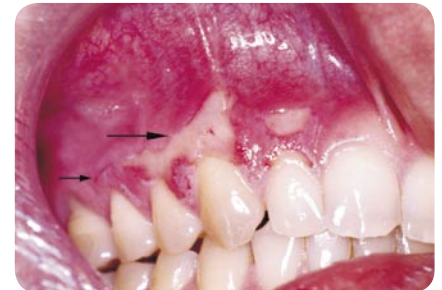Figure 6: Extensive ulceration and characteristic crust formation (arrow) on the lips of the same patient with erythema multiforme



Mucous membrane pemphigoid (MMP) is an autoimmune disease most commonly seen in middle-aged to older females. It is characterised by bullous eruptions and ulceration, particularly of the oral mucosa and conjunctiva.¹¹ Eighty percent of the affected patients have oral lesions in the form of shallow ulcerations and a characteristic form of gingivitis known as desquamative gingivitis (see Figure 7). Seventy percent may have conjunctival lesions, 25% have genital lesions, and 20% have skin lesions. Involvement of the eye conjunctiva is a major concern. Bullae, erosions and generalised swelling and erythema can lead to the formation of adhesive

tissue bands extending from the conjunctiva of the eye to the sclera, and this can result in entropion and blindness.

Figure 7: MMP presenting as desquamative gingivitis of the gingival, with resulting ulceration (arrows).



Management

As LP is a chronic disease with no cure, treatment is aimed at symptomatic control. If the patient is asymptomatic, no active treatment is required. For symptomatic atrophic or erosive lesions, treatment consists of topical steroids such as fluocinonide gel (0.05%) applied four to six times a day (mix with Orabase 1:1 to facilitate adhesion). Topical therapy affords only temporary control of the disease and patients should be advised that the lesions might recur. The development of iatrogenic candidiasis should be monitored and managed.

Patients with PV should be referred for specialist treatment. Prolonged high dosages of systemic corticosteroids that are tapered as soon as control is obtained are still the mainstay of treatment. Secondary infection of the ulcerated areas should be monitored and managed.

The aetiological factor in EM should be eliminated if applicable. Mild cases of EM require only symptomatic treatment, which may include analgesics and anti-inflammatories such as aspirin or non-steroidal anti-inflammatory drugs. However, care should be taken to check the history to ensure the EM was not precipitated by NSAIDs. Topical steroids can also be prescribed. Minimising mucosal damage by means of a bland liquid diet is essential. Maintaining optimal oral hygiene to prevent secondary infections with agents such as *Candida* is also important.

Treatment for MMP is similar to that of pemphigus vulgaris. Topical corticosteroids (fluocinonide gel 0.05%, mixed with Orabase) are indicated, especially for gingival lesions. Systemic corticosteroids are indicated in severe cases.


Oral hygiene may be difficult for the patient, given the desquamative gingivitis. Mouth washes containing agents such as chlorhexidine are beneficial. Ophthalmologic examination is important to evaluate and exclude the possibility of early ocular disease. Patients should also be made aware of this in order to facilitate long-term management.

Conclusion

All patients with recurrent or persistent oral ulceration should be fully investigated to establish a definitive diagnosis and to eliminate the possibility of an underlying systemic disorder or oral malignancy. Ulcers should always be examined for induration or fixation, which may be indicative of malignancy. Unless the cause is undoubtedly local, general physical examination is always indicated, looking especially for mucocutaneous lesions or other systemic conditions. All undiagnosed ulcers, as well as ulcers that are suspected as being malignant, should be biopsied. Although oral ulceration therefore may pose a clinical dilemma, thorough clinicopathological examination will usually result in a final diagnosis that can lead

to optimal management and treatment of such a patient. 

See CPD Questionnaire, page 42

 This article has been peer reviewed

References

1. Van Heerden WFP. Oral manifestations of viral infections. *SA Fam Prac* 2006;48:20–4.
2. Porter SR, Leao JC. Review article: oral ulcers and its relevance to systemic disorders. *Aliment Pharmacol Ther* 2005;21: 295–306.
3. Meade GM. Management of oral mucositis associated with cancer chemotherapy. *Lancet* 2002;359:815–6.
4. Scully C. Aphthous ulceration. *N Engl J Med* 2006;355:165–72.
5. Field EA, Allan RB. Review article: oral ulceration – aetiopathogenesis, clinical diagnosis and management in the gastrointestinal clinic. *Aliment Pharmacol Ther* 2003;18:949–62.
6. Van Heerden WFP, Butow K-W. The role of the dentist in the prevention and early diagnosis of oral cancer. *S Afr Dent J* 2002;57: 22–4.
7. Blot WJ, McLaughlin JK, Winn DM, et al. Smoking and drinking in relation to oral and pharyngeal cancer. *Cancer Res* 1988;48: 3282–7.
8. Hoffmann D, Djordjevic MV. Chemical composition and carcinogenicity of smokeless tobacco. *Adv Dent Res* 1997;11:322–9.
9. Sugarman PB, Savage NW, Walsh LJ, et al. The pathogenesis of oral lichen planus. *Crit Rev Oral Biol Med* 2002; 13: 350–365.
10. Black M, Mignogna MD, Scully C. Pemphigus vulgaris. *Oral Diseases* 2005;11: 119–30.
11. Chan LS, Ahmed AR, Anhalt GJ, et al. The first international consensus on mucous membrane pemphigoid. *Arch Dermatol* 2002;138:370–9.