

# Complications of inflammatory sinusitis in children: institutional review.

**Tshifularo M**, MBChB, M Med (ORL), FCS (SA)

Department of Otorhinolaryngology, University of Limpopo (MEDUNSA Campus)

**Monama GM**, MBChB

Department of Otorhinolaryngology, University of Limpopo (MEDUNSA Campus)

**Correspondence to:** Dr M Tshifularo, e-mail: tshifularom@surgeon.co.za

## Abstract

### Background

Complications of acute inflammatory sinusitis into orbital and intracranial sepsis is a common problem in paediatrics. A delay in making a diagnosis and early appropriate treatment has a high morbidity and mortality rate. The commonest presenting symptoms are throbbing headache and facial or periorbital swelling usually following a two week history of upper respiratory tract infection. A high resolution Computed Tomography (CT) scan is very helpful in making a proper and accurate diagnosis. Appropriate early medical and surgical treatment has a good outcome. We are reporting our epidemiological study of complicated sinusitis of 59 cases treated at Dr George Mukhari Hospital, ENT Department a Tertiary referral centre, Medunsa Campus, University of Limpopo, RSA.

### Methods

A prospective case series of all patients admitted with complicated inflammatory confirmed on CT scan between April 2004 to August 2005 (Winter months). An interview data collection sheet was used to collect all clinical information.

### Results

Fifty-nine (59) inpatients (50 males and 9 females) admitted and treated at DGMH for complicated pansinusitis. The mean age of the patients was 13 years, with a male:female ratio of 7:1. All patients presented with a sporadic first episode of sinusitis, occurring within two weeks of upper airway infection. The affected age group was mainly paediatric of peripubertal age. In almost all the patients, headache and facial (peri-orbital) swelling were the main presenting symptoms. Most patients (85%) were initially referred to other departments 59.3% (35) to Ophthalmology, 18.6% (11) to Neurosurgery, 6.7% (4) to Paediatrics and only 15.2% (9) directly to ENT (Otorhinolaryngology). Of these patients, 36 (61%) had intracranial complications confirmed on CT scan and were managed in consultation with the neurosurgeons and ophthalmologists. No major surgical complications were reported. Staphylococcus species were the most common organisms isolated; however, 50% of the pus swabs had a negative culture. Medical treatment based on culture and sensitivity, together with surgical drainage, achieved good results. Three females with severe complications died during the period of the study, but there were no male deaths reported in this study, even though more males than females were affected.

### Conclusion

Complications of septic sinusitis are a common problem in the paediatrics, with males more commonly affected than females. Females, however, had a poorer prognosis than males in this study. Complicated sinusitis should be suspected in any adolescent with orbital, facial or frontal swelling associated with headache always during the winter (cold) months. To prevent morbidity and mortality, a high resolution contrasted CT scan is mandatory for the exclusion of complicated sinusitis, medical and surgical treatments are effective management of complicated sinusitis.

**SA Fam Pract 2006;48(10):16**

**INTRODUCTION**

Sinusitis is a relatively common problem, although sinusitis associated with a complication is less frequent. A small but significant number of people still develop intracranial complications, which affect between 0.5% and 24% of patients admitted to hospital with acute bacterial sinusitis.<sup>1</sup> Despite recent advances in medical and surgical therapy for sinusitis, suppurative intra-cranial complications remain a contemporary problem. Complicated sinusitis can result in significant morbidity if not appropriately managed.<sup>2</sup>

The close proximity of the orbit to the paranasal sinuses often results in orbital complications. The lamina papyracea is a paper-thin bony dividing wall between the nose and orbit. This bony wall is perforated by small vessels, which permit the spread of aggressive infections into the orbit. The superior and inferior ophthalmic veins are valveless, allowing for the much easier spread of infection. Fortunately, the peri-orbital periosteum serves as a strong barrier for the orbital contents, giving way only to the most aggressive infection.<sup>3</sup> Although complications of sinusitis can be serious in most cases, the anatomy does provide time for medical treatment prior to the development of the most serious complications.

Several classifications of complicated sinusitis spreading to the orbit are available.<sup>4</sup> The most commonly seen early complications are orbital, especially in children, and are staged according to Chandler's classification (I-V). These patients present with upper and lower eyelid oedema, eye pain, sepsis, chemosis, proptosis, complete extraocular muscular paralysis and visual loss, which may deteriorate. Daily evaluation by ophthalmologists is therefore necessary. Early complicated sinusitis with lid oedema can be managed medically with broad-spectrum antibiotics and close follow-up. A very important decision is when to select surgery as part of the treatment plan. Strict clinical monitoring and CT scanning are important to determine the progression of the disease.

Intra-cranial complications include meningitis, epidural abscess, subdural empyema, cavernous sinus thrombosis, brain abscesses and infarction. Fortunately, aggressive treatment with antibiotics has greatly reduced these complications. The adolescent age group is particularly susceptible to intracranial complications, because both frontal sinus expansion and the vascularity of the diploic system are peaking.<sup>5</sup>

The clinical picture depends on the history and physical findings and

is related to the location of the initial infection. Acute or progressive headache is the most important indicator of complications. Other symptoms can be a swollen face, proptosis, nausea, vomiting, convulsions, coma or alteration of mental status, focal neurological signs and signs of meningitis.

The introduction of scanning has made early diagnosis possible, but mortality rates remain significant at 5 to 27%, increasing with age. Up to 40% of patients will have permanent serious disability, such as convulsions (7.5%) or hemi-paresis (2 to 17%).<sup>6,7</sup> These mortality and morbidity rates have not altered since the popularisation of FESS (Functional Endoscopic Sinus Surgery) in 1981. FESS has been advocated not only as the least invasive approach, but also as the most effective, because not only can diseased ethmoid air cells be removed, but medial subperiosteal orbital collections can also be drained. This study is an epidemiological survey of complicated sinusitis patients treated in our hospital with the purpose of reviewing our treatment protocol.

**PATIENTS AND METHODS**

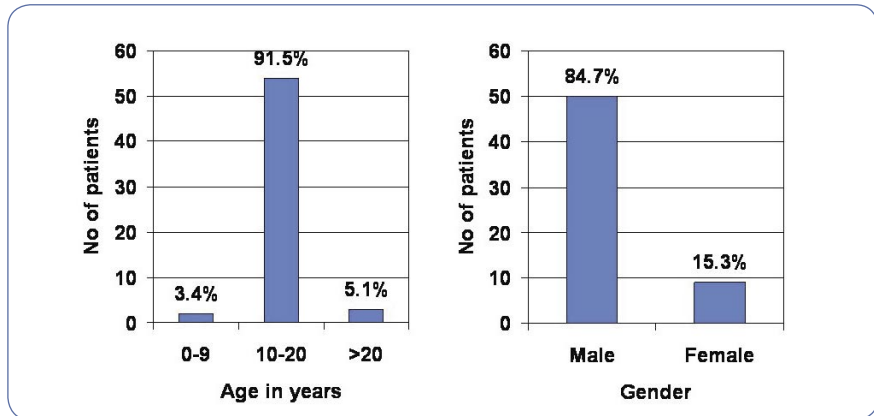
We conducted a prospective study in the winter, from April 2003 to August 2005. All the patients who were admitted to DGM Hospital with a diagnosis of complicated septic sinusitis that had been confirmed on CT scan were included. These patients were invited to join the study after all the ethical issues had been discussed with them and informed consent had been given. A structured interview questionnaire was completed with each patient. Relevant investigations were done on all these patients (CT scan, blood FBC, U/E; LFT, and pus swabs from surgical site in theatre for microscopy, culture and sensitivity). All patients were put on antibiotics before they were taken to theatre for surgical drainage.

**RESULTS**

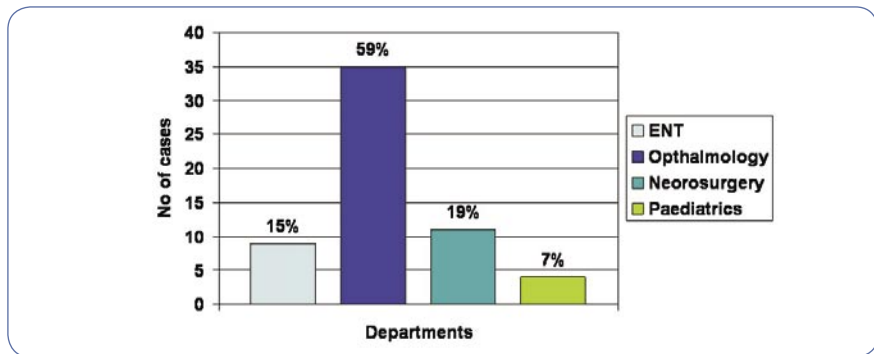
There were a total number of 59 subjects (50 males and 9 females), with a male to female ratio of 7 to 1. The age distribution ranged from 10 to 20 years old (see Figure 1).

Two patients were 10 years old (3.4%), 54 patients were between 10 and 20 years old (91.5%), and three patients were approximately 20 years old (5.1%). These patients presented to the primary physicians, who then referred them to the specialist departments according to their differential diagnosis. They were referred to four main departments (see Figure 2).

**Fig. 1:** Age and gender distribution



**Fig. 2:** Distribution of referrals to different departments



Most patients were referred to the department of ophthalmology because of orbital complications before a diagnosis of complicated sinusitis was made. Headache was the common presenting symptom in most of these patients, together with facial swelling (see Figure 3), proptosis, convulsion, fever, nasal blockage, rhinorrhea, facial neurological signs and mental status changes or coma. Most of the patients were misdiagnosed by primary physicians, thus leading to a delay in treatment.

These complications occurred mainly during the winter months, from April to August. CT scan of the sinuses to confirm the diagnosis was a mandatory investigation (see Figure 4). The main complications were intra-cranial (36; 61%), orbital (13; 22%) and both intra-cranial and orbital (10; 17%) (see Figure 5).

The referring physicians treated all these patients with intravenous antibiotics, including piperacillin, vancomycin, cefuroxime, cloxacillin, gentamycin, ampicillin, chloramphenicol and metronidazole. The availability of antibiotics in the referring hospital was the main determinant of antibiotic selection. All the patients had undergone surgical drainage of the purulent sinuses and the site of complications (brain, orbit). A swab was taken from aspirated purulent discharges and sinus washout aspirate for microscopy, culture and sensitivity. Approximately 50% of cultures were negative, probably as a result of these patients having received antibiotics before surgery (see Table 1).

Fig. 3:

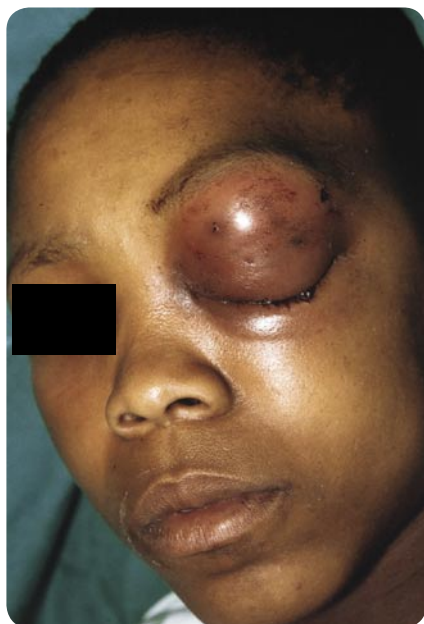

Fig. 4:

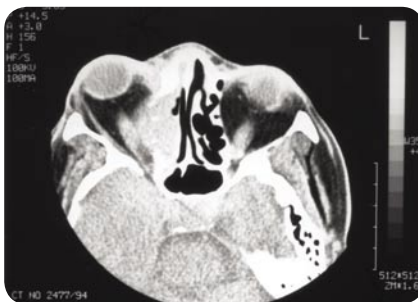

Fig. 5: Distribution of complications between orbital, Intracranial and both

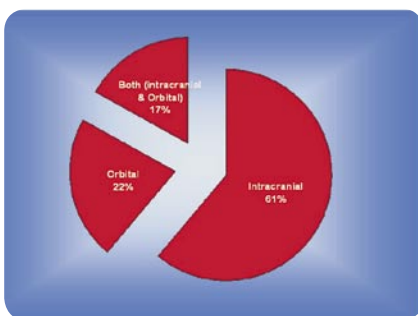


Table 1: Micro-organisms isolated

Micro-organisms		Tshifularo n=25	Bouwer <i>et al.</i>	Zinnat <i>et al.</i> N=339	A.C. Swiet <i>et al.</i> N=27	G. David <i>et al.</i> N=35
Staph	Epidermis Aureus	20% (5) 16% (4)	- 0-8%	- 3%	- 13%	- -
	Pneumonia Viridans	0% (0) 16% (4)	20-35% -	41% -	10% -	23% -
Haemophilus Influenza		12% (3)	5-25%	35%	26%	23%
Moraxella Catarrhalis		0% (0)	2-20%	40%	-	11%
Anaerobes		12% (3)	-	-	-	-
Others	Proteus Morabilis	8% (2)	-	3%	-	-
	E. Coli	4% (1)	-	-	-	-
	Klebsiella Pneumonia	12% (3)	-	-	-	-

This table shows cultured micro-organisms from patients with acute complicated sinusitis reported by different investigators.

The mean inpatient stay was 21 days (range 14-45 days). Three of the 59 patients died (5.1%). All three patients were females who were very ill on admission from the referring hospitals. Complications in these patients were brain abscesses, cerebritis, meningitis, encephalitis and focal neurological fallouts. Patients who had intra-cranial complications and neurological defects stayed in hospital for longer, and all the neurological defects improved.

DISCUSSION

This report emphasises the importance of early diagnosis and a high index of suspicion of complicated sinusitis in any young patient with facial swelling, which is a common condition in our community. This study comprised 59 patients in the age group of 10 to 20 years (paediatric). More males (50; 85%) were affected than females (9; 15%), in a ratio of 7:1 (male: female). This is similar to the ratio reported by other authors.<sup>7</sup> Intra-cranial complications included meningitis (4; 6.8%), extradural abscess (22; 37%), cerebritis (2; 3%), and encephalitis and hydrocephalus (4; 6.8%). The remaining 13 patients (22%) had orbital complications, including inflammatory oedema, orbital cellulitis, subperiosteal abscess, orbital abscess and cavernous sinus thrombosis, while 14 (24.4%) had both intra-cranial and orbital complications. One patient had bilateral blindness.

The referral pattern by primary physicians was to four departments, with patients diagnosed as ENT (9; 15.2%),

paediatric (4; 6.8%), neurosurgery (11; 18.6%) and ophthalmology (35; 59.3%). Most patients were referred to ophthalmology with differential diagnoses of ecchymosis, panophthalmitis, retrobulbar tumour, cavernous sinus thrombosis and orbital cellulitis, as the orbital complications were obvious on clinical examination.

None of the patients appeared to have had allergies or chronic rhinosinusitis before; this was a sporadic and

unpredictable event, in keeping with other authors' experiences.<sup>8</sup> The preponderance of adolescent (paediatric) males in the peripubertal age group being affected is in line with other studies. It is suggested that adolescents and young adults are affected most because this is the age at which the valveless diploic system is at its most vascular and paranasal sinus growth is at a maximum, thus providing good conductive pathways for bacterial infection. The posterior wall of the maturing frontal sinuses is a poor barrier to the spread of organisms that cause sinus infection. Retrograde septic thrombophlebitis is the most likely route of infection and it is less common for this to be spread by means of direct extension through a bony defect.<sup>9</sup>

Complications are more common in males and it is unclear if the hormonal effect has an influence. Many of the patients were otherwise healthy and developed their rhinosinusitis after an upper respiratory tract infection. The most common presenting symptoms, which lasted an average of two weeks, were headache, present in almost all patients, together with fever, facial swelling, orbital swelling, echymosis and focal neurological deficit and/or coma. A retrospective review of these patients' notes suggests that they were misdiagnosed and mismanaged by their primary physicians. They were initially treated for cellulitis with inappropriate antibiotics.

Many factors besides anatomical ones determine whether an individual will develop complications. These factors include the virulence of the infecting organism or organisms, and bacterial resistance, which results in commonly used antibiotics becoming increasingly more ineffective, particularly in relation to streptococcus pneumonia, staphylococcus (betalactam resistance), haemophilus and moraxella.<sup>10</sup> It therefore is likely that the organisms causing intracranial complications are highly virulent or resistant to the antibiotics used. It has also been suggested that facultative and obligate anaerobes may work synergistically to cause the persistence of infection. The studies of the organisms found in these cases may have been affected by the fact that the patients presented after hours as emergency cases and that they had been on antibiotics before cultures were taken. Other factors are poor microaerobic and anaerobic culture techniques. The 50% negative culture (no growth) in the specimens in this study was probably due to many factors, such as antibiotic use, collection time and technique. Resistance to penicillin was encountered, although the infection responded

to cefuroxime or cefotaxime and metronidazole. Anaerobes may be part of the mixed flora and have been proposed as the primary causative agent in brain abscesses. Staphylococcus aureus can be particularly aggressive and is the most common organism in extradural abscesses and should not be dismissed as a contaminant when considering antibiotic regimens. Other micro-organisms were also isolated. Given the sporadic nature of the complications and their unpredictability, it is very important to have a high index of suspicion when symptoms like vomiting, convulsions, echymosis, orbital swelling and facial swelling present in an adolescent male patient in cold winter months. All of these symptoms warrant an urgent CT scan with contrast to exclude complicated sinusitis.

In this study, there was no report of silent intracranial complications, as reported by other authors.<sup>11</sup> More than 50% of the cases presented with orbital and frontal swelling, which is in keeping with the findings of other studies.<sup>12</sup> Surgical drainage of the sinuses is likely to help if they are in continuity with the extradural and orbital complications. The pus swab for microscopy and sensitivity needs to be done at the first sitting of the procedure. The advantages of FESS over external surgical approaches for extracranial complications in acute sinusitis include high success rates, low morbidity and no facial distortion or scars.<sup>13</sup> Endoscopic surgery could be more difficult due to the infective environment and more bleeding is present during this procedure. It should also only be performed by a competent, trained surgeon. There currently is debate as to whether acute complicated sinusitis should be managed by frontal sinus trephine and sinus washout or by immediate frontoethmoidectomy/functional endoscopic sinus surgery.<sup>13</sup>

In this study, the morbidity associated with intracranial complications in the medium term was 33%. There was a mortality rate of 5.1%, as three of the female patients died. The first was a 10-year-old girl who was very ill and in a coma on presentation; she had hemiencephalitis, extradural empyema, lobar pneumonia and cavernous sinus thrombosis. The second patient was an 11-year-old girl who presented with pansinusitis, encephalitis, extradural emphyema, hemiparesis and convulsions. The third patient was a 14-year-old girl who presented with convulsions, headache and brain abscesses. None of these patients had signs suggestive of being immunocompromised, although they were not tested for HIV. There were no deaths among the male

patients, despite the male preponderance in this study group. Complications in the females turned out to be more severe (reason not known).

## CONCLUSION

Complicated septic sinusitis in the paediatric age group is still a common and serious problem in our community, particularly in the winter. It is often misdiagnosed, or the diagnosis is delayed, leading to incorrect and delayed appropriate treatment. The intra-cranial complications of sinusitis remain an important entity for the primary physician to identify and manage. Complications are more common in males than females (7:1) in the pre-pubertal age group. Headache and facial swelling were common presenting symptoms of complicated sinusitis. In most of the cases there was no history of recurrent rhinosinusitis. Staphylococcus species were the most common organisms isolated, although 50% of the patients had a negative culture.

Medical treatment based on culture and sensitivity and surgical drainage as a multidisciplinary approach achieved good results. Frontal trephine with the management of associated complications is an acceptable management option for patients with acute complicated pansinusitis. Frontoethmoidectomy or FESS can be held in reserve for those patients with persistent disease that does not resolve after the initial treatment. However, cavernous sinus thrombosis and multiple brain abscesses still had a very high mortality rate. Finally, to exclude complicated sinusitis, a high index of suspicion and early diagnosis with high-resolution CT scan with contrast are mandatory in a paediatric patient with orbital or facial swelling in the winter months.

## References

1. Liorente Fendas JL, Del Campo A, Perez Vazquez P, et al. Complicated sinusitis and nasal endoscopic surgery. *Acta Otorinolaringol Esp*. 2003;54(8):551-6.
2. Jones NS, Walker JL, Bassi S, Jones T, Punt J. The intracranial complications of rhinosinusitis: can they be prevented? *Laryngoscope* 2002;112:59-63.
3. Giannoni CM, Stewart MG, Alford EL. Intracranial complications of sinusitis. *Laryngoscope* 1997;107:863-7.
4. Clayman GL, Adams GL, Paugh DR, Koopmann CF. Intracranial complications of paranasal sinusitis: a combined institutional review. *Laryngoscope* 1991;101:234-9.
5. Maniglia AJ, Goodwin J, Arnold JE, Ganz E. Intracranial abscess secondary to nasal, sinus and orbital infection in adults and children. *Arch Otolaryngol Head Neck Surg*. 1989;115:1424-9.
6. Stankiewicz JA, Park AA, Newell DJ. Complication of sinusitis. *Current Opinion in Otolaryngology & Head and Neck Surgery* 1996;4:17-20.
7. Stankiewicz JA, Newell DJ, Park AA. Complications of inflammatory diseases of the sinus. *Otolaryngol Clin North Am*. 1993;26:639-55.
8. Schramm VL, Cartin HO, Kennerdell JS. Evaluation of orbital cellulitis and results of treatment. *Laryngoscope* 1982;92:732-8.
9. Lemke BN, Gommering RS, Weinstein JN. Orbital cellulitis with periosteal elevation. *Ophthal Plast Reconstr Surg*. 1987;3:1-7.
10. Lerner DN, Choi SS, Zalzal GH, Johnson DL. Intracranial complications of sinusitis in childhood. *Ann Otol Rhinol Laryngol*. 1995;104:288-93.
11. Tinkelman DG, Silk HJ. Clinical and bacteriologic features of chronic sinusitis in children. *AJDC*. 1989;143:938-41.
12. Deutsch E, Hevron I. Endoscopic sinus surgery for extracranial complications of sinusitis. *Harefuah* 2000; 138(3): 195-9.
13. Mortimore S, Wormald PJ. Management of acute complicated sinusitis: a 5-year review. *Otolaryngol Head Neck Surg*. 1999;121(5):639-42.