

# Primary eye care for the general practitioner

Thunström V, FCOOphth(SA)

Department of Ophthalmology, Nelson R Mandela School of Medicine, University of KwaZulu-Natal

Correspondence to: Dr V Thunström, e-mail: skinner1@saol.com

## Abstract

This article outlines the clinical features and management of the basic eye conditions that every general practitioner should be able to diagnose and treat. These include ocular and adnexal conditions such as sty, conjunctivitis, blepharitis and preseptal cellulitis. The more severe conditions, such as dacryocystitis, corneal ulcer and orbital cellulites, also are presented, along with the criteria for specialist referral.

*SA Fam Pract 2006;48(7): 27-32*

### Introduction

Primary eye care forms an important part of every day general practice. This article reviews common conditions and will hopefully improve primary eye care significantly.

### Corneal foreign body

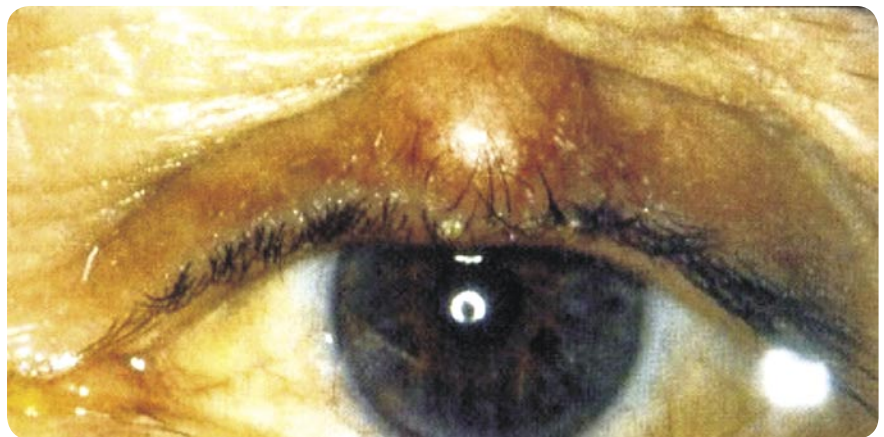This typically occurs in the occupational setting and is most commonly related to grinding, especially with a lack of protective eyewear. This topic is dealt with in the section dealing with trauma.

### Stye (external hordeolum)

This is a bacterial micro-abscess of the eyelash follicle and it may be recurrent in patients with blepharitis. The patient presents with pain, swelling and tenderness of the involved area of the eyelid. A small collection of pus may develop and later drain spontaneously through the skin. It should not be confused with a meibomian cyst, which occurs in the tarsal plate (see Figure 1). It is not an abscess, but represents an accumulation of sebaceous material due to blockage of a meibomian gland duct. Incision and curettage by an ophthalmologist is usually required.

The management of a sty is ancillary, as the condition usually runs a self-limiting course. Hot compresses and topical antibiotic ointment, such

Figure 1: Meibomian cyst



as Fucithalamic, may hasten resolution, and oral antibiotics, such as flucloxacillin, may be required if a significant regional cellulitis develops. Incision and drainage is reserved for the minority of cases where a significant abscess develops.

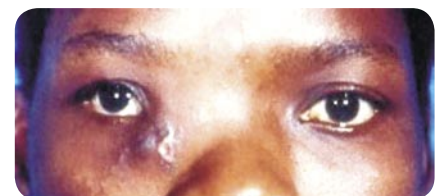### Dacryocystitis

This is an infection of the lacrimal sac secondary to blockage of the nasolacrimal drainage system, which drains tears from the lacrimal sac into the nose. Congenital cases are secondary to a membranous blockage of the nasolacrimal duct and present with tearing from birth. It is important to exclude other causes of tearing in a baby. Ninety per cent of cases resolve by the age of one year and do not require any special

treatment during this time. If tearing is still present at one year, the patient should be referred for a syringe and probe of the lacrimal apparatus.

Acquired dacryocystitis is due to an acquired blockage of the nasolacrimal duct. Patients present with chronic epiphora (tearing), and stasis of the tears allows secondary bacterial infection of the lacrimal sac. This manifests in pain and swelling below the medial canthal ligament (see Figure 2). Gentle pressure may

Figure 2: Dacryocystitis



cause the reflux of purulent material from the lacrimal punctum. If the infection breaks through the lacrimal sac, preseptal cellulitis and abscess formation develop. Posterior spread through the orbital septum gives rise to orbital cellulitis with globe displacement and limited extra-ocular movement.

Management in the acute phase consists of oral antibiotics with good staphylococcal cover. If there is frank orbital cellulitis or abscess formation, the patient should be referred for CT scanning and further management. If epiphora persists beyond the acute infection, the patient should be referred to an ophthalmologist for probing of the lacrimal system to locate the site of blockage so that surgical management may be planned.

## Conjunctivitis

### Allergic conjunctivitis

*Acute allergic conjunctivitis* is a hypersensitivity reaction to airborne allergens, e.g. dust and pollen. It presents acutely with ocular burning, itching, conjunctival hyperaemia, chemosis and a watery to mucoid discharge. Home management involves bathing the eyes with cold water. Medical management involves the use of the rapid onset histamine-1 antagonists levocabastine or emadastine for the rapid resolution of symptoms. Combination mast cell stabilisers/H1 antagonists may be used for acute/chronic conditions. These have a longer onset and duration of action (e.g. olopatidine/ketotifen). Vasoconstrictors (naphazoline/antazoline) treat hyperaemia only and the treatment mentioned previously is preferred, as it treats the underlying pathogenic mechanism. There is also the risk of rebound hyperaemia with the use of the vasoconstrictor type of drugs upon cessation of use.

*Contact dermatconjunctivitis* is caused by eye drops, cosmetics, clothing, jewellery or industrial chemicals. It presents with severe itching and a mucopurulent discharge. There is an eczematous rash involving the skin of the lower eyelid and chronic exposure to the allergen may lead

to keratinisation of the conjunctival surface of the eyelid. Management involves ophthalmic diagnosis and management and recurrences being followed up by the general practitioner.<sup>1</sup>

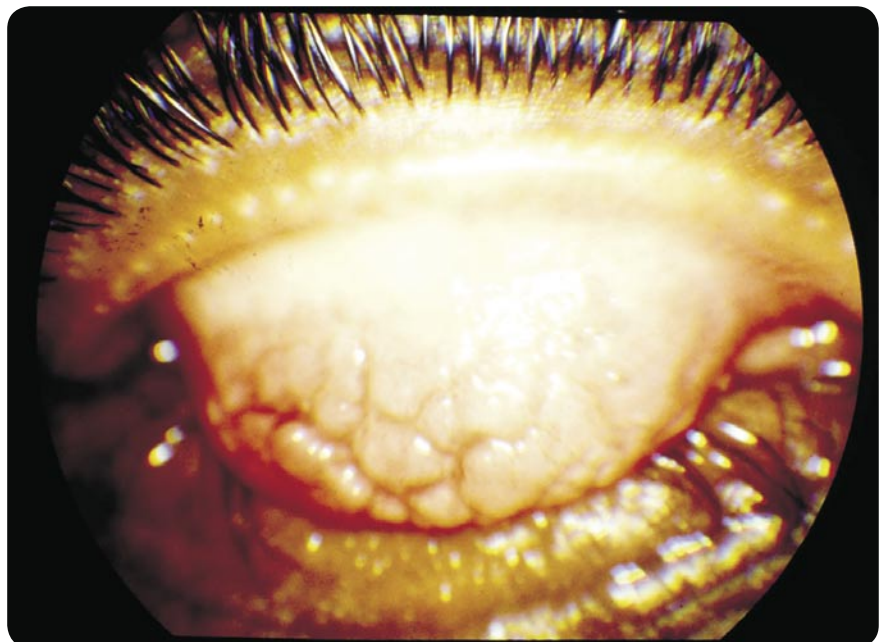
*Seasonal/perennial allergic conjunctivitis* represents the most common of the allergic ocular manifestations. A patient with the perennial form is asymptomatic throughout the year, but is prone to seasonal flare-ups. The seasonal form is less common and only symptomatic, for example in spring and summer due to grass/pollen allergens. Treatment is as for acute allergic conjunctivitis.<sup>2</sup>

*Vernal conjunctivitis* is similar to perennial allergic conjunctivitis, but may cause corneal blindness if not treated adequately. Its symptomatology is chronic, with seasonal exacerbations. It is most common in children aged 11 to 13 years, although adult onset is now increasingly being seen in patients with HIV infection. Patients have a significant history of atopy such as eczema or asthma. They complain of photophobia, tearing, burning sensation and a thick ropy discharge, especially in the mornings. If the upper eyelid is everted, it is possible to see enlarged papillae, which take on a cobblestone appearance and

may cause mechanical damage to the cornea with ulceration (see Figure 3). Enlarged lymphoid tissue around the limbus may become hypertrophic and visible as raised discrete inflamed spots next to the limbus – Trantas dots. Dry eye may result from the loss of goblet cells in the conjunctiva, as well as corneal opacification with vessel ingrowth. It is therefore essential that the condition be adequately treated – an ophthalmic diagnosis should be made and, if mild, followed up by the general practitioner. If symptoms are not controlled, they should be managed primarily by an ophthalmologist, as long-term medication may be required.

*Giant papillary conjunctivitis* is a specific form of allergic conjunctivitis affecting contact lens wearers in particular. It may only develop after a few years of uneventful lens wear. Patients complain of ocular itching, especially after the removal of the lenses, and they may experience an increase in mucous discharge. They may also be more aware of the lens causing a foreign body sensation. These patients need to be seen by their optometrist and/or ophthalmologist, who will recommend a change in their contact lens fitting or may recommend a change in cleaning regime or lens material. Medical treatment in the form of mast

**Figure 3:** Tarsal cobblestoning





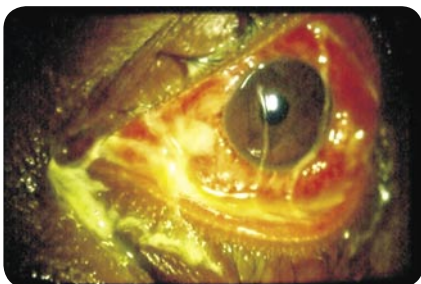
cell stabilisers and/or topical steroids is used in the short term.

#### *Infective conjunctivitis*

*Viral conjunctivitis* is the most common of the infectious aetiologies. It usually has an acute unilateral onset, although the fellow eye may become involved within a week or so. The eye typically has a watery discharge, conjunctival injection and mild lid swelling, with a swollen ipsilateral pre-auricular lymph node. It occurs most commonly following a viral upper respiratory tract infection and is often caused by an adenovirus. It usually runs a self-limiting course, but may benefit from topical antibiotics to prevent a secondary infection. Severe cases with a course longer than a week should be referred, as these cases may have developed corneal involvement.

*Bacterial conjunctivitis* is a relatively uncommon disease entity that presents with an acute onset of a purulent ocular discharge, lid swelling and conjunctival injection, with possible chemosis. The organisms implicated most commonly are *Staphylococcus* species, *Streptococcus pneumoniae* and *Haemophilus influenzae*. These patients may require conjunctival swabs that should be sent for MC&S and should be watched closely for corneal involvement. Treatment is with a broad-spectrum antibiotic, such as chloramphenicol, or with one of the quinolones. Particular mention should be made of gonococcal conjunctivitis, which presents with a hyperacute onset of severe unilateral or bilateral conjunctivitis (see Figure 4). There is a copious frothy discharge with lid swelling and chemosis and the patient may admit to having urogenital symptoms of dysuria or genital

**Figure 4: Gonococcal conjunctivitis**



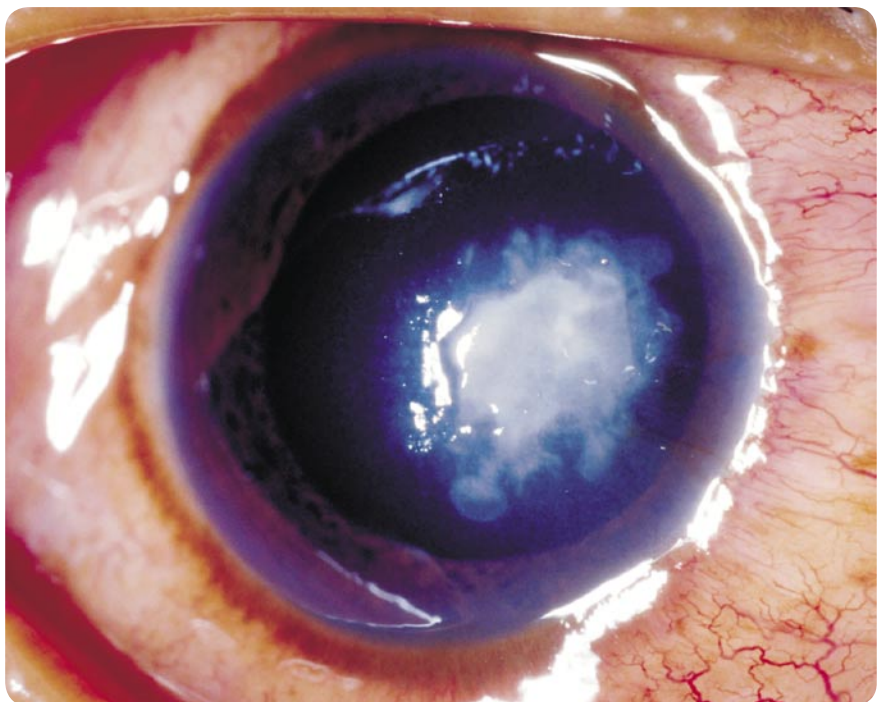
discharge, or may admit to instilling urine into the eyes. These patients represent an ophthalmic emergency and should be referred to an ophthalmologist without delay, as corneal involvement occurs rapidly and may lead to blindness if speedy treatment is not instituted.

#### **Corneal ulcer**

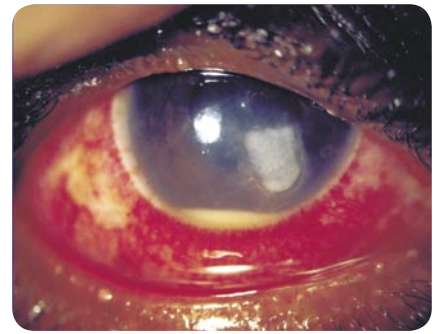This is potentially a visually devastating condition if neglected and should be treated by a specialist. The range of possible aetiologies includes bacteria, virus, fungus and protozoa. The most common cause in the developed world is related to contact lens wear. In the developing world it is microtrauma. Ulceration involves disruption of the corneal epithelium with infection of the underlying stroma. The course varies according to the aetiology. The patient presents with pain, discharge and decreased visual acuity. Indolent bacteria and fungi may present with a slower onset.

*Bacterial keratitis* is the most common form of the infectious aetiologies. A history of microtrauma or contact lens wear is common. There is an epithelial defect that stains with fluorescein and a surrounding grey-white area of infiltration and oedema. If more

**Figure 6: Fungal ulcer**



**Figure 5: Bacterial hypopyon ulcer**



advanced, there may be a white fluid level in the inferior anterior chamber – pus – and this is termed a hypopyon (see Figure 5). The management involves exclusion of a foreign body and referral to an ophthalmologist, who will frequently undertake a scrape of the lesion to identify the causative organism and to determine its sensitivity to antibiotics. Treatment is with intensive topical antibiotics. Topical steroids should not be given to patients in whom a corneal ulcer is suspected, as this will exacerbate the condition

*Fungal keratitis* is more common in tropical and subtropical climes and occurs most frequently with corneal microtrauma, most commonly with vegetable matter. Patients with impaired immunity, for example

HIV-positive and diabetic patients, are particularly prone. These ulcers frequently have an indolent onset, followed by a persistent foreign body sensation in the affected eye. The eye is frequently very painful, with all the usual features of ocular inflammation. Fungal ulcers typically have feathery borders and often have smaller satellite lesions (see Figure 6). They are difficult to culture and to treat, and require intensive topical therapy with appropriate antifungal agents, following corneal scraping.

*Viral keratitis* is most commonly caused by HSV-1. The primary infection in children commonly occurs as a blepharoconjunctivitis, although the vast majority of individuals will demonstrate subclinical infection. Nearly 100% of individuals over the age of 60 years will be sero-positive. A vesicular rash develops on the upper and lower eyelids, with associated viral conjunctivitis. Thirty to sixty per cent of patients will go on to develop a keratitis within one to two weeks of developing the rash. The keratitis may follow a variety of morphologies, varying in severity from a punctate epithelial infection to the classic dendritic ulcer, which is typified by a linear branching pattern of staining with terminal buds. Recurrent keratitis may develop in about one-third of patients, initiated by a variety of factors, including stress, illness, UV exposure and epithelial microtrauma, including surgery. Any of the corneal

layers may be involved and specialist opinion should be sought, as a variety of treatment options may be considered, depending on the exact nature of the infection. These treatments vary from topical antiviral agents to topical steroids, which may be of benefit in certain cases.

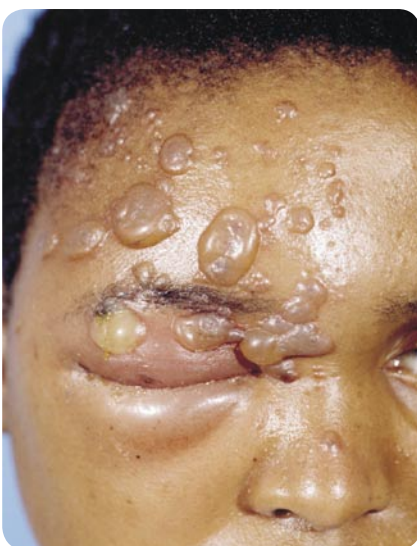Herpes zoster ophthalmicus (HZO) deserves special mention as there recently has been an upsurge in its incidence, particularly associated with HIV infection. Patients in the early phase of HIV infection may present with Herpes Zoster Ophthalmicus, indeed it may be the first manifestation of the disease. The onset of the rash is typically preceded by paraesthesia of the affected dermatome, which is the first division of the ophthalmic nerve. A vesicular rash involves the forehead and upper eyelid, with possible involvement of the eyelid margin (see Figure 7). Involvement of the tip of the nose – Hutchinson's sign – confers an increased risk of ocular involvement in those individuals. Conjunctivitis is common early on and presents with a red eye and a mucoid-watery discharge. Serious ocular complications may occur 10 to 21 days after the onset of the rash and include keratitis, anterior uveitis with glaucoma, scleritis, optic neuritis and multiple cranial nerve palsies. Late sequelae include an anaesthetic cornea with a predisposition to corneal ulceration; misdirected eyelashes or lid margin scarring with corneal abrasion; neuralgia

of that dermatome; and chronic conjunctivitis. Management should involve oral antiviral cover, such as acyclovir, as soon as the patient presents. If the patient presents late, the benefits are somewhat reduced. Topical antibiotic ointment may be used when the rash is in the vesicular phase and, once that has passed, topical steroid/antibiotic cream may be applied to limit scarring and the severity of postherpetic neuralgia. All patients should be seen by an ophthalmologist about a week to 10 days after the onset of the rash, and any patient who presents with ocular problems following zoster infection requires referral.

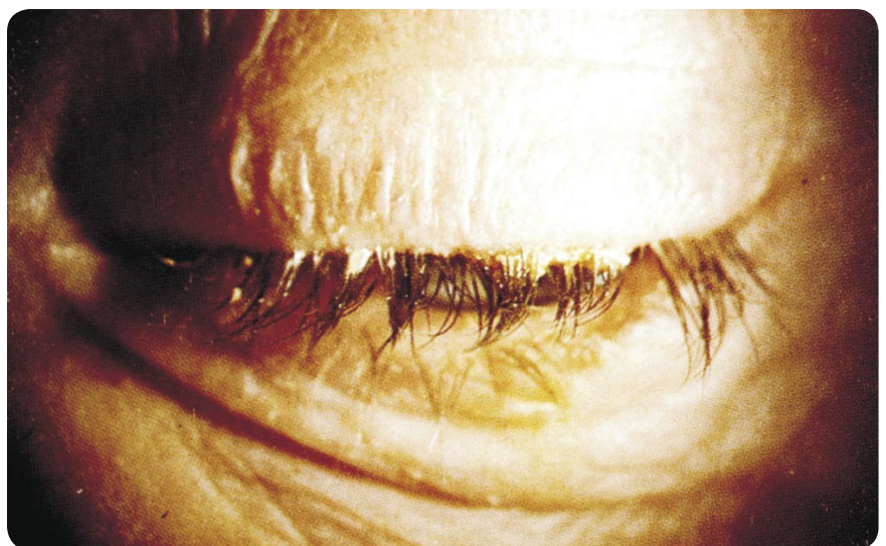### Blepharitis

This is a fairly common and frequently troublesome disorder of the eyelids, which loosely can be divided into anterior and posterior depending on the primary focus of the abnormality, although the presentation is frequently mixed. Anterior disease is frequently associated with staphylococcal infection of the eyelash bases and seborrhoea. Excess lipids are produced and, on the eyelids, *Corynebacterium acnes* breaks these down into fatty acids, creating ocular inflammation. *Posterior* disease is associated with meibomian gland dysfunction characterised by abnormally thick secretions. The symptoms include a burning sensation, foreign body symptoms and mild photophobia, frequently worse

**Figure 7:** Vesicular stage of HZO



**Figure 8:** Anterior blepharitis





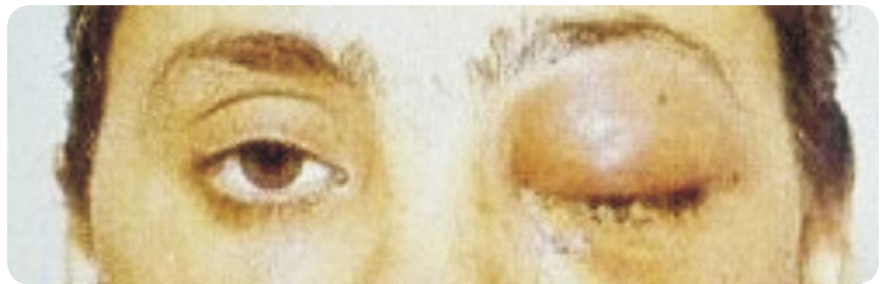in the morning. The disease follows a chronic course, with periods of exacerbation and remission.

When the eyelids are examined, anterior blepharitis exhibits scales centred on the base of the hair follicle, with hyperaemic lid margins and telangiectatic vessels. The eyelashes are greasy and frequently adhere to each other (see Figure 8). Frequent sequelae include stye, tear film instability with symptoms of dry eye, and hypersensitivity to staphylococcal exotoxins, which may cause a conjunctivitis or keratitis. Posterior disease presents with oil globules at the meibomian gland orifices and a foamy discharge may be noticeable at the lateral canthus. There is inflammation or obstruction of the meibomian glands, frequently associated with cyst formation. In these cases, management includes identification of the disease entity and awareness of its fluctuating natural history. Lid scrubs with a commercially available solution, or with diluted baby shampoo (1:4), form the basis of treatment. Anterior blepharitis may require a topical anti-staphylococcal agent to treat the infection. Tear replacement may be required if dry eye symptoms are prominent. For posterior blepharitis, systemic tetracycline may be prescribed for a period of six to 12 weeks, although not in children. Hot compresses may also aid in liquefying the meibomian secretions, followed by gentle pressure on the eyelid margin to allow the lipid to be expressed. It is important for the patient to adopt a regime of cleaning and applying drops to manage the symptoms.<sup>3</sup>

**Preseptal cellulitis**

This is a bacterial infection of the superficial tissues of the eyelid. It typically starts with a small pimple or some form of minor trauma to the periocular region and the causative organism is usually of the

**Figure 9: Orbital cellulitis**



staphylococcal or streptococcal species. When examining these patients it is of paramount importance that the globe is inspected behind the eyelids, as this is the only way to exclude orbital cellulitis. Even if it means causing the patient some degree of pain, the globe should be examined for any evidence of proptosis, chemosis of the conjunctiva, or limitation of the range of extra-ocular movement of the eye, as the presence of any of these represents postseptal infection. Management is with oral antibiotics with good staphylococcal and streptococcal cover. Admission is reserved for those patients with severe disease who require intravenous therapy. Abscess formation may complicate the picture and require incision and drainage.

**Orbital cellulitis**

This is characterised by postseptal infection with proptosis, chemosis and limitation of the movement of the eye (see Figure 9). It is far more serious and is most commonly associated with sinusitis. A CT scan of the brain, orbits and sinuses is required to exclude orbital or intracranial collections and to look for sinusitis, as neurosurgical or ENT advice may be required. These patients all need to be referred for emergency admission, intravenous antibiotics and possible surgery, depending on the aetiology. It also is necessary to document the Glasgow Coma Scale, look for meningism and exclude focal

neurological signs in these patients. In children, rhabdomyosarcoma may present similarly, thus the possibility of a tumour should be borne in mind.

**Indications for referral**

Any neurological signs
Orbital collection
Suspicion of tumour
Sinusitis

See CPD Questionnaire, page 50

**P** This article has been peer reviewed

**References**

1. Yanoff M, Duker J. Ophthalmology. 2nd ed. Mosby; . p. 405.
2. Kanski JJ. Clinical ophthalmology. 4th ed. Butterworth Heinemann; . p. 145.
3. American Academy of Ophthalmology. Section 8; 1998-1999. p. 155-7.