

# Office skills for the general practitioner

**Adamjee MF**, MBBCh, DA, DCH, FC Ophth(SA)

Dept of Ophthalmology, Nelson R Mandela School of Medicine, University of KwaZulu-Natal

**Correspondence to:** Mohamed Adamjee, e-mail: dradamjee@yahoo.com

## Abstract

Eye disorders are relatively common. Often the initial presentation is to a general practitioner. With a few basic tools for eye examination, a general practitioner would be able to conduct an adequate ophthalmic examination and appropriately refer cases requiring specialist care.

Assessment of visual acuity using a snellen chart and a pinhole can exclude refractive errors. A penlight is an inexpensive yet indispensable tool in the assessment of pupillary response, external structures as well as the anterior segment of the eye.

Superficial ocular foreign bodies are relatively common. With a good technique for eyelid eversion, these foreign bodies can be easily removed. Using fluorescein stain and cobalt blue light one can appreciate corneal epithelial defects.

Glaucoma is a sight threatening condition that can be effectively screened for, by using a schiotz tonometer and appropriate referrals made if the intraocular pressure is  $> 21$  mmHg or if the optic disc is cupped.

Direct ophthalmoscopy may be difficult but with a systematic approach and a few simple guidelines one would be able to adequately evaluate the posterior segment.

*SA Fam Pract 2006;48(7): 20-26*

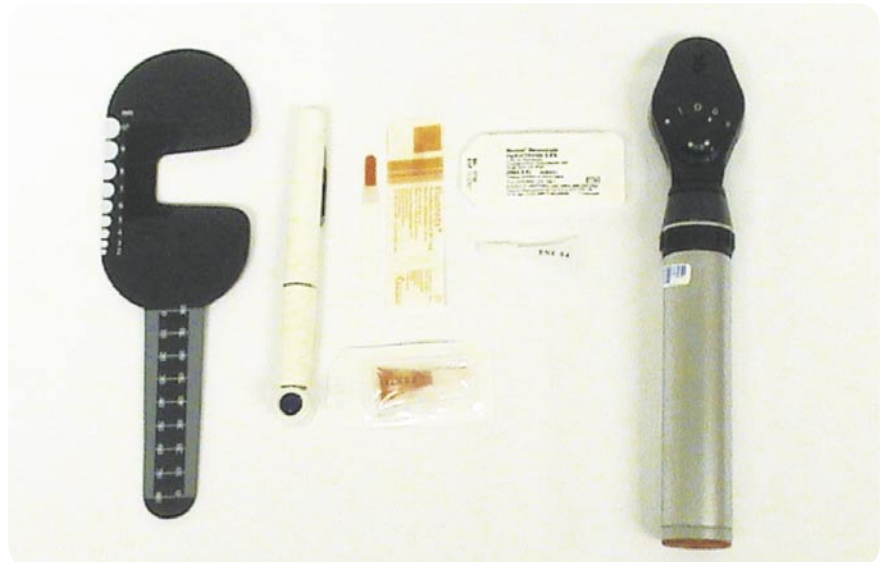## Introduction

Eye disorders are relatively common. In most cases, the patient would present to a general practitioner for the initial eye assessment. A thorough ophthalmologic evaluation is therefore vital in order to uncover common abnormalities of the visual system and related structures, as well as less common but extremely serious ones, such as ocular tumours. Often, an adequate evaluation can also uncover evidence of many forms of systemic disease with ophthalmic manifestations.<sup>1</sup> A comprehensive medical eye evaluation includes history, examination, diagnosis, and initiation of management. The tools that are essential for an adequate eye examination are listed below and pictured in Figures 1, 2 and 3.<sup>2</sup>

## Visual acuity

The first part of the eye examination is an assessment of visual acuity. This can be done with either a standard Snellen chart or a 'Tumbling (illiterate) E' chart. With the patient standing a distance of six metres away, each eye is tested independently. First, the vision is tested without the prescription glasses or contact lenses and thereafter with them.<sup>3</sup> The numbers at the end of the line provide an indication

**Figure 1:** Essential GP tools for eye examination



of the patient's acuity compared to that of normal subjects. Finally, a pinhole testing device can be used to determine whether a problem with acuity is the result of refractive error (and thus correctable with glasses) or due to another aetiology.

In clinical practice, the patient is instructed to view the Snellen chart through a single pinhole. Theoretically, each pinhole allows a narrow beam of

### SIX ESSENTIAL GP TOOLS FOR EYE EXAMINATION

- Snellen or E chart appropriately illuminated
- Pinhole device
- Penlight
- Fluorescein stain
- Topical anaesthetic agent
- Ophthalmoscope (with reliable batteries)

Figure 2: Snellen and E charts


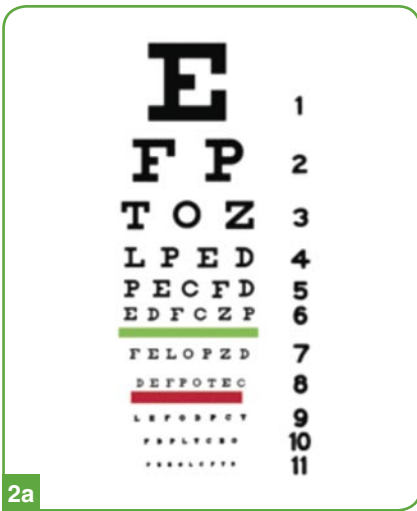


Figure 3: Pinhole



light to pass through, thus forming a clear retinal image irrespective of the refractive state of the eye.<sup>4</sup> If the deficit corrects with the pinhole in place, the decreased acuity is due to a refractive problem.

If the patient is unable to read any of the lines, a gross estimate of what they are capable of seeing should be determined (e.g. the ability to count the number of fingers placed in front of them, detect motion or perceive light).


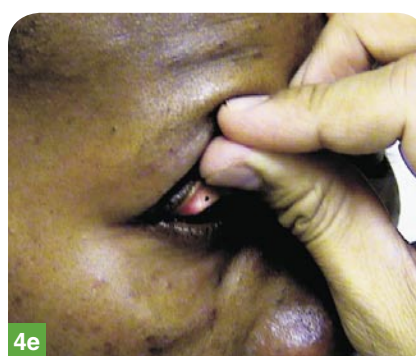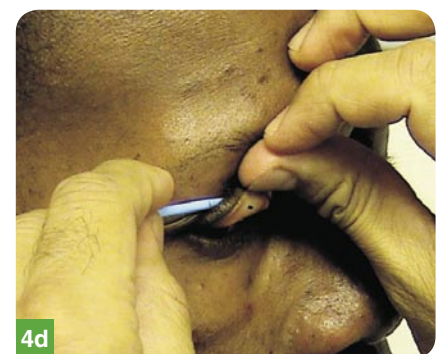
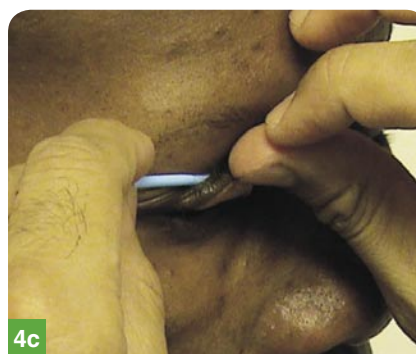
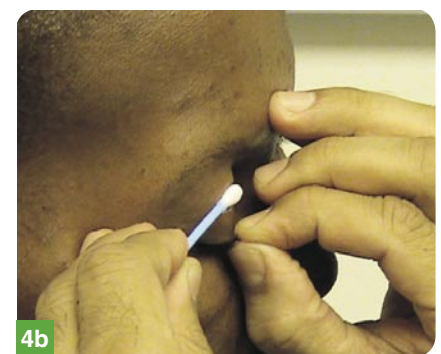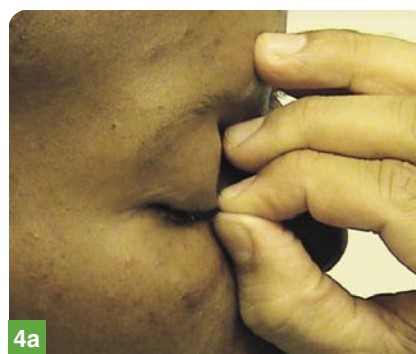
**External examination of the eye**

The external examination of the eye using a penlight should include an assessment of the lids, lashes, lacrimal apparatus, ocular surface and pupils. Some common causes of external eye abnormalities are easily seen with a penlight, for example proptosis (or exophthalmos) and ptosis, localised swelling in the eyelids (chalazion and sty), diffuse swelling (dacryocystitis and allergies), ectropion, entropion, trichiasis and eyelid lacerations.<sup>3</sup>

If the patient's symptoms are suggestive of a superficial foreign body, eyelid eversion is mandatory. With the correct technique, the procedure is relatively easy. Often, the foreign body is lodged in the palpebral conjunctiva of the upper lid and can be easily removed, as set out below and illustrated in Figure 4:<sup>3</sup>

- Instil a drop of local anaesthetic in the eye
- Grasp the eyelashes of the upper lid and pull down and away from the eye (a)
- Place an ear-bud in the upper lid fold, 1 cm above the lid margin (b)

Figure 4: Removal of foreign body



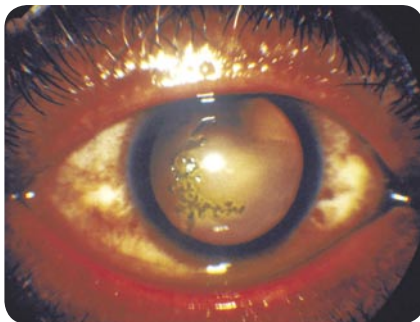
- Evert the upper lid over the ear-bud (c, d)
- Remove the ear-bud, while maintaining the lid in the everted position (e)
- Remove the foreign body using a rolling motion of the ear-bud (f)

**Examination of the cornea**

The cornea should be assessed thoroughly for foreign bodies, opacities and ulcers.

Suspected *corneal epithelial defects* should be stained with sterile fluorescein strips. A drop of topical anaesthetic (e.g. one drop of proparacaine 0.5% or tetracaine 0.5%), followed by a wet fluorescein strip, is applied to the inferior fornix. Using a cobalt-blue light, one can appreciate the corneal epithelial defect, which will appear green<sup>5</sup>. A penlight covered with a blue filter can also be used. (See Figure 5)

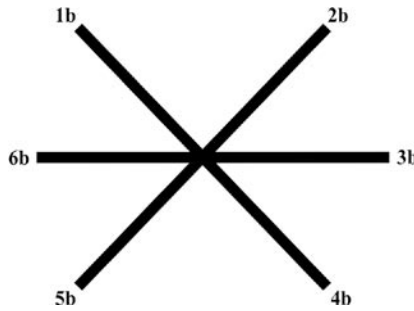
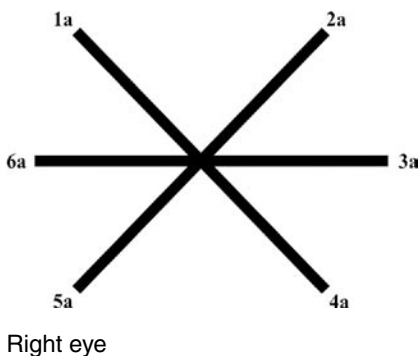
**Figure 5:** Dendritic corneal ulcer



**Ocular motility**

As part of the eye examination and neurological assessment, it is important to assess ocular motility. The patient is instructed to follow an object or penlight with his/her eyes in the six cardinal positions of gaze (labelled 1-6 in the Figure 6).

**Figure 6:** Testing of ocular motility



*Ductions* of the eye are eye movements tested with one eye being occluded while the fellow eye is tested. They consist of adduction, abduction, elevation, depression, intorsion and extorsion.

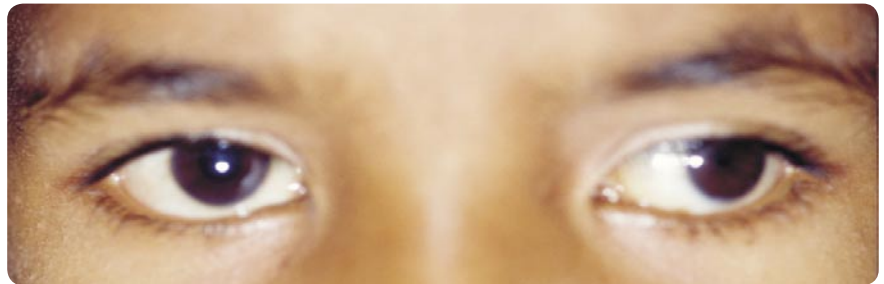*Versions* are binocular, conjugate

movements in the same direction, while *vergences* are binocular disconjugate movements in opposite directions.

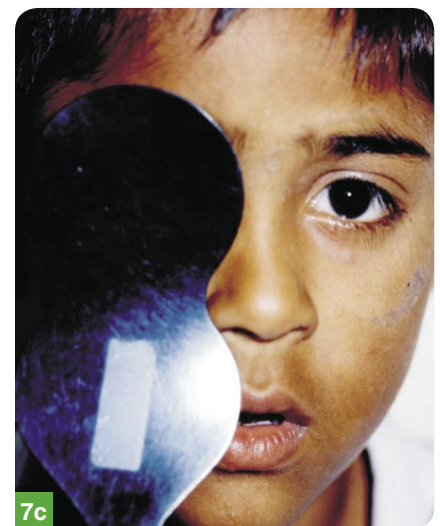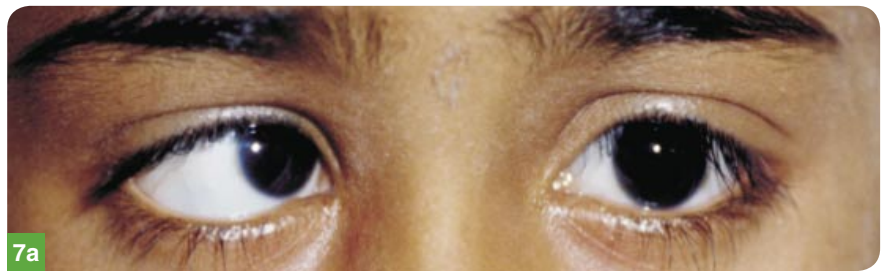Further information regarding ocular alignment can be elicited by performing the *corneal light reflex test*. This is done by shining a penlight onto both corneas simultaneously. The light reflex is normally symmetric in both eyes.

The *cover test* is a more accurate test for ocular misalignment (see Figure 7) than the corneal light reflex test. In Figure 7a, the child with esotropia is taking up fixation with the left eye. When the left eye is occluded, the right eye takes up fixation while the patient is focusing on an object (Figure 7b). When the right eye is occluded, the left eye once again takes up fixation (Figure 7c).

**Figure 7:** Patient with exotropia (note the corneal reflex on the left eye displaced nasally); see cover test in a, b and c below



Patients with strabismus (squints) need referral for appropriate management.

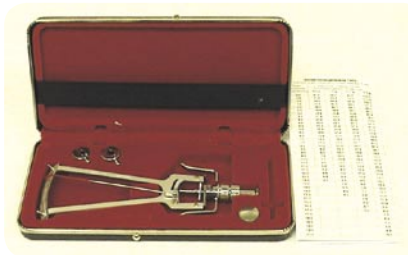
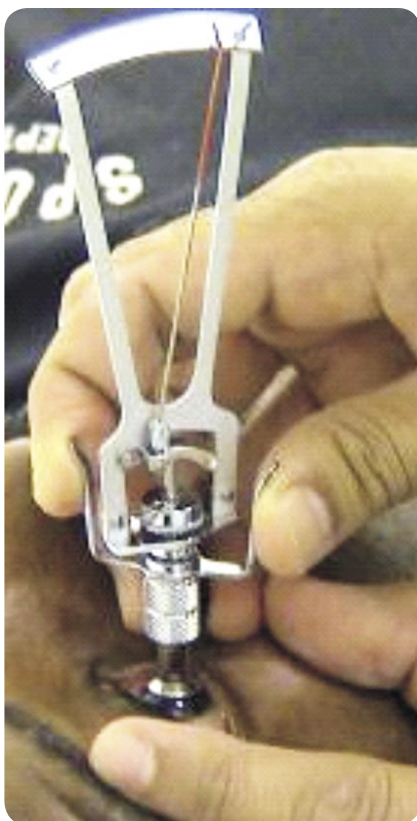
**Glaucoma**

*Glaucoma* is a sight-threatening condition and the accurate measurement of intraocular pressure (IOP) is vital in order to institute early and effective treatment. The most accurate instrument for the measurement of IOP is the Goldmann applanation tonometer, which is used in conjunction with a slitlamp. This is not always feasible in general practice. The indentation, or Schiøtz tonometer (see Figure 8), is portable and easy to use after some practice.<sup>6</sup>

The patient lies supine and should avoid squeezing the eyelids closed. A drop of topical anaesthetic is instilled into each eye. A plunger with a preset weight is placed on the cornea. The tonometer scale reading is converted into mmHg by using standard conversion tables. It is imperative to clean the Schiøtz tonometer with alcohol after each use to prevent cross-infections, e.g. viral diseases. In some patients, the use of an indentation tonometer has resulted in corneal abrasions due mainly to poor technique. Referral to an ophthalmologist is advised in cases where the IOP exceeds 21 mmHg<sup>7</sup> or where the optic nerve is cupped or excavated.

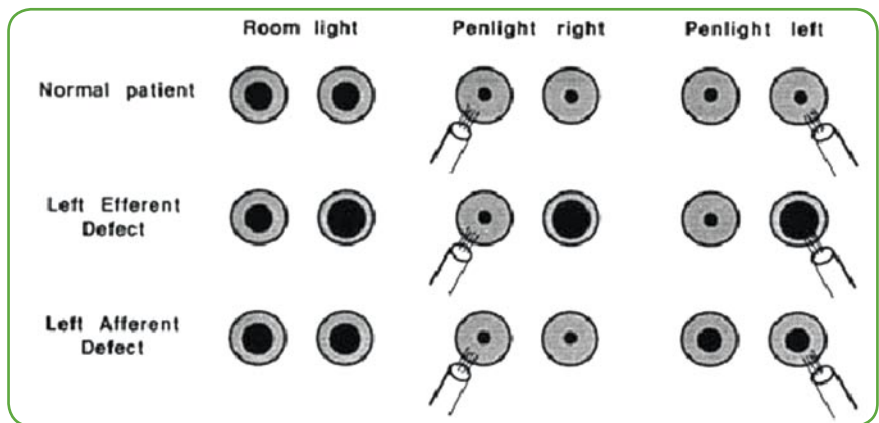
**Figure 8:** Schiøtz tonometer



**Pupil assessment**

A penlight is an inexpensive yet indispensable tool used in pupillary assessment. The size and shape of each pupil should be noted. Pupillary reflexes should be elicited under ambient light conditions. Pupillary responses in efferent and afferent pupil defects are illustrated in Figure 9.<sup>8</sup>

**Figure 9:** Pupillary defects



The following conditions commonly cause pupillary abnormalities:<sup>3</sup>

- Anisocoria (pupils that differ in size): Benign idiopathic anisocoria, where neither pupil is abnormal, cranial nerve III palsy (the larger pupil is abnormal, extraocular and levator muscle palsy is usually present), Horner's syndrome (the smaller pupil is abnormal), ocular trauma or inflammation, prescription or 'over-the-counter' eye drops. Argyll Robertson (Luetic) pupil.
- Weak reaction to direct light: optic nerve or retinal disease
- Relative afferent pupillary defect (RAPD): optic neuritis, ischaemic optic neuropathy, chiasmal area tumours, retinal artery or vein occlusion, retinal detachment and angle closure glaucoma.

An RAPD is **not** seen in patients with media opacities, refractive errors, functional visual loss or cortical lesions.<sup>9</sup>

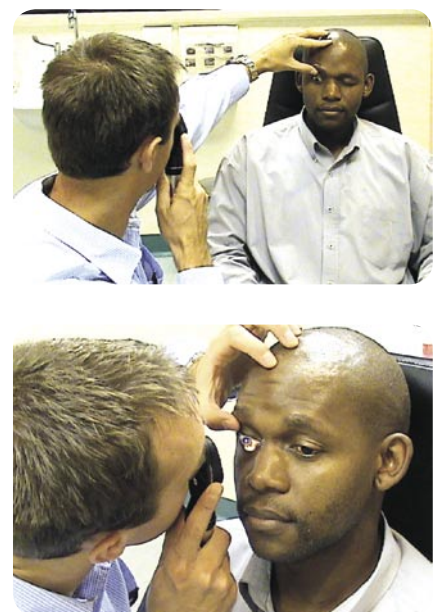
**Direct ophthalmoscopy**

The direct ophthalmoscope is a useful tool for examining the optic disc and posterior pole. The best view is achieved when the pupils are dilated with drops, e.g. Tropicamide 1%. Direct ophthalmoscopy is performed with the examiner's eye corresponding to the eye being examined (see Figure 10).<sup>3</sup> The examiner should wear his or her glasses or contact lenses during the exam. The patient is requested to fixate on a distant target. The patient's upper eyelid should be supported by the examiner's thumb.

Set the ophthalmoscope dioptic power to 0. Note the normal red reflex. A reduced or absent red reflex usually indicates opacities in the ocular media.

Approach the eyelashes as close as possible, aiming the beam 15° nasally towards the optic disc.

**Figure 10:** Technique of fundus examination



Adjust the dioptric power to achieve the best focus on the optic nerve. Examine the fundus as illustrated in Figure 11.<sup>3</sup> Carefully evaluate the optic disc, retinal vessels, retina and macula. A normal fundus is illustrated in Figure 12.

Some important causes of ophthalmoscopic abnormalities:<sup>3</sup>

- **Absent or dull red reflex:** corneal opacity, hyphaema, cataract and vitreous haemorrhage
- **Optic disc cupping:** glaucoma
- **Optic disc pallor:** optic nerve disease
- **Raised and indistinct optic disc margins:** papilloedema (raised intracranial pressure), optic neuritis
- **Retinal arteriolar silver wiring, arteriovenous nicking:** long-standing systemic hypertension
- **Retinal haemorrhage:** diabetes, hypertension, blood disorders, trauma and retinal vein occlusion
- **Cotton wool spots:** hypertension, diabetes, connective tissue disease, blood disorders, AIDS
- **Hard exudates:** diabetes

**Conclusion**

With these simple tools and a bit of practice, general practitioners can detect most of the common ophthalmological problems and even some of the more serious conditions. 🧑

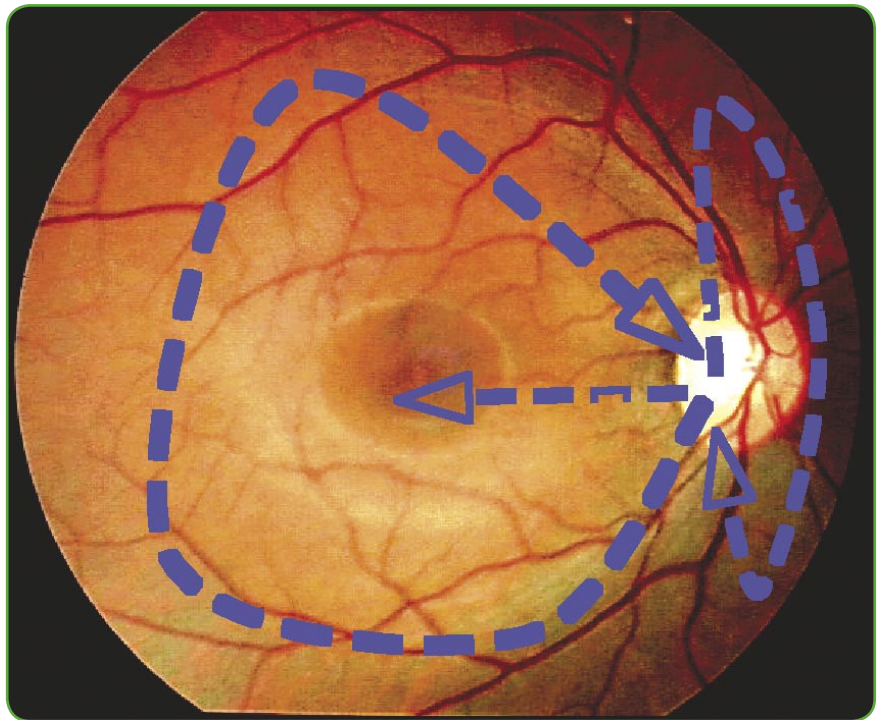
See CPD Questionnaire, page 50

**P** This article has been peer reviewed

**References**

1. American Academy of Ophthalmology. Core Eye Care Benefits Package. San Francisco: American Academy of Ophthalmology; 1993.
2. Best SJ. General practice emergencies in ophthalmology. NZFP 2004;31(1):29-32.
3. Trobe JD. The physician's guide to eye care. San Francisco: American Academy of Ophthalmology; 1993. p. 2-16.
4. Elkington AR, Frank H. Clinical optics. London: Blackwell Scientific Publications; 1984. p. 89-90.
5. The Merck manual of diagnosis and therapy. Section 8: Ophthalmologic disorders. Chapter 90: Approach to the patient with eye disease. Available: [www.merck.com/mrkshared/mmanual/section8/chapter90/90a.jsp](http://www.merck.com/mrkshared/mmanual/section8/chapter90/90a.jsp)
6. Nissl J. A-Z health guide from WebMD: Medical tests: Tonometry. Available: [www.webmd.com/hw/health\\_guide\\_atoz](http://www.webmd.com/hw/health_guide_atoz)
7. Kanski JJ. Clinical ophthalmology: a systemic approach. 4th ed. Butterworth Heinemann; 1999. p. 189.
8. Yung CW. Introduction to ophthalmology for senior medical students. Indiana University School of Medicine.
9. American Academy of Ophthalmology. Basic and clinical science course. Section 5: Neuro-ophthalmology; 1998-1999. p. 104.

**Figure 11:** Examination of fundus – starting at the optic disc, follow the viewing path indicated by the arrows



**Figure 12:** Normal fundus

