

Fine Needle Aspiration Biopsy in a Rural Family Practice

O'Mahony, D, MBBCh, DCH, DTM&H, DPH, Dip Mid COG (SA), FRCGP
Family Practitioner, Bridge Street, Port St Johns

Banach, L, MDPH, MIAC
Associate Professor, Department of Pathology, and Director, Telemedicine Unit,
Faculty of Health Sciences, University of Transkei, Umtata

Correspondence: D O'Mahony, PO Box 27, Port St Johns, South Africa 5120,
omahonyd@cybertrade.co.za

Keywords: Fine needle aspiration, biopsy, cytology, tumours, general practice

Abstract

Background: Fine Needle Aspiration Biopsy (FNAB) is a safe economic method of obtaining tissue from a suspicious mass for diagnostic purposes. This study describes the results of FNAB in a family practice in a poor rural community.

Methods: Any patient with a suspicious mass that the family practitioner considered could be safely aspirated percutaneously underwent FNAB. Masses for aspiration were located by means of palpation or ultrasound scan. A 21-gauge 1½-inch or 23-gauge 1¼-inch needle, attached to a 10-mL disposable plastic syringe, was used for FNAB of superficial masses. For percutaneous FNAB of deep-seated organs and masses, a 23 gauge 1¼-inch needle or 3½-inch spinal needle was used. The aspirate was spread on slides and sent for cytopathology analysis.

Results: The cytological diagnoses from 187 FNAB were: malignant 47 (25%), suspicious of malignancy 14 (7%), atypia 10 (5%), tuberculosis 31 (17%) and benign 60 (33%). Twenty-five (13%) were inadequate. The biopsy sites and number (%) were: lymph nodes 97 (52%), liver 30 (16%), subcutaneous masses 25 (13%), lung 18 (10%), thyroid 5 (3%), breast 8 (4%) and other 4 (2%). The yield for a diagnosis of malignancy or TB was 42%.

Conclusions: FNAB is a procedure that can be efficiently performed by a family practitioner and has a substantial diagnostic yield in rural practice in a developing country.

SA Fam Pract 2003;45(5):_____

INTRODUCTION

Fine Needle Aspiration Biopsy (FNAB) can be defined as the removal of a sample of cells, using a fine needle, from a suspicious mass for diagnostic purposes.¹ It is a simple, accurate, fast, economic and safe procedure that can be done in an office setting without anaesthesia and has a high patient acceptance.¹ Hospital-based specialists usually perform FNAB but family practitioners in developed countries also do this procedure.² FNAB, as an alternative to expensive and time-consuming surgical biopsy, is especially suited to family practitioners and non-specialist hospital doctors in developing

countries where there exists an absolute shortage of specialists and resources.³ This study describes the results of FNAB in a family practice in a poor rural community in South Africa.

METHODS

The records of patients who underwent FNAB at a family practice in Port St Johns between May 1997, when the procedure was introduced, and May 2001 were reviewed. The decision to do a FNAB was a clinical one, made by the family practitioner. Masses for FNAB were located by means of palpation or ultrasound scan (with a 3.5 MHz probe) for deep intra-abdominal

or intra-thoracic masses. Ultrasound guidance was not used when performing the biopsies. A 21-gauge 1½-inch or 23-gauge 1¼-inch needle, attached to a 10-mL disposable plastic syringe, was used for FNAB of superficial masses. For percutaneous FNAB of deep-seated organs and masses, a 23 gauge 1¼-inch needle or 3½-inch spinal needle was used. A standard technique was used to aspirate.¹ The following are the essential elements of the technique. The needle is inserted into the mass, which if superficial, is immobilized with one hand. Suction is applied and the needle moved in and out, rather vigorously, in a sawing (cutting) motion, and directed to as many areas of the mass as possible.

Suction is released (so the material does not enter the syringe) before the needle is withdrawn. Upon withdrawal, the needle is disconnected from the syringe. Air is drawn into the syringe, which is then reconnected, to the needle. The needle is placed directly on a glass slide and material is expressed by blowing out the needle. Four smears were made per aspirate of which two were fixed immediately with standard spray fixative and two air-dried. Specimens were processed and read at the Cytology Laboratory, Department of Pathology, University of Transkei.

RESULTS

A total of 187 FNAB were taken.

Sex and Age:

Figure 1 lists the sex and age distribution of the patients. The average age of patients for lymph node biopsy (n=97) was 42 years and that for breast biopsies (n=8) was 45 years, compared to 62 years for the remainder (n=82). For each FNA biopsy site, the number of males and females were similar except for the lung, where males constituted 12 (67%) of 18 patients and the breast, where all 8 patients were female.

Biopsy site and Cytopathology results:

Table I lists the sites of biopsy and the

cytopathology results. The category "benign" includes non-specific inflammation and normal tissue.

Yield:

Of the FNAB, 47 had malignancy and 31 had tuberculosis (TB). Thus, the yield, for a definitive diagnosis, was 42%. For FNAB of lymph nodes, the largest category, the yield was 40%.

Human Immune Deficiency

Status:

Of 97 patients who had lymph node FNAB, 23 underwent HIV ELISA testing. Of these, 20 (87%) were positive.

DISCUSSION

In this study, FNAB provided a positive diagnosis in 42% of patients with suspicious masses. Thus, the family practitioner could then make a definitive decision on the clinical management of these patients. Malignant FNAB results are generally considered definitive with rare false positive results^{1,4,5} and the positive predictive value for a malignant diagnosis approaches 100%.^{6,7} Whilst TB was diagnosed on cytologic criteria, without staining or culture for bacilli, it is appropriate to do so in areas of high TB prevalence.⁸

In the case of malignancy of the

breast and thyroid, and lymphoma, where there is a good chance of cure or remission, the family practitioner referred patients for hospital treatment. Patients with malignancy of the liver and lung and metastatic disease had advanced disease and were considered ineligible for curative treatment. They were counseled on terminal care. Patients with tuberculosis were referred for curative treatment.

Amongst the group of patients without a positive diagnosis on FNAB, those with a report of suspicion of malignancy were referred to hospital for a confirmatory diagnostic procedure. A suspicion of malignancy is invariably confirmed.⁵ The management of the remainder depended on the clinical findings and patient preferences, and included observation without further testing, further FNA biopsy or referral to hospital. A negative FNAB result does not preclude serious disease - absence of proof is not proof of absence.¹ However, the overall ability of FNAB to accurately diagnose malignancy at most sites is more than 90%.⁵

The high yield of TB in patients with peripheral lymphadenopathy is expected in developing countries with high TB prevalences. In studies of FNAB of lymph nodes in India⁹ and Nigeria³, TB accounted for 43% and 26% of cases respectively. In South Africa, a review of 68 lymph node FNAB showed 47% were positive for TB as diagnosed with Ziehl-Neelsen (ZN) staining.¹⁰ In this study, neither ZN staining nor TB culture of lymph node aspirates was done because patients could not afford the cost. The yield of TB would probably have been higher with these additional diagnostic tests. However, as compared to ZN staining and culture, cytopathology can be more accurate in diagnosing TB lymphadenitis.⁸ There was a high prevalence of HIV disease in those patients that were tested. This is expected in South Africa where an estimated 13% of the 20-64 year age group are HIV positive.¹¹ In view of the rapidly increasing prevalence of the Acquired Immune Deficiency Syndrome (AIDS) and associated TB, FNAB offers a simple method of diagnosing TB lymphadenitis.

FNAB of subcutaneous masses had a high yield of malignant disease. This

Figure I: Age distribution of patients undergoing FNAB (no = 187)

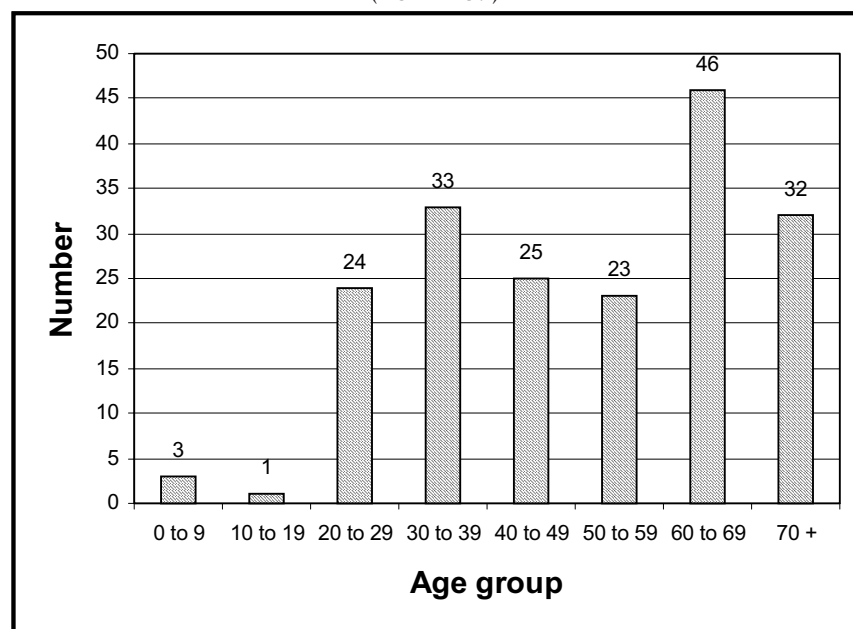


Table I: Site of Fine Needle Aspiration Biopsy and Cytopathology Results

Results	Lymph Nodes	Liver	Sub-cut Mass	Lung	Thyroid	Breast	Other	Totals
Malignant	9	15	15	3	1	3	1	47 (25%)
Suspicious Malignant	5	2	3	-	1	2	1	14 (7%)
Atypia	2	5	1	1	-	1	-	10 (5%)
Tuberculosis	30	-	1	-	-	-	-	31 (17%)
Benign	39	5	3	9	2	-	2	60 (32%)
Inadequate	12	3	2	5	1	2	-	25 (13%)
Total	97	30	25	18	5	8	4	187

Note: "Sub-cut mass" means subcutaneous mass
 "Other" included 1 retro-peritoneal, 1 testicular and 1 parotid mass; and 1 chest wall sinus.

is to be expected, as there is a high probability of malignant disease in any recent-onset isolated expanding mass.

The value of FNAB biopsy in intrathoracic lesions is well recognized.¹² A study of FNAB in peripheral lung lesions in India had a yield (for TB and cancer) of 67%¹³ as compared to 17% in this study. The high yield in the Indian teaching hospital is probably because of the selection bias of patients at very high risk of disease.

Only 25 (13%) smears were inadequate for examination. This compares with 25% in a series by non-specialists in South African hospital⁶ and 4% in a study of FNAB of assorted sites by a multi-disciplinary specialist team in Australia using image guidance when necessary.¹⁴ The family practitioner in this study had no formal training in FNAB techniques. This implies that FNAB is a technique that can readily be used by family practitioners and non-specialist hospital doctors. However, best results are obtained with proper training.¹ Patients readily accepted FNAB. No one refused the procedure and there were no complications.

However, potentially serious and rarely fatal complications can occur.¹ For superficial masses, fatalities are almost non-existent. Pneumothorax can occur if FNAB is done in the vicinity of the chest, including breast, supraclavicular area, or axilla. The clinical manifestations are immediate chest and shoulder pain; occasionally, symptoms may develop up to six hours later (delayed pneumothorax). Chest tube drainage is rarely required.¹ In FNAB

of deep-seated organs, pneumothorax is most likely to occur with trans-thoracic FNAB but can occur during upper abdominal aspirations e.g. liver. In this series, FNAB was only performed on large (adjudged to be segmental or lobar) peripheral lung lesions that abutted on the chest wall as visualized on ultrasound examination. The incidence of complications in FNAB of peripheral lung lesions is low. In a series of 268 FNAB's, 1 (0.4%) patient developed pneumothorax and one haemoptysis occurred.¹⁴ In another series of 134 FNAB's, 5 (3.7%) patients developed pneumothorax.¹⁵ While a chest X-ray is advisable after thoracic FNAB, this was not done in this study in the absence of symptoms suggesting pneumothorax.

In FNAB of the liver, haemorrhage is the most important complication and blood transfusion and surgery may be required. While coagulation studies are advised prior to the biopsy of deep-seated organs,¹ in this study, they were not done. There were logistical problems in that the nearest laboratory was 60 Km away. The majority of patients are poor and many travel long distances to the practice, and cannot afford the cost of the tests or the transport costs of repeated visits. Thus a decision was made to do biopsies unless there was a high-risk of bleeding as indicated by history or examination (e.g. anaemia, jaundice, petechiae). Patients were advised on symptoms of haemorrhage and to return immediately if this occurred. Patients could have been referred to hospital for FNAB or

another diagnostic procedure but it is unlikely that FNAB would have been done. Statistics at the referral pathology laboratory at Umtata indicate that, per annum, only 200 FNAB are done at hospitals in the Transkei region. This may be due to a lack of awareness of the value of FNAB among rural doctors and the lack of time to undertake diagnostic procedures in under-staffed public hospitals.

The risk of complications must be kept in perspective. Fatalities are extremely rare. For deep-seated FNAB, the risk averages 1 in 10,000 cases.¹ The risks must be balanced against potential benefits. When a definitive diagnosis is made, patients are spared the costs (financial and emotional) of repeated visits to doctors, hospitals and traditional healers in search of an explanation for their illness. Major surgery may be avoided if a diagnosis of malignancy is made.

Core biopsy (CB) is an alternative to FNAB. While there may be a slightly increased yield with CB,¹⁶ the incidence of complications rises exponentially with increasing diameter of the biopsy needle.¹ FNAB has the best safety record of any method of procuring tissue for a morphologic diagnosis.¹

In summary, there is a high diagnostic yield from FNAB in the setting of rural practice in a developing country. FNAB should be used more frequently, especially in view of the rapidly increasing number of people with AIDS and associated TB. □

References

1. DeMay RM. The Art & Science of Cyto-

- pathology. Chicago: *American Society of Clinical Pathologists Press*, 1996. p. 464-481.
2. Phillips WR. Diagnostic and Screening Procedures in Family Practice. *Arch Fam Med* 1993;2:1051-7.
 3. Thomas JO, Adeyi D, Amanguno H. Fine-needle aspiration in the management of peripheral lymphadenopathy in a developing country. *Diagn Cytopathol* 1999 Sep; 21 (3):159-62.
 4. Nicastrì GR, Reed WP, Dziura BR. The accuracy of malignant diagnoses established by fine needle aspiration cytologic procedures of mammary masses. *Surg Gynaecol Obstet* 1991 Jun;172(6):457-60.
 5. Zardawi IM. Fine Needle Aspiration Cytology in a Rural Setting. *Acta Cytol* 1998; 42(4):899-906.
 6. Orell SR, Sterrett GF, Walters MN-I, Whitaker D. *Fine needle Aspiration Cytology*. New York: Churchill Livingstone; 1992. p. 7-23.
 7. Gupta AK, Nayar M, Chandra M. Reliability and limitations of fine needle aspiration cytology of lymphadenopathy; An analysis of 1,262 cases. *Acta Cytol* 1991;35:777-83.
 8. Gupta SK, Chugh TD, Sheikh ZA, Al-Rubah NAR. Cytodiagnosis of Tuberculous Lymphadenitis. *Acta Cytol* 1993;37(3):329-332.
 9. Dandapat MC, Mishra BM, Dash Sp, Kar PK. Peripheral lymph node tuberculosis: a review of 80 cases. *Br J Surg* 1990;77:911-912.
 10. Parrish AG. Fine-needle aspiration of lymph nodes (letter). *SAMJ* 1997;87:342
 11. South African Health Review. Durban: Health Systems Trust; 2000.
 12. Weisbrod GL. Transthoracic needle biopsy. *World J Surg* 1993 Nov-Dec;17(6):705-1
 13. Kushwaha SK, Sachan AS, Gupta A, Gupta R, Sharma RD. Efficacy and safety of unguided percutaneous fine needle aspiration cytology in peripheral lung lesions. *J Indian Med Assoc* 1996 Mar;94(3):105-7.
 14. Scisca C, Rizzo M, Maisano R, Monaco M, Ferrari M, Munao S et al. The role of ultrasound-guided aspiration biopsy of peripheral pulmonary nodules: our experience. *Anticancer Res* 2002;22(4):2521-3.
 15. Knudsen DU, Nielsen SM, Hariri J, Christensen J, Kristensen S. Ultrasonographically guided fine-needle aspiration biopsy of intrathoracic tumors. *Acta Radiol* 1996; 37 (3 Pt 1): 327-31.
 16. Zardawi IM. Fine Needle Aspiration Cytology vs. Core Biopsy in a Rural Setting. *Acta Cytol* 1998;42(4):883-7.