

# Ocular trauma

**Mustak H**, MBChB, DipOphth(SA), Registrar

Division of Ophthalmology, Groote Schuur Hospital; University of Cape Town

**Du Toit N**, MBChB, DipOphth(SA), FRCS(Ed), FCOphth(SA), MMed, Consultant Ophthalmic Surgeon, Senior Lecturer

Division of Ophthalmology, Groote Schuur Hospital; University of Cape Town

**Correspondence to:** Nagib Du Toit, e-mail: nagib.dutoit@uct.ac.za

**Keywords:** ocular trauma, injury to the eye, traumatic vascular events, open globe injury

## Abstract

Ocular trauma is an important cause of unilateral blindness and visual impairment across the world. Most injuries are accidental, work-related injuries in developed countries, while assaults predominate as a cause in developing countries. Trauma may result in various forms of ocular injuries, ranging from minor insult to major functional impairment. Any ocular structure may be involved, and a careful, systematic approach to the examination of a patient is essential to avoid missing occult injury and resultant visual impairment. This paper highlights key points regarding the clinical evaluation of patients with ocular trauma and covers the presentation and primary care management of the more common ocular injuries.

© Peer reviewed. (Submitted: 2013-08-16 Accepted: 2013-09-19). © SAAFP

S Afr Fam Pract 2014;56(2):88-94

## Introduction

Trauma is the most important cause of unilateral blindness in the world.<sup>1,2</sup> Up until the end of the last century, it accounted for approximately 1.6 million cases of blindness, 2.3 million cases of bilateral visual impairment and 19 million cases of unilateral vision loss worldwide.<sup>1</sup> The cause of the injuries varies. Work-related accidental injuries are prevalent in developing countries, while assaults are an important cause in developing urban communities.<sup>1,2,3</sup> Men are at significantly higher risk (approximately four times higher) than women. Almost half of all reported injuries occur in people aged 18-45 years.<sup>2</sup>

Injuries range from mild to severe, and can affect any anatomical structure of the eye. However, most injuries tend to be minor and affect the structures of the ocular surface.<sup>4</sup> A systematic and thorough examination is critical to ensure that sight-threatening injuries are not missed and are appropriately managed.<sup>4,5</sup>

## Approach to the patient

The evaluation of ocular trauma should follow the principles of a focused history, systematic examination and appropriate special investigations.

A focused history is valuable in anticipating and determining the nature and severity of the injury. Many injuries occur in the workplace. It is important to obtain information on the circumstances of the incident, as well as the use of appropriate protective eyewear.<sup>4,5</sup> The mechanism and object involved inform the nature of the tissue destruction. Blunt objects result in tissue contusion, and if severe, may

cause globe rupture, while sharp objects cause lacerating and penetrating injuries. The exact time of the injury is also important in determining the treatment strategy.<sup>5</sup>

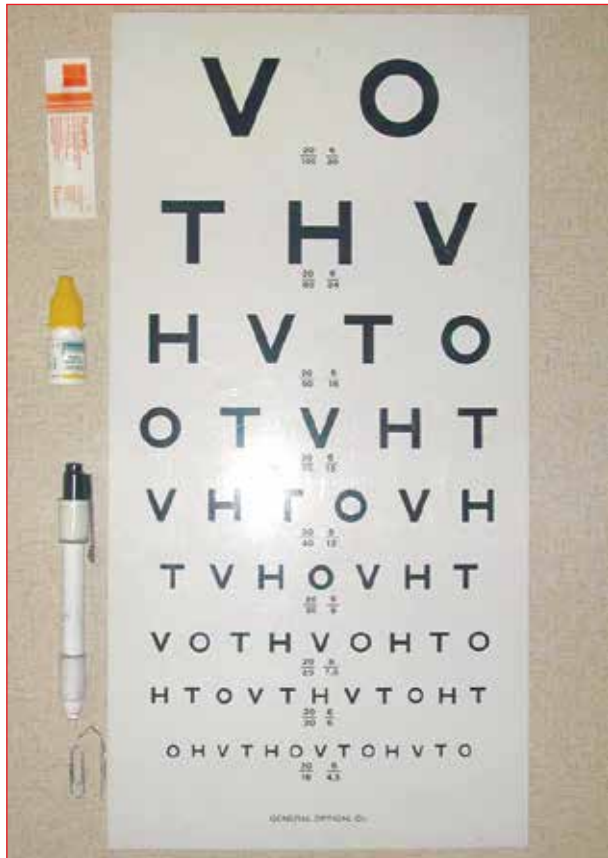It is important to remember that any anatomical structure may be involved. Table I outlines the more common eye injuries. A systematic “front to back” approach to examination should be employed.<sup>4,5</sup> Basic evaluation involves inspection, which may be facilitated by the use of local anaesthetic drops and a speculum (if lid swelling is present). Figure 1 lists items that facilitate examination of the injured eye, and Figure 2 specula that can be used to pry the swollen eyelids apart. Visual acuity should be measured and documented as it is the most informative measure of ocular function, and is a prognostic factor in severe ocular trauma.<sup>4,5</sup> Eye movements should then be checked to determine deficits in ocular motility. An ocular movement exam should be omitted if the patient is suspected of having an open globe injury, in order to prevent prolapse of the intraocular contents. Each anatomical structure of the eye should then be examined with the aid of a good light source. Examination should begin with the lids and skin, followed by careful examination of the conjunctiva, cornea and sclera. If a corneal abrasion is suspected, the instillation of fluorescein drops will help to confirm the diagnosis.<sup>4</sup> Pupil responses should be tested and a note made on the presence of a relative afferent pupil defect. It should then be determined if there is red reflex, followed by fundoscopy.

Imaging is a useful adjunct for further evaluation of the patient. Following blunt trauma, orbital and skull X-rays are useful in confirming fractures of the orbital wall and cranium. Orbital X-rays are also useful in verifying the

**Table I:** The more common injuries following ocular trauma


| Sharp or lacerating trauma                                 |
|--|
| Eyelid laceration (with or without lid margin involvement) |
| Conjunctival haemorrhage and laceration                    |
| Lacerated extraocular muscles                              |
| Orbital foreign body                                       |
| Corneal foreign body                                       |
| Corneal laceration   |
| Scleral laceration   |
| Intraocular foreign body                                   |
| Carotid-cavernous fistula                                  |
| Blunt trauma   |
| Lid haematoma  |
| Subconjunctival haemorrhage                                |
| Muscle contusion with abnormal movements                   |
| Subperiosteal haematoma                                    |
| Orbital blowout fracture                                   |
| Corneal abrasion   |
| Hyphaema   |
| Globe rupture  |
| Subluxed or dislocated lens                                |

presence and location of intraocular foreign bodies. Patients who have sustained penetrating injuries will require a computed tomography (CT) scan of the head to exclude possible intracranial injury.<sup>4,5</sup> Minor injuries can be managed



Source: The Division of Ophthalmology, University of Cape Town

**Figure 1:** Snellen's chart, a pen torch, and other "tools" needed to assess the traumatised eye



Source: The Division of Ophthalmology, University of Cape Town

**Figure 2:** Desmarre retractors and paper clips bent for use as retractors

**Table II:** Management of ocular injuries

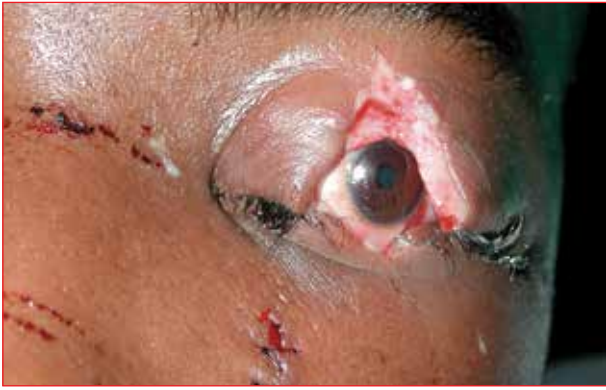| Primary care   |
|--|
| Eyelid laceration without lid margin involvement                       |
| Subconjunctival haemorrhage (with an otherwise normal eye examination) |
| Conjunctival foreign body  |
| Small corneal abrasions  |
| Initial treatment of chemical injuries                                 |
| Secondary or tertiary care   |
| Eyelid laceration with lid margin involvement                          |
| Conjunctival haemorrhage and laceration                                |
| Abnormal eye movements following trauma                                |
| Orbital blowout fracture   |
| Corneoscleral laceration   |
| Hyphaema   |
| Globe rupture  |
| Subluxed or dislocated lens  |
| Corneal or intraocular foreign bodies                                  |

at primary care level, while severe injuries require referral to a specialist for further treatment. This differentiation is outlined in Table II.

### Common eye injuries

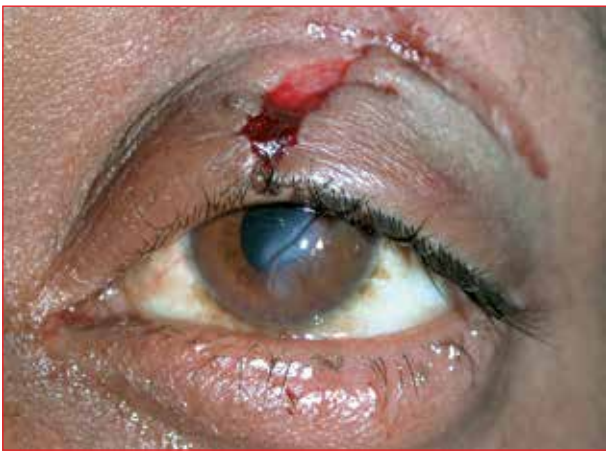#### Lacerations of the eyelids

The eyelids may be lacerated with sharp object injury or avulsed with blunt object injury.<sup>6,7</sup> These injuries may or may not involve the lid margin. The worst injuries usually involve the use of a broken bottle head, and may even result in tissue loss.<sup>5</sup> Human and dog bites to the eye can also cause tissue loss, requiring the need for tissue grafting.<sup>5,7</sup> All three layers of the lid (skin, orbicularis and tarsal plate) may be involved (Figure 3). Repair requires careful anatomical realignment of these structures to prevent lid notching.<sup>5</sup> Clinically, lid lacerations are obvious injuries. It is important to exclude possible globe (Figure 4) penetration<sup>5,7</sup> in cases of sharp object injury, particularly in the presence of a full-thickness laceration. Lacerations involving the medial canthal region may involve the nasolacrimal apparatus, and may result in a chronic "watery" eye if not repaired.<sup>5,6</sup> Lacerations resulting



Source: The Division of Ophthalmology, University of Cape Town

**Figure 3:** Upper and lower lid lacerations involving the lid margins



Source: The Division of Ophthalmology, University of Cape Town

**Figure 4:** Upper lid and corneal lacerations

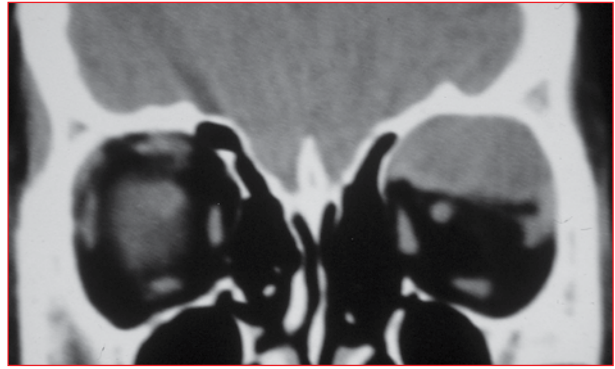
in full-thickness injury, or involving the margin or the medial canthal area, should be referred to an ophthalmologist for careful repair, since incorrect realignment of the tarsal plate may result in a lid margin notch which can cause chronic corneal irritation and scarring.<sup>5</sup>

### Abnormal eye movements

Abnormal ocular movements may follow blunt or sharp injury. Causes may be direct injury to the extraocular muscles (contusion or laceration), or due to mechanical infringement on the muscle (haematoma, blowout fracture or an orbital foreign body).<sup>4</sup>

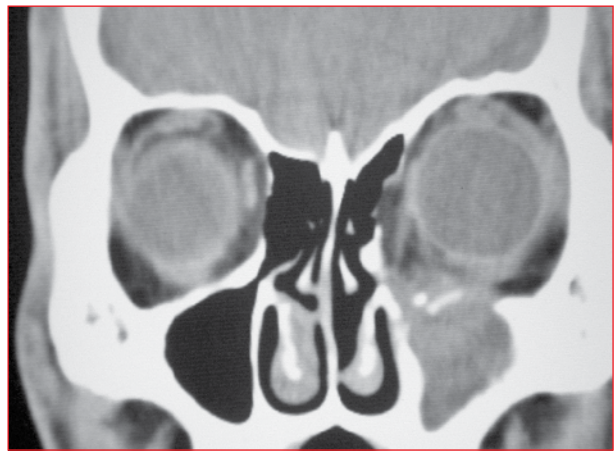
Subperiosteal haematoma is a result of bleeding into the subperiosteal space, commonly following blunt trauma in children and young adults. Classical presentation is with downward proptosis, with an otherwise normal eye. A CT scan is useful to confirm the diagnosis and visualise the blood collection (Figure 5). Patients should be referred for drainage of the collection.<sup>4</sup>

Blowout fractures result from blunt-force injury to the orbit, with the transmitted force causing fracture of the weakest points of the orbit, mainly the floor and medial wall.<sup>4,8</sup> Clinically, the patient will have lack of elevation on attempted up-gaze (due to entrapment of the inferior rectus in the



Source: The Division of Ophthalmology, University of Cape Town

**Figure 5:** Computed tomography scan showing left subdural haematoma



Source: The Division of Ophthalmology, University of Cape Town

**Figure 6:** Computed tomography scan showing left orbital floor fracture with herniation of tissue into the maxillary sinus

fracture), loss of infraorbital sensation and subcutaneous crepitus.<sup>4</sup> Facial X-rays or a CT scan will show opacification of the maxillary sinus because of herniation of the orbital contents (Figure 6) and entrapment of the inferior rectus.<sup>8</sup> Other ocular injuries should be carefully excluded, and the patient referred to an ophthalmologist or maxillofacial surgeon for repair.

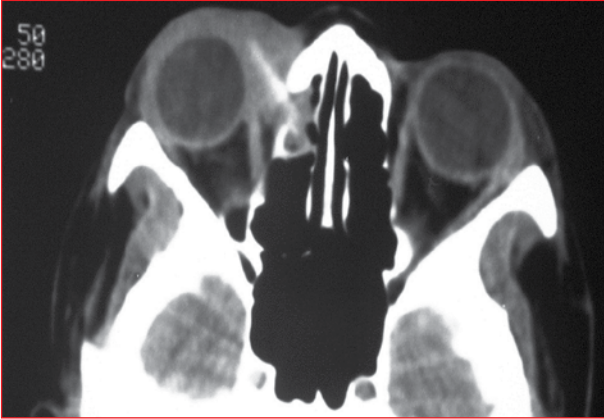
Orbital foreign bodies can cause mechanical restriction.<sup>4,8</sup> The limitation of movement will depend on the site of the foreign body and the affected muscles. A CT scan will confirm the presence of an orbital foreign body (Figure 7). Patients should be referred for removal of the foreign body.

### Foreign bodies

Ocular foreign bodies are commonly acquired at the workplace, particularly if appropriate protective eyewear is not worn.<sup>3,4</sup> Common activities resulting in foreign bodies are grinding, hammering, drilling and sawing. Foreign bodies can either be found on the conjunctiva (bulbar and tarsal) or cornea, or may be intraocular.

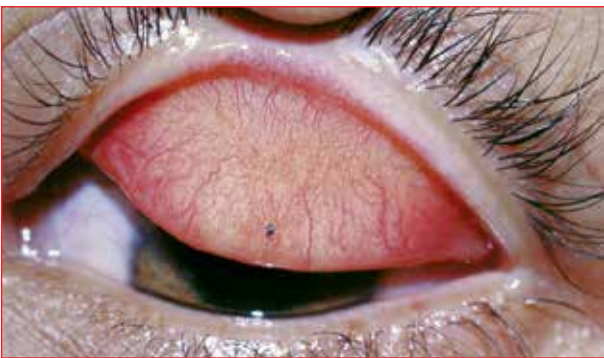It is important to take a detailed history of the exact mechanism of injury and materials involved in order to know what type of injury to expect.<sup>3,4,6</sup> Activities such as





Source: The Division of Ophthalmology, University of Cape Town

**Figure 7:** Right orbital foreign body extending into the ethmoid sinus



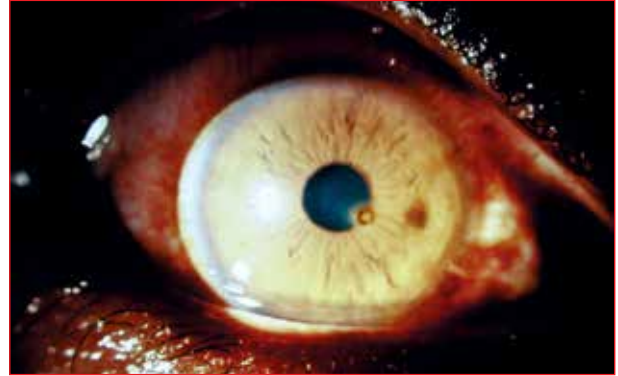
Source: The Division of Ophthalmology, University of Cape Town

**Figure 8:** Subtarsal foreign body

grinding result in low-velocity projectiles which often embed in the conjunctiva or cornea, while higher-velocity shrapnel, e.g. from hammering, is more likely to penetrate the globe and lodge intraocularly.<sup>4</sup> Patients will complain of a foreign body sensation. The affected eye will be red, painful and photophobic. The foreign body may be clearly seen as a dark spot on the conjunctiva or cornea. It may also be lodged in the tarsal conjunctiva (Figure 8), and can be missed if the lids (especially the upper lid) are not everted.<sup>4,6</sup> Fluorescein staining is useful in these cases when searching for linear corneal abrasions that may result from a subtarsal foreign body rubbing against the cornea.

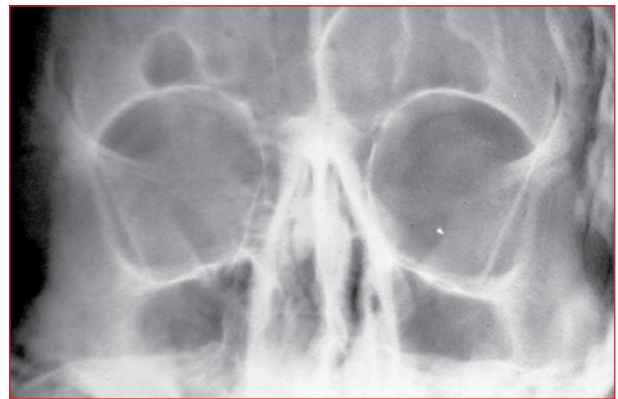
Conjunctival foreign bodies may be removed with a cotton bud, following the instillation of local anaesthetic drops. Corneal foreign bodies may be removed (Figure 9) in a similar fashion after liberal use of topical anaesthesia, and clear instructions given to the patient regarding the procedure.<sup>4</sup> If the foreign body persists, then the patient should be referred to an ophthalmologist.

X-rays (or a CT scan, if available) are useful imaging modalities to confirm diagnosis and the location of an intraocular foreign body (Figure 10). Cases of intraocular foreign bodies must be referred to an ophthalmologist for further management. Missed foreign bodies can result in conditions such as endophthalmitis, particularly if organic matter is involved, or siderosis bulbi, if iron is involved.<sup>4,6</sup>



Source: The Division of Ophthalmology, University of Cape Town

**Figure 9:** Residual corneal rust ring after foreign body removal



Source: The Division of Ophthalmology, University of Cape Town

**Figure 10:** Intraocular foreign body visible on X-ray

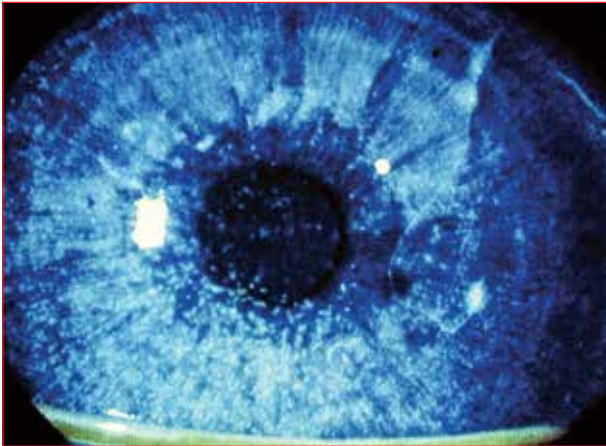
Metallic foreign bodies, particularly iron and copper, are toxic to the retina and cause yellow-brown discolouration of the ocular tissue.

### Corneal abrasions and erosions

Abrasions and erosions of the cornea are common injuries.<sup>6,9</sup> Abrasions are caused by scratches from minor trauma, i.e. by fingernails, paper and sand. Erosions tend to occur as a result of excessive ultraviolet (UV) exposure, with resultant epithelial damage, such as welding, glass blowing and tanning on sunbeds, without wearing protective goggles. These lesions tend to be painful as a result of epithelial loss and exposure of the underlying nerve endings.<sup>4</sup>

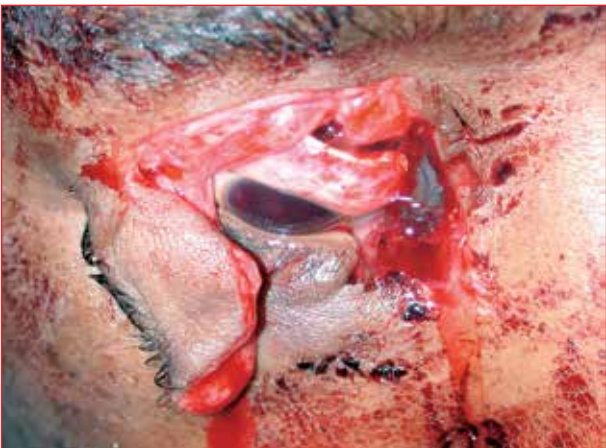Patients present with a history of minor trauma to the eye or of excessive UV exposure. The affected eye or eyes are red and painful, and there is excessive lacrimation.<sup>4,9</sup> Fluorescein drops should be instilled to allow confirmation of the epithelial injury. A single linear defect is often seen in abrasions, while erosions tend to result in multiple punctate (Figure 11) lesions.<sup>4</sup>

Corneal epithelial recovery is rapid, and the management of abrasions and erosions essentially involves pain relief and infection prevention.<sup>4,6,9</sup> Cycloplegics should be prescribed to relieve associated ciliary spasm, analgesics taken for pain, and chloramphenicol ointment used as prophylaxis against secondary infection, while padding of the eye



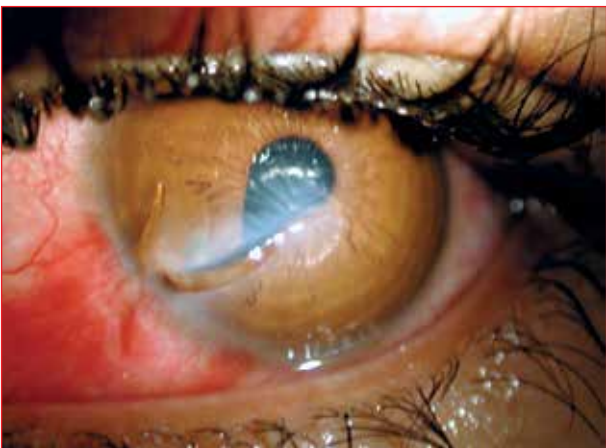Source: The Division of Ophthalmology, University of Cape Town

**Figure 11:** Multiple corneal erosions after welding without protective goggles



Source: The Division of Ophthalmology, University of Cape Town

**Figure 12:** Severe lid trauma with open globe injury

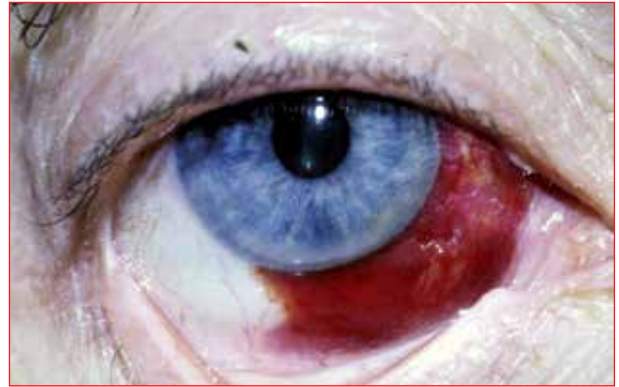

Source: The Division of Ophthalmology, University of Cape Town

**Figure 13:** Open globe injury with iris prolapse through corneal laceration

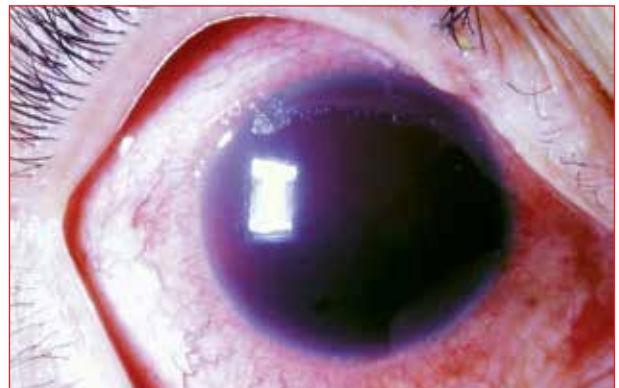will reduce discomfort from blinking and may aid corneal healing.<sup>4</sup> Patients should be advised to return if they are not better within 48 hours. They must be advised to wear UV protection as a preventative measure.

Patients with large defects, or defects involving the visual axis, should be referred for further evaluation. While local



Source: The Division of Ophthalmology, University of Cape Town

**Figure 14:** Subconjunctival haemorrhage



Source: The Division of Ophthalmology, University of Cape Town

**Figure 15:** Hyphaema filling the anterior chamber

anaesthetic drops provide immediate pain relief, they should not be prescribed for patients to take home. A local anaesthetic inhibits corneal healing, and will make the patient unaware of any further insult to the cornea.<sup>4,9</sup>

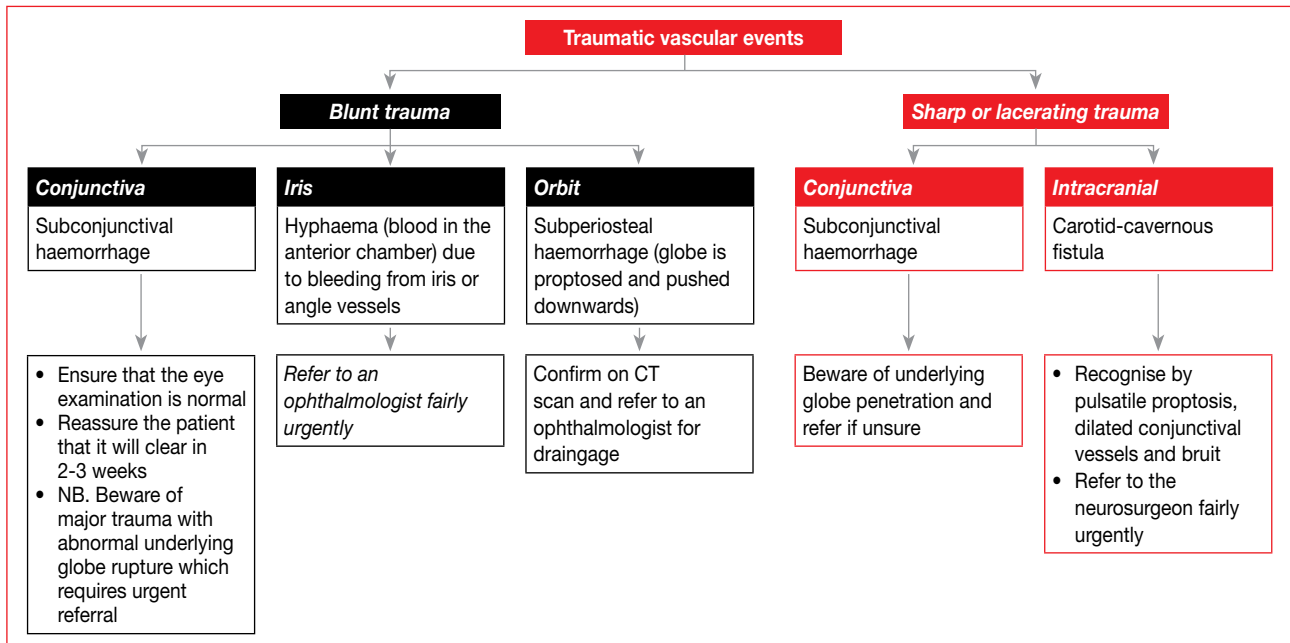
### Penetrating injury or globe rupture

A sharp or severe blunt injury can result in globe disruption.<sup>4,10</sup> Most injuries will be obvious on simple inspection (Figure 12). However, some injuries may seem innocuous, but if subtle signs are not anticipated, or if there is not a high index of suspicion, then sight-threatening injuries may be missed.<sup>4,5</sup>

Signs of globe disruption include reduced visual acuity, distortion or an abnormally shaped pupil with poor pupillary response, prolapse of the brown uveal tissue at the wound site (Figure 13), reduced red reflex as a result of vitreous haemorrhage, hyphaema (blood in the anterior chamber), and an anterior chamber that appears deeper than the normal, fellow eye.<sup>4,5,10</sup> A high index of suspicion of globe penetration must be maintained for full-thickness lid lacerations, as well as sharp object injuries around the periorbita.<sup>4</sup>

Management requires referral to an ophthalmologist within 24 hours for globe repair. While awaiting ophthalmology referral, drops should not be instilled in the eye. This is to prevent potentially toxic preservatives from affecting





CT: computed tomography

**Figure 16:** Approach to traumatic vascular events

exposed intraocular tissue. A shield should be placed over the eye, without an underlying pressure dressing, in order to avoid further prolapse of intraocular content.<sup>4</sup> Patients with open globe injuries will require a CT scan of the head to exclude retained foreign material, as well as intracranial injury.

### Traumatic vascular events

Subconjunctival haemorrhage is common after minor trauma, coughing or valsalva manoeuvres.<sup>4</sup> It can also occur spontaneously in patients with hypertension, bleeding diathesis or those on anticoagulant medication.<sup>6</sup> It presents as a red area on the bulbar conjunctiva (Figure 14), which is easily identifiable as blood. It is usually painless, but patients may occasionally complain of mild discomfort. Management is often conservative provided the visual acuity, pupil response, eye movements and fundus examination are all normal, and there is no suspicion or sign of globe rupture. Patients with bilateral subconjunctival haemorrhage and an inability to identify the posterior extent thereof may be associated with an anterior base-of-skull fracture.<sup>4</sup>

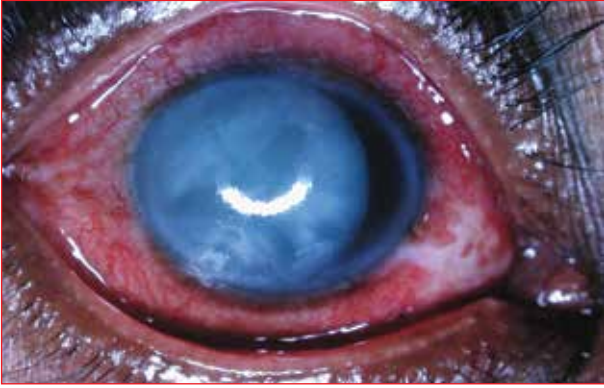Hyphaema usually occurs after blunt trauma, and its severity can vary from mild (dispersed blood cells in the anterior chamber) to an anterior chamber filled with blood (Figure 15); the so-called “8-ball” hyphaema.<sup>4,11</sup> Vision may be reduced according to the severity of the injury. Patients may experience pain, particularly if the intraocular pressure is raised. Most commonly, a fluid level of settled blood can be seen in the inferior part of the anterior chamber. Hyphaema can be complicated by a rebleed which most commonly occurs in the first five days following the initial bleed, and blood may also obstruct the trabecular meshwork, resulting

in elevation of the intraocular pressure.<sup>4,11</sup> Prolonged raised intraocular pressure may, in turn, result in retinal vascular obstruction and corneal staining.<sup>4</sup> Thus, patients must be referred to an ophthalmologist within 24 hours to avoid these complications.

Carotid cavernous fistula most commonly occurs as a result of penetrating eye injury, but may follow blunt trauma, particularly with base-of-skull fractures. There is direct arteriovenous communication between the internal carotid artery and the cavernous sinus. Patients present with conjunctival chemosis and dilated vessels, a pulsatile proptosis and a bruit on auscultation. A CT angiogram will confirm the diagnosis, and these patients require neurosurgical referral for embolisation of the fistula in order to prevent glaucoma, optic nerve and retinal damage.<sup>4</sup> A schematic approach to these injuries is illustrated in Figure 16.

### Lens subluxation or dislocation

Repeated episodes of blunt trauma, or even a single episode of severe blunt trauma, can result in iris sphincter and lens zonular injury.<sup>12</sup> The lens may then become partially displaced within the pupillary zone, or dislocate completely, either into the vitreous or the anterior chamber.<sup>4,12</sup> Anterior lens dislocation can be complicated as it causes trabecular outflow obstruction, and thus elevated intraocular pressure. If it is observed that the lens has dislocated into the anterior chamber (Figure 17), and the eye feels hard and the patient has pain, referral to an ophthalmologist is necessary, usually within 24 hours for lens extraction.<sup>4</sup> Acetazolamide 500 mg orally should be administered in these cases, while awaiting the ophthalmology consultation.



Source: The Division of Ophthalmology, University of Cape Town

**Figure 17:** Cataractous lens dislocated into the anterior chamber

### Chemical injury

Chemical injuries most commonly occur in the workplace when adequate eye protection is not used.<sup>4,6,13</sup> They should never be regarded as being innocuous, and immediate management should be instituted prior to referral to an ophthalmologist for formal assessment.<sup>4,6</sup> The most common offending agents are alkaline in nature (commonly detergents and cleaning agents), followed by acids and particulate chemicals.<sup>13</sup> Alkalis are more likely to result in serious ocular damage since these agents can readily diffuse through the cornea (Figure 18) to cause intraocular damage. Acidic agents tend to cause surface coagulation which prevents further penetration.<sup>4,13</sup> Chemical damage can range from mild irritation to severe corneal and intraocular injury, resulting in visual loss.

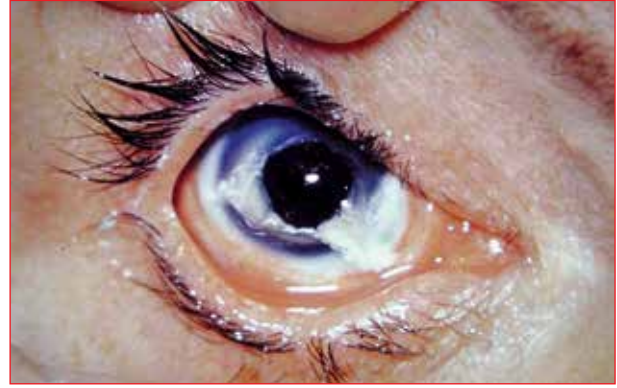
The mainstay of treatment is copious irrigation of the affected eye.<sup>4,13</sup> Local anaesthetic drops should be instilled. The lids may need to be held open and the eye irrigated (Figure 19) for at least 30 minutes. If readily available, litmus or pH sticks can be used to determine the nature of the agent, but this should not delay irrigation. The fornices must be swept with a cotton bud to remove particulate matter. Patients should then be urgently referred to an ophthalmologist for further evaluation and management.

### Conclusion

Ocular trauma is an important cause of visual impairment and unilateral blindness. The majority of injuries tend to be minor and can be managed in the primary healthcare setting. Knowledge of ocular anatomy, as well as careful examination, is crucial in the identification of vision-threatening injuries. Features of severe injury include marked visual loss and a relative afferent pupil defect. Imaging modalities should be used in cases of severe injuries as a routine. If there is any doubt as to the nature and extent of the injury, patients should be referred to an ophthalmologist for further assessment.

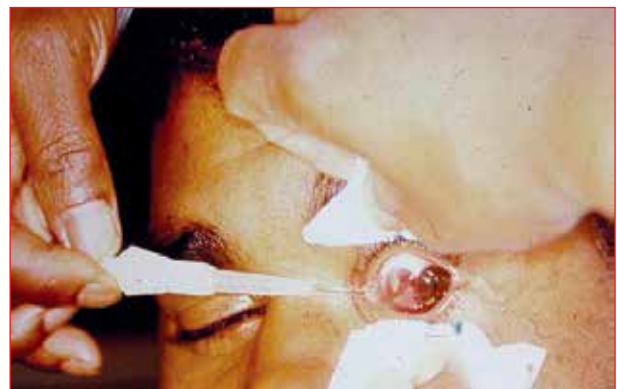### Acknowledgements

The Division of Ophthalmology of the University of Cape Town is thanked for providing permission for the use of its clinical photographs.



Source: The Division of Ophthalmology, University of Cape Town

**Figure 18:** Severe chemical injury to cornea with a deceptively "white" eye



Source: The Division of Ophthalmology, University of Cape Town

**Figure 19:** Irrigation of the eye after chemical injury

### Conflict of interest

The authors declare no conflict of interest.

### References

1. Négrel AD, Thylefors B. The global impact of eye injuries. *Ophthalmic Epidemiol.* 1998; 5(3):143-69.
2. Thylefors B. Epidemiological patterns of ocular trauma. *Aust NZ J Ophthalmol.* 1992;20(2):95-98.
3. Kuhn F, Mester V, Morris R, Dalma J. Eye injury epidemiology and prevention of ophthalmic injuries. In: Kuhn F, editor. *Ocular trauma: principles and practice.* New York: Thieme, 2002; p. 14-22.
4. Du Toit N, Cook C. *Ocular trauma.* Cape Town: Juta, 2009; p. 46-52.
5. Kuhn F, Pieramici D. Designing the management strategy. In: Kuhn F, editor. *Ocular trauma: principles and practice.* New York: Thieme, 2002; p. 38-52.
6. Khaw P, Shah P, Elkington A. Injury to the eye. *BMJ.* 2004;328(7430): 36-38.
7. Long J, Tan T. Eyelid and lacrimal system trauma. In: Kuhn F, editor. *Ocular trauma: principles and practice.* New York: Thieme, 2002; p. 373-383.
8. Long J, Tan T. Orbital trauma. In: Kuhn F, editor. *Ocular trauma: principles and practice.* New York: Thieme, 2002; p. 383-392.
9. Wipperman J, Dorsch J. Evaluation and management of corneal abrasions. *Am Fam Physician.* 2013;87(2):114-120.
10. Dalma-Weiszhausz J. Extrabulbar tissue prolapse. In: Kuhn F, editor. *Ocular trauma: principles and practice.* New York: Thieme, 2002; p. 123-131.
11. Walton W, Von Hagen S, Grigorian R, Zarbin M. Management of traumatic hyphema. *Surv Ophthalmol.* 2002;47(4): 297-331.
12. Mester V, Kuhn F. Lens. In: Kuhn F, editor. *Ocular trauma: principles and practice.* New York, Thieme, 2002; p. 180-197.
13. Wagoner M, Kenyon K. Chemical injuries: clinical course and management. *Ocular trauma: principles and practice.* New York: Thieme, 2002; p. 335-350.