

## Ansa brachii from a median-musculocutaneous trunk: an anatomical variation - a case report

**Authors:** J. P. Rugambwa<sup>1,2,\*</sup>; O. Kubwimana<sup>1,2</sup>; F Hirwa<sup>3</sup>; E. Rafiki<sup>3</sup>; S. Olorunnado<sup>1</sup>; J. Gashegu<sup>1</sup>

**Affiliations:** <sup>1</sup>Department of Anatomy, University of Rwanda; <sup>2</sup>Department of Surgery, University Teaching Hospital of Butare (CHUB), University Teaching Hospital of Kigali (CHUK); <sup>3</sup>Surgical Postgraduates, University of Rwanda

### ABSTRACT

Anatomical variations in humans are widespread but highly complex. A thorough understanding of anatomy is essential for successful surgical and anesthetic procedures. Brachial plexus anatomical variations are prevalent and account for more than 50% of anatomical variations in cadaveric analyses of the human nervous system. Clinical outcomes may be unsatisfactory if specific brachial plexus anatomical variations are overlooked. In 22% of axillary blocks, the musculocutaneous nerve location was found to be irregular. It may be joined to the median nerve and extended distally before disconnecting from it or may be located close to the axillary artery more frequently. Hence, understanding the anatomy of the brachial plexus is necessary for excellent clinical outcomes in upper extremity surgical procedures.

We identified a complex left brachial plexus anatomical variation during the upper limbs dissection course. From the lateral cord, two parallel nervous brands emerge as the musculocutaneous nerve and median nerve fusing into the median-musculocutaneous common trunk. Distally, this trunk forms the ansa brachii that gives the nerve to the biceps brachii muscle, the nerve to the brachialis muscle, and the lateral cutaneous nerve of the forearm. Four branches from the lateral cord, the musculocutaneous nerve, and the median-musculocutaneous trunk sequentially innervated the coracobrachialis muscle.

Successful upper extremity surgery and anesthesia need a thorough understanding of the human brachial plexus anatomy and its variations. Additional research and dissections are encouraged to understand human anatomy and its variations.

**Keywords:** Anatomical Variation, Brachial Plexus, Musculocutaneous Nerve, Clinical Implications, Case Report

### INTRODUCTION

Human anatomy anatomical variations are quite common; however, they are very complex [1]. A solid understanding of the architecture of the human nervous system can be a success factor in

elective neurosurgeries [2]. In case of emergency, quick surgical response demands an understanding of the human nervous system anatomy due to the urgent conditions of trauma patients [3]. In particular, the upper limbs are vulnerable to traumas in the extremities, but sadly, brachial

**\*Corresponding author:** Jean Paul Rugambwa, email: rugambwarutagambwa@gmail.com, Department of Human Anatomy, College of Medicine and Health Sciences, University of Rwanda; **Funding:** This study was conducted as a part of the second anatomy annual congress in Rwanda, October 15, 2023 sponsored by the UR, Operation Smile, and MMI; **Academic Integrity.** All authors confirm that they have made substantial academic contributions to this manuscript as defined by the ICMJE; **Originality:** All authors: this manuscript is original has not been published elsewhere; **Review:** This manuscript was peer-reviewed by two reviewers of the S-CAR committee

**Received:** 24<sup>th</sup> October 2023; **Accepted:** 17<sup>th</sup> February 2024.

**Copyright:** © The Author(s). This is an Open Access article distributed under the terms of the Creative Commons Attribution License (CC BY-NC-ND) ([click here](https://creativecommons.org/licenses/by-nc-nd/4.0/)) which permits unrestricted use, distribution, and reproduction in any medium, provided the original work is properly cited. **Publisher:** Rwanda Biomedical Centre (RBC)/Rwanda Health Communication Center, P. O. Box 4586, Kigali. ISSN: 2079-097X (print); 2410-8626 (online)

**Citation for this article:** J. P. Rugambwa; O. Kubwimana; F Hirwa et al. Ansa brachii from a median-musculocutaneous trunk: an anatomical variation- a case report. Rwanda Medical Journal, Vol. 81, no. 1, p. 161-166, 2024. <https://dx.doi.org/10.4314/rmj.v81i1.19>

plexus anatomical differences are common [4,5]. The brachial plexus accounts for more than 50% of anatomical variations in cadaveric analyses of the human nervous system [6,7]. The extrinsic thoracic muscles and the upper limb receive motor and sensory innervations from the brachial plexus [1]. Certain variants of the brachial plexus can result in the dispersion of blockades or local anesthetics spreading in an uncontrolled manner [8].

Beginning in the posterior triangle of the neck, the brachial plexus travels distally into the upper extremities. It starts with five nerves and ends with five nerves. Cervical and thoracic spinal cord roots constitute the brachial plexus. It originates from the anterior rami of C5, C6, C7, C8, and the first thoracic nerve. It ends up forming the musculocutaneous, median, ulnar, axillary, and radial nerves [9]. The middle sections are shown in groups of three; the C5 and C6 rami combine to form the superior trunk, the C7 ramus continues as the middle trunk, and the C8 and T1 rami combine to form the inferior trunk [10].

Posterior to the clavicle, each trunk divides into anterior, flexor, and posterior, extensor divisions at the lateral boundary of the first rib. After that, divisions join to form cords, which are distinguished by their location in relation to the second portion of the axillary artery [11]. The anterior divisions of the superior and middle trunks form the lateral cord, the anterior division forms the medial cord, and the posterior divisions of all three trunks form the posterior cord [9].

The cords split and give rise to the five terminal branches of the plexus in the lower region of the axilla. Functionally, the lateral cord functions as the cord of the proximal flexors. The medial cord supplies the distal flexors of the forearm, wrist, and hand, while the posterior cord supplies all the extensor muscles of the upper limb [10]. The medial cord divides into the ulnar nerve (C8-T1) and the medial ramus of the median nerve, whereas the lateral cord splits into the musculocutaneous nerve (C5-7) and the lateral ramus of the median nerve. Thus, the median nerve is composed of both the lateral and medial cords (C5-T1). The axillary nerve (C5,6) and the radial nerve divide from the posterior cord [12].

At the level of the axillary block, the musculocutaneous coming in as a part of the upper part of the lateral cord typically resides in the coracobrachialis muscle or between the

coracobrachialis and biceps muscles. It supplies these muscles, gives sensory branches to the humerus, and is the chief sensory supply to the elbow joint. It then continues as the lateral antebrachial cutaneous nerve, providing sensation to the distal lateral forearm [9,10].

In 22% of axillary blocks, ultrasound has shown that the location of the musculocutaneous nerve is, in fact, irregular [13]. It may be joined to the median nerve or be located close to the axillary artery more frequently. If connected to the median nerve, it can extend distally for a certain distance before disconnecting from it [10].

The median nerve receives the contribution from the lateral cord and the second contribution from the medial cord starts just distal to the lower margin of the pectoralis minor. With the exception of the flexor digitorum profundus medial two divisions to the ring and small fingers, the median nerve supplies the flexor and pronator muscles of the forearm. In the hand, the median nerve supplies part of the short muscles of the thumb, the two radial lumbricals, and the skin covering the central portion of the palm and thenar eminence. It also supplies the palmar skin on the thumb, index, and long fingers and the radial half of the ring finger [9].

A thorough understanding of the anatomy of the brachial plexus is necessary for efficient local anesthetic and effective surgical procedures in the axillary area and the rest of the upper extremities. This case report's objective is to illustrate the brachial plexus architecture variation we encountered during our dissection and its clinical implications.

## CASE PRESENTATION

On 27 January 2023, during the upper limbs dissection course, we identified the anatomical variation of the left upper extremity brachial plexus. We conducted the dissection layer by layer, according to instructions received before starting the upper limbs dissection course, where all structures have to be identified and named. After reaching the brachial plexus, we identified the anatomical variation at the level of the brachial plexus's cords and terminal branches.

The lateral cord gave two parallel bands of nerves, one to form the musculocutaneous nerve and the second to form the lateral root of the median nerve

that met the medial root from the medial cord to form the median nerve. The lateral root of the median nerve seems to be thinner than expected, while the musculocutaneous seems to be thicker. Then, the musculocutaneous nerve and median nerve fuse to form the common trunk in the mid-arm, which we call the median-musculocutaneous trunk.

We identified four nerves that sequentially supplied the coracobrachialis muscle. The first nerve is from the lateral cord and musculocutaneous nerve, the second and third nerves are from musculocutaneous nerve, while the fourth nerve to the coracobrachialis from the median-musculocutaneous trunk.

Distally, the median-musculocutaneous trunk forms the "ansa brachii" with the superior and inferior looping branches. The superior looping branch gives an anastomotic branch that connects the two looping branches and continues as the nerve to the biceps muscle. The anastomotic branch of the superior looping branch joins the inferior looping branch to form the two terminal branches of the musculocutaneous nerves; the nerve to the brachialis muscle and the lateral cutaneous nerve of the forearm (Figures 1 and 2).

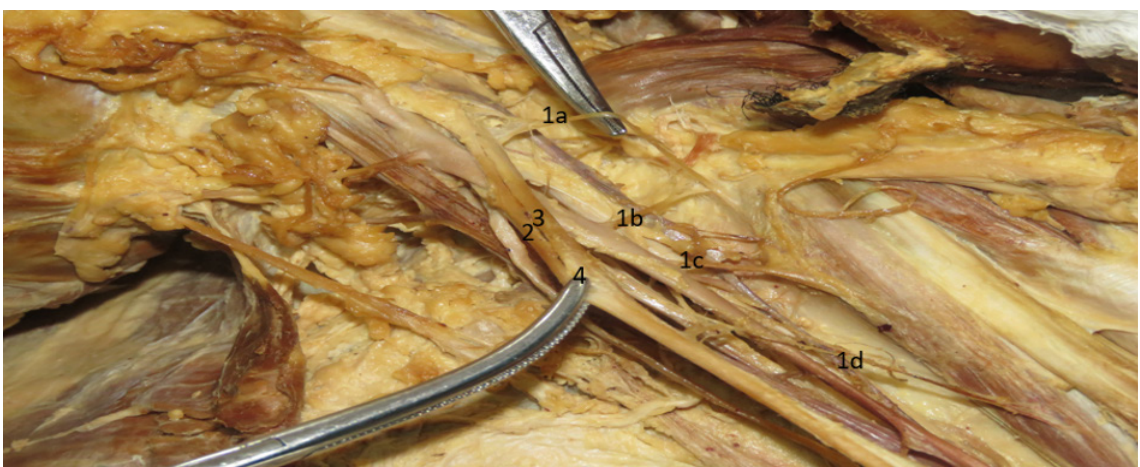
These findings have significant clinical implications anytime local or regional anesthesia in the arm or forearm is necessary, as it would necessitate anesthetic administration at a higher level

to anesthetize the arm. Anytime there is a musculocutaneous median trunk injury, the motor functions of the flexors in the arm and forearm, as well as the sensations at the elbow and lateral forearm, will undoubtedly be complicated. To prevent any harm to the patients because of their anatomy, the surgical techniques for the arm must take into account the neurovascular architectures and their anatomical variance.

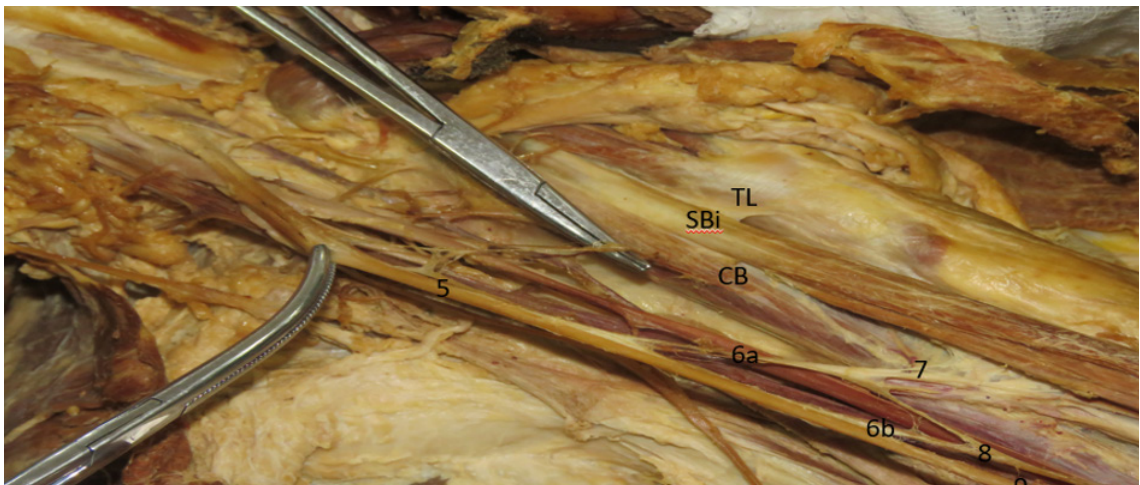
## DISCUSSION

The brachial plexus is prone to anatomical variations, which make up 50% of all nervous system anatomical variants [1,14]. Based on the variation, the brachial plexus may be pre-fixed due to contributions from C4 or post-fixed due to contributions from T2 [15]. Additional variants have been observed in peripheral branches, where the median nerve has received branches from the lateral, medial, or posterior cord, and the musculocutaneous nerve has given a branch to the median nerve [1].

Communication between musculocutaneous and median nerves may be a result of failed nerve segregation during embryological development [16]. Variations between the musculocutaneous nerve and median nerve are usually common, and the most commonly used classifications are the ones proposed by Le Minor [17] and Venieratos and Anagnostopoulou [18]. Communication



**Figure 1: (a) Nerve to coracobrachialis muscle from lateral cord and musculocutaneous nerve, (b) Nerve to coracobrachialis muscle from musculocutaneous nerve, (c) Nerve to coracobrachialis muscle from musculocutaneous nerve, (d) Nerve to coracobrachialis muscle from musculocutaneous nerve and median-musculocutaneous trunk, (2) Median nerve, (3) Musculocutaneous nerve, (4) Median-Musculocutaneous trunk.**



**Figure 2: (5) Median-Musculocutaneous trunk, (6a, 6b) Superior and inferior musculocutaneous “ansa brachii” branches, (7) Superior looping branch gives the nerve to biceps brachii muscle; (8) union of the anastomotic branch of the superior looping and inferior looping branch forms the nerve of brachialis muscle and lateral cutaneous nerve of the forearm, (9) Median nerve from the trunk, (CB) Coracobrachialis muscle, (SBi) Short head of biceps brachii muscle, (TL) Transverse ligament forming the bicipital (inter-tuberosity) canal for the tendon of the long head of biceps brachii.**

between musculocutaneous and median nerves has been grouped into five based on Le Minor's classification of the course of the nerves. Type I: classic description of what is obtainable in textbooks, without anastomoses between the musculocutaneous nerve and median nerve with the former passing through the coracobrachialis muscle; type II: fibers link both nerves in the distal section of the arm; type III: lateral root of the median nerve is merged with the musculocutaneous nerve; type IV: all fibers of the musculocutaneous nerve are merged with the lateral root of the median nerve, they follow the median nerve for some distance and then separate from it as a lateral branch; type V: the musculocutaneous nerve is absent and branches are located in the upper arm [17]. The only variation that shows similarity to Le Minor classification in our finding is type II; however, in this case, report the anastomosis was located at the midpoint of the arm, which subsequently formed superior and inferior looping branches from the median-musculocutaneous forming the ansa brachii that gives the nerve to biceps brachii, the nerve to brachialis muscle and the lateral cutaneous nerve of the forearm with four nerves supplying the coracobrachialis.

On the other hand, Venieratos and Anagnostopoulou classified the communication between the musculocutaneous nerve and median nerve into three about the coracobrachialis muscle

[18]. In Type I, there is proximal communication before entering the coracobrachialis muscle; in Type II, the communication is distal to the muscle; and in Type III, neither the nerve nor its communicating branch pierces the muscle [18]. Therefore, according to this classification, our present case is similar to type I because there was communication between the nerves before it entered the coracobrachialis muscle.

The musculocutaneous nerve giving a branch to the median nerve was also observed in the upper arm just below the musculocutaneous nerve where it enters the coracobrachialis muscle, so the communication can also be found or seen before the musculocutaneous nerve where it penetrates the Coracobrachialis muscle [19]. In their work on fetal cadaver dissection, the incidence of musculocutaneous nerve and median nerve communication was observed to be 25%, and mostly a branch that develops from the musculocutaneous nerve toward the median nerve [20].

The brachial plexus has several anatomical architectures. This is especially true about the development of the median nerve and musculocutaneous nerves. There may occasionally be a partial or full union of the median and musculocutaneous nerves [21]. Median nerve roots may grow longer and eventually unite into a



single trunk inside the arm, external to the axillary cavity. Moreover, abnormal connections could arise between the median and musculocutaneous nerves [22]. Furthermore, the existence of anatomically varied neurovascular structures may be seen and should be taken into account during anesthesia administration and surgical procedures [23].

Our finding of this brachial plexus variation is a potent reminder about possible numerous anatomical variations that have not been identified yet. The dissection course done by medical students, surgical trainees, and anatomists may continue to show different variations for great future anatomical and clinical development. Reports on various anatomical variances increase our understanding, help us get over the subjectivity of individual researchers' descriptions, and can be helpful to clinicians in their day-to-day work [24].

## CONCLUSION

The brachial plexus has different anatomical variations, and its occurrence is not rare. These variations may have a significant clinical impact on anesthesia administration and surgery. Given the formation of the ansa brachii and the pattern of the left arm's nerve supply in our case, it is important to use wide local anesthesia with no tourniquet (WALANT) under ultrasound guidance if surgery is required to prevent unnecessary hazards. Different anatomical variations of the brachial plexus described in different literature are also a reality in the Rwandan population. Further research about brachial plexus anatomical variations is paramount in our settings so that the current anesthesia and surgery techniques involving the upper limbs may be adjusted to the anatomy of the Rwandan population. During the clinical activities of the upper limbs, surgeons, and anesthesiologists should have in the back of their mind the likelihood of anatomical variations to avoid possible hazards.

## REFERENCES

1. Emamhadi, M.; Chabok, S.Y.; Samini, F.; Alijani, B.; Behzadnia, H.; Firozabadi, F.A.; Reihanian, Z. Anatomical Variations of Brachial Plexus in Adult Cadavers; a Descriptive Study. *Arch. Bone Jt. Surg.* 2016, 4, 253–258.
2. Butz, J.J.; Shiwlochan, D.G.; Brown, K.C.; Prasad, A.M.; Murlimanju, B. V.; Viswanath, S. Bilateral Variations of Brachial Plexus Involving the Median Nerve and Lateral Cord: An Anatomical Case Study with Clinical Implications. *Australas. Med. J.* 2014, 7, 227–231, doi:10.4066/amj.2014.2070.
3. Parchand, M.P.; Patil, S.T. Absence of Musculocutaneous Nerve with Variations in Course and Distribution of the Median Nerve. *Anat. Sci. Int.* 2013, 88, 58–60, doi:10.1007/s12565-011-0126-6.
4. Aydin, M.E.; Kale, A.; Edizer, M.; Kopuz, C.; Demir, M.T.; Çorumlu, U. Absence of the Musculocutaneous Nerve Together with Unusual Innervation of the Median Nerve. *Folia Morphol.* 2006, 65, 228–231.
5. Soleymanha, M.; Mobayen, M.; Asadi, K.; Adeli, A.; Haghparast-Ghadim-Limudahi, Z. Survey of 2582 Cases of Acute Orthopedic Trauma. *Trauma Mon.* 2014, 19, 20–23, doi:10.5812/traumamon.16215.
6. Budhiraja, V.; Rastogi, R.; Asthana, A.K. Variations in the Formation of the Median Nerve and Its Clinical Correlation. *Folia Morphol. (Warsz.)* 2012, 71, 28–30, doi:10.2139/ssrn.4325366.
7. Uysal, I.I.; Şeker, M.; Karabulut, A.K.; Büyükmumcu, M.; Ziylan, T.; Kline, D.G.; Klot, M.; Huang, J.H.; Zager, E.L. Brachial Plexus Variations in Human Fetuses. *Neurosurgery* 2003, 53, 676–684, doi:10.1227/01.NEU.0000079485.24016.70.
8. Abrahams, M.S.; Panzer, O.; Atchabahian, A.; Horn, J.L.; Brown, A.R. Case Report: Limitation of Local Anesthetic Spread During Ultrasound-Guided Interscalene Block. Description of an Anatomic Variant With Clinical Correlation. *Reg. Anesth. Pain Med.* 2008, 33, 357–359, doi:10.1016/j.rapm.2008.01.015.
9. Leinberry, C.F.; Wehbe, M.A. Brachial Plexus Anatomy. 2004, 20, 1–5, doi:10.1016/S0749-0712(03)00088-X.
10. Desai, N.; Russon, K. Anatomical Variation of the Brachial Plexus and Its Clinical Implications. 2016, 1–9.
11. Neal, J.M.; Gerancher, J.C.; Hebl, P.J.R.; Ilfeld, B.M.; McCartney, C.J.L.; Franco, C.D.; Hogan, Q.H. Essentials of Our Current Understanding, 2008. 2009, 34, 134–170, doi:10.1097/AAP.0b013e31819624eb.
12. Mian, A.; Chaudhry, I.; Huang, R.; Rizk, E.; Tubbs, R.S.; Loukas, M. Brachial Plexus Anesthesia: A Review of the Relevant Anatomy, Complications, and Anatomical Variations. *Clin. Anat.* 2014, 27, 210–221, doi:10.1002/ca.22254.
13. Remerand, F.; Laulan, J.; Palud, M.; Baud, A.; Velut, S.; Fuscuardi, J. Is the Musculocutaneous Nerve Really in the Coracobrachialis Muscle When

- Performing an Axillary Block? An Ultrasound Study. 2010, 110, 1729–1734, doi:10.1213/ANE.0b013e3181dc25c8.
14. Orebaugh, S.L.; Williams, B.A. Brachial Plexus Anatomy: Normal and Variant. *ScientificWorldJournal* 2009, 9, 300–312, doi:10.1100/tsw.2009.39.
15. Kubwimana, O.; Ndata, A.; Ivang, A.; Ndahimana, P.; Nzayisenga, A.; Byiringiro, J.C.; Gashegu, J. Musculocutaneous and Median Nerve Branching: Anatomical Variations. Case Series from UR Clinical Anatomy and Literature Review. *Afr. Health Sci.* 2022, 22, 263–268, doi:10.4314/ahs.v22i1.33.
16. Barone, R.; Amico, A.G.D.; Lorenzo, N. Di; Laura, G.; Grado, D.; Matranga, E.; Bucchieri, F.; Cappello, F.; Piotrowska, W.; Spodnik, J.H. Anastomosis between Median and Musculocutaneous Nerve: Presentation of an Anastomosis between Median and Musculocutaneous Nerve: Presentation of a Very Rare Anatomical Variation in Comparison to Classical Divisions. 2022, doi:10.3390/anatomia1010007.
17. Le Minor, J.M. [A rare variation of the median and musculocutaneous nerves in man]. *Arch. Anat. Histol. Embryol. Norm. Exp.* 1990, 73, 33–42.
18. Venieratos, D.; Anagnostopoulou, S. Classification of Communications between the Musculocutaneous and Median Nerves. *Clin. Anat.* 1998, 11, 327–331, doi:10.1002/(SICI)1098-2353(1998)11:5<327::AID-CA6>3.0.CO;2-M.
19. Ballesteros, L.E.; Forero, P.L.; Buitrago, E.R. Communication between the Musculocutaneous and Median Nerves in the Arm: An Anatomical Study and Clinical Implications. *Rev. Bras. Ortop. Engl. Ed.* 2015, 50, 567–572, doi:10.1016/j.rboe.2014.08.009.
20. Caetano, E.B.; Vieira, L. ângelo; Cavalheiro, C.S.; Filho, M.R.; Almargo, M.A.P.; Caetano, M.F. Anatomic Study of the Nervous Communication between the Median and Musculocutaneous Nerve. *Acta Ortop. Bras.* 2016, 24, 200–203, doi:10.1590/1413-785220162404159372.
21. Clarke, E.; Tubbs, R.S.; Radek, M.; Haładaj, R.; Tomaszewski, M.; Wysiadecki, G. Unusual Formation of the Musculocutaneous and Median Nerves: A Case Report Refined by Intraneural Dissection and Literature Review. *Folia Morphol. (Warsz.)* 2021, 80, 1020–1026, doi:10.5603/FM.A2020.0121.
22. Haładaj, R.; Wysiadecki, G.; Polguy, M.; Topol, M. Hypoplastic Superficial Brachioradial Artery Coexisting with Atypical Formation of the Median and Musculocutaneous Nerves: A Rare Combination of Unusual Topographical Relationships. *Surg. Radiol. Anat.* 2019, 41, 441–446, doi:10.1007/s00276-019-02183-1.
23. Clarke, E.; Wysiadecki, G.; Haładaj, R.; Skrzat, J. Fusion between the Median and Musculocutaneous Nerve: A Case Study. *Folia Med. Cracov.* 2019, 59, 45–52, doi:10.24425/fmc.2019.131135.
24. Żytkowski, A.; Tubbs, R.S.; Iwanaga, J.; Clarke, E.; Polguy, M.; Wysiadecki, G. Anatomical Normality, and Variability: Historical Perspective and Methodological Considerations. *Transl. Res. Anat.* 2021, 23, doi:10.1016/j.tria.2020.100105.