

## Sciatic nerve loop engulfing perforator arteries - a case report

**Authors:** O. Kubwimana<sup>1,2,\*</sup>; J. Rugambwa<sup>1,2</sup>; J. Gashegu<sup>1</sup>

**Affiliations:** <sup>1</sup>University of Rwanda, Department of Human Anatomy; <sup>2</sup>University Teaching Hospital of Butare (CHUB), Department of Surgery

### ABSTRACT

The sciatic nerve is the thickest in the human body; however, it is susceptible to a wide range of anatomical variations with potential clinical implications. Some variations are very rare and unreported in the existing literature

We present a case of a middle-aged male cadaver with a sciatic nerve giving a loop where 3 perforator arteries from the profunda femoris artery pass; the loop bundles were reforming the main nerve distally.

A sciatic nerve loop engulfing muscular perforator arteries is a scarce anatomical variation worth knowing for clinical, academic, and research interests.

**Keywords:** Sciatic Nerve, Arteries, Dissection, Cadaver

### INTRODUCTION

The sciatic nerve is a branch of the lumbosacral plexus and the biggest peripheral nerve in the human body [1–3]. It originates from the anterior rami from L4 to S3 and supplies muscles and underlying skin of the posterior compartment of the lower extremity [1]. Variations in Sciatic nerve length have been documented from 2.5 cm up to 39 cm. This was proved in a cadaveric study by Prameela et al. [4]. Some authors like Dupont et al. have reported the sciatic nerve to be made by 2 nerves covered by a single epineurium [5].

A lot has been documented on anatomical variations of the sciatic nerve in relation to the piriformis muscles, and up to the current, six variants are documented [1,2]. Some authors believe the presence of a variation in piriformis muscle–sciatic nerve variation at 23% [6]. Another documented variation is the high division of the sciatic nerve, which can happen anywhere along

the posterior compartment [2,7]. Arterial vessels crossing through the nerve is such a rare finding. An ultrasound-based case report by Tuhin et al. reported an aberrant artery originating to the popliteal artery and passing between the tibia and common peroneal nerve [8]. Another reported variation was a remnant of the ischiatic artery piercing the sciatic artery at the mid-thigh to supply the hamstring muscles [3]. The sciatic nerve, as a nerve with a long course, is susceptible to variations and injuries. Surgeons should be aware of common variations in their daily activities [9]. Currently, there is an increase in documented sciatic nerve variations, which are upper, mid-thigh, and lower variations. Therefore, Barbosa et al. have recommended including this pattern in medical semiology to raise awareness among all physicians [10].

However, to the present, there is a lack of data reporting the sciatic nerve being perforated by perforator arteries, such as the one we are

**\*Corresponding author:** Dr KUBWIMANA Olivier, Email: oliviee3@gmail.com, University of Rwanda, Department of Human Anatomy; **Funding:** This study was conducted as a part of the second anatomy annual congress in Rwanda, October 15, 2023 sponsored by the UR, Operation Smile, and MMI; **Academic Integrity.** All authors confirm that they have made substantial academic contributions to this manuscript as defined by the ICMJE; **Originality:** All authors: this manuscript is original has not been published elsewhere; **Review:** This manuscript was peer-reviewed by two reviewers of the S-CAR committee

**Received:** 24<sup>th</sup> October 2023; **Accepted:** 17<sup>th</sup> February 2024.

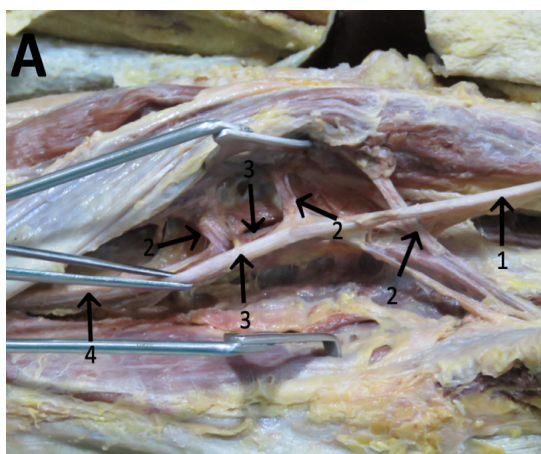
**Copyright:** © The Author(s). This is an Open Access article distributed under the terms of the Creative Commons Attribution License (CC BY-NC-ND) ([click here](#)) which permits unrestricted use, distribution, and reproduction in any medium, provided the original work is properly cited. **Publisher:** Rwanda Biomedical Centre (RBC)/Rwanda Health Communication Center, P. O. Box 4586, Kigali. ISSN: 2079-097X (print); 2410-8626 (online)

**Citation for this article:** O. Kubwimana; J. Rugambwa; J. Gashegu. Sciatic nerve loop engulfing perforator arteries: a case report. Rwanda Medical Journal, Vol. 81, no. 1, p. 137-139, 2024. <https://dx.doi.org/10.4314/rmj.v81i1.15>

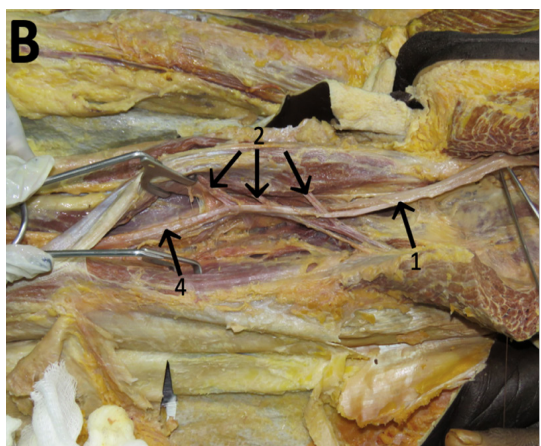reporting here. Therefore, this serves to raise awareness of its existence for academic and clinical benefits.

## CASE PRESENTATION

In the usual dissection course for surgical trainees, which took place in the Anatomy Laboratory, a middle-aged male cadaver was positioned in the prone position on the dissection table. The stratigraphic dissection was done from the buttocks area toward the posterior thigh, then the popliteal fossa on the posterior thigh. After identifying the superficial structures, the hamstring muscles were raised and separated.



**Figure 1A: (1) Proximal sciatic nerve (2) Three perforator arteries from profunda femoris, (3) Two bundles of sciatic nerve loop, (4) Distal sciatic nerve**



**Figure 1B: (1) Proximal sciatic nerve (2) Three perforator arteries from profunda femoris, (4) Distal sciatic nerve**

The sciatic nerve course was observed from the infra-piriformis towards the distal; however, in the proximal mid-thigh, we found a sciatic nerve loop allowing passage to 3 muscular perforator arteries, and it rejoined the main sciatic nerve distally; there was no kinking or compression effect on the perforators as the loop was large.

The perforator arteries were originating on the profunda femoris artery as normal, and the supplied muscles were the same size as the contralateral muscles. Figures 1 and 2 below are showing labeled findings in the cadaver.

## DISCUSSION

Undoubtedly, the sciatic nerve is the greatest nerve in the human body. The present case presented uniqueness, as the sciatic nerve gave a loop that allowed passage of perforator arteries normally arising from the profunda femoris artery, which was not previously reported. The given loop macroscopically appears as a nerve branch. However, no microscopic analysis was done to confirm whether it contains nerve fibers as it could be part of connective tissues as well, even though the case remains very rare.

The current medical literature contains some case reports that present some similarities with ours, such as a case done by Nayak et al. where the sciatic nerve was perforated by the ischiatic artery or sciatic artery, which has persisted. This is a branch of the internal iliac artery and is often present in early embryological phases; then, it gets obliterated later. In this published case, it has remained and perforated the mid-sciatic nerve [3]. It is not fully similar to ours since the artery is a single and ischiatic artery, not a perforator.

There is current evidence supporting cadaveric study as the best reliable way to study sciatic nerve anatomical variations and liaise with surgeons, neurologists, and anesthesiologists dealing with this nerve along its course in their daily practice [9]. The presence of 2 mm diameter intraneural arteries in the sciatic nerve is not so rare, as described by Larkman et al. It is currently hypothesized as a possible cause of sciatica when other causes are excluded. Practicing surgeons should be aware of this variation[11]. Mastering the existing anatomical variants of the sciatic nerve is paramount for practicing surgeons to prevent possible occupation hazards [5]. The authors' thoughts are that

the present case may have potential clinical implications. In case the perforator arteries get an aneurysm or pseudoaneurysm, the patient may present with sciatic nerve compression-related clinical features, and this has been presented in other body parts where the artery lies in nerve proximity [12,13].

## CONCLUSION

Sciatic nerve anatomical variations are many, ranging from common to very rare variations such as this case. This was a male cadaver with a sciatic nerve giving a loop engulfing 3 perforator arteries from the profunda femoris artery. We reported it to raise awareness among surgeons, anesthesiologists, and other concerned medical personnel, as this variation can cause sciatica upon the perforator arteries aneurysm or pseudoaneurysm. Further research into this matter is recommended.

## REFERENCES

1. Giuffre, B.A.; Jeanmonod, R. Anatomy, Sciatic Nerve. StatPearls 2019.
2. Kanawati, A.J. Variations of the Sciatic Nerve Anatomy and Blood Supply in the Gluteal Region: A Review of the Literature. *ANZ J. Surg.* 2014, 84, 816–819, doi:10.1111/ans.12675.
3. Nayak, S.B.; George, B.M.; Mishra, S. A Sciatic Nerve with Three Roots and Its Perforation by the Enlarged Ischiadic Artery. *Anat. Sci. Int.* 2014, 89, 118–121, doi:10.1007/s12565-013-0198-6.
4. Prameela; Raj, R.; Saralaya, V. Variations in the Course and Branching Pattern of Sciatic Nerve in the Gluteal Region and Its Surgical Implications. *Res. J. Pharm. Biol. Chem. Sci.* 2016, 7, 40–47.
5. Dupont, G.; Unno, F.; Iwanaga, J.; Oskouian, R.J.; Tubbs, R.S. A Variant of the Sciatic Nerve and Its Clinical Implications. *Cureus* 2018, 10, 6–8, doi:10.7759/cureus.2874.
6. Huq, E.; Bailie, P. A Rare Bifurcation Pattern of the Sciatic Nerve. *Anat. J. Afr.* 2017, 6, 1011–1014, doi:10.4314/aja.v6i3.163500.
7. Vloka, J.D.; Hadžić, A.; April, E.; Thys, D.M. The Division of the Sciatic Nerve in the Popliteal Fossa: Anatomical Implications for Popliteal Nerve Blockade. *Anesth. Analg.* 2001, 92, 215–217, doi:10.1097/0000539-200101000-00041.
8. Mistry, T.; Keshri, V.; Sonawane, K.; Sekar, C. An Aberrant Vessel Crossing the Paraneural Sheath between the Two Divisions of the Sciatic Nerve. *J. Clin. Anesth.* 2021, 73, 110352, doi:10.1016/j.jclinane.2021.110352.
9. Berihu, B.A.; Debeb, Y.G. Anatomical Variation in Bifurcation and Trifurcations of Sciatic Nerve and Its Clinical Implications : In Selected University in Ethiopia. *BMC Res. Notes* 2015, 1–7, doi:10.1186/s13104-015-1626-6.
10. Beatriz, A.; Barbosa, M.; Viana, P.; Targino, V.A.; De, N.; Silva, A.; Costa, Y.; Silva, D.M.; Gomes, F.B.; Assis, T.D.O. Sciatic Nerve and Its Variations : Is It Possible to Associate Them with Piriformis Syndrome ? 2019, 646–653.
11. Larkman, N.; Lefebvre, G.; Jacques, T.; Demondion, X.; Cotten, A. Anatomical and MR Correlative Study of the Proximal Sciatic Nerve Vasculature. *Br J Radiol* 2017 2017.
12. Papadopoulos, S.M.; McGilliduddy, J.E.; Messina, L.M. Pseudoaneurysm of the Inferior Gluteal Artery Presenting as Sciatic Nerve Compression 1989, 926–928.
13. Geelen, J.A.G.; de Graaff, R.; Biemans, R.G.M.; Prevo, R.L.; Koch, P.W.A.A. Sciatic Nerve Compression by an Aneurysm of the Internal Iliac Artery. *Clin. Neurol. Neurosurg.* 1985, 87, 219–222, doi:10.1016/0303-8467(85)90011-3.