

Curcumin intervention in hippocampal atrophy of diet-induced Alzheimer-like deficits in insulin-resistant rats

Authors: A. A. Mohammed^{1,2,*}; O.B. Akinola²

Affiliations: ¹Department of Anatomy, School of Medicine and Pharmacy, College of Medicine and Health Sciences, University of Rwanda, Rwanda; ²Neuroendocrinology division, Department of Anatomy, Faculty of Basic Medical Sciences, College of Health Sciences, University of Ilorin, Ilorin, Nigeria

ABSTRACT

INTRODUCTION: The primary mechanism connecting Type 2 diabetes mellitus (T2DM) to the neurodegenerative deficits in brain regions such as the hippocampus is insulin resistance. Neurodegenerative deficits in the form of amyloid aggregation and Tau hyperphosphorylation, which are hallmarks of Alzheimer's disease, are documented for both conditions in scientific literature. A mouse model of insulin resistance was used to study this relationship, and curcumin, a flavonoid contained in the spice turmeric, was evaluated as a potential treatment because of its reported benefits in lowering hyperglycemia and hyperlipidemia in diabetes mellitus. Curcumin is a prime contender against these pervasive diseases due to its efficacy, accessibility, affordability, and safety.

METHODS: The study methodology included measuring fasting blood glucose levels, staining hippocampal sections for histomorphological examination, and ELISA to quantify hippocampal PI3K expression, AKT expression, and GSK3- β . Data were processed using one-way ANOVA and Turkey's post hoc test.

RESULTS: The findings demonstrated that oral curcumin effectively corrected hyperglycemia and reduced insulin resistance. The study further revealed that insulin resistance was related to hippocampal atrophy and related deficits in the assessed rat model. Curcumin ameliorated these changes, reduced the aggregation of A β in the hippocampus, and reversed impaired signaling of proteins PI3K, AKT, and GSK-3 β .

CONCLUSION: The study's findings imply that oral curcumin has potential therapeutic advantages against prevalent neuronal death linked to abnormalities mimicking Alzheimer's disease and insulin resistance. Hence, curcumin may benefit dementia patients who also have insulin resistance

Keywords: Curcumin, Insulin Resistance, Hippocampus, Metabolic Disorders, Western Diet, Alzheimer's Disease

INTRODUCTION

Unhealthy dietary habits and sedentary lifestyles contribute to obesity and metabolic disorders,

impacting lipid and glucose balance [1,2]. Excessive consumption of high-carbohydrate and fatty foods, coupled with insufficient physical activity, leads to unhealthy weight gain and metabolic imbalances

***Corresponding author:** Abdullahi A. Mohammed, Department of Human Anatomy, School of Medicine and Pharmacy, CMHS, University of Rwanda, Rwanda. Email: a.mohammed@ur.ac.rw Telephone: +250791703551; **Funding:** This study was conducted as a part of the second anatomy annual congress in Rwanda, October 15, 2023 sponsored by the UR, Operation Smile, and MMI; **Academic Integrity.** All authors confirm that they have made substantial academic contributions to this manuscript as defined by the ICMJE; **Originality:** All authors: this manuscript is original has not been published elsewhere; **Review:** This manuscript was peer-reviewed by two reviewers of the S-CAR committee

Received: 24th October 2023; **Accepted:** 17th February 2024.

Copyright: © The Author(s). This is an Open Access article distributed under the terms of the Creative Commons Attribution License (CC BY-NC-ND) ([click here](https://creativecommons.org/licenses/by-nc-nd/4.0/)) which permits unrestricted use, distribution, and reproduction in any medium, provided the original work is properly cited. **Publisher:** Rwanda Biomedical Centre (RBC)/Rwanda Health Communication Center, P. O. Box 4586, Kigali. ISSN: 2079-097X (print); 2410-8626 (online)

Citation for this article: A.A. Mohammed; O.B. Akinola. Curcumin intervention in hippocampal atrophy of diet-induced Alzheimer-like deficits in insulin-resistant rats. Rwanda Medical Journal, Vol. 81, no. 1, p. 103-113, 2024. <https://dx.doi.org/10.4314/rmj.v81i1.10>

[1]. High carbohydrate intake, particularly fructose, is consistently associated with obesity and related health conditions. However, the long-term effects of a fructose-rich diet on cognitive function due to induced insulin resistance remain underexplored. Therefore, it is crucial to investigate whether insulin resistance, a consequence of poor dietary habits, influences the progression of Alzheimer's disease pathology [1–3].

Keshk et al. conducted a study using rodent models fed a high-fat diet containing sucrose and fructose. The research aimed to assess how AD resulting from induced insulin resistance affected specific aspects, such as inflammation and synaptic plasticity, regardless of plaque formation and neurofibrillary tangle buildup. The findings may have implications for future preventive treatments and early detection methods for dementia patients [4].

Moreover, individuals with diabetes have a significantly higher risk, five to eight times greater, of developing Alzheimer's disease compared to those without diabetes [3]. This relationship underscores the importance of insulin regulation in brain function. Conditions like cardiovascular diseases, obesity, and diabetes, all indicative of insulin dysregulation, severely affect brain function [5]. Insulin plays a pivotal role in glucose metabolism control and influences synaptic plasticity, neuronal growth, ion transport in gated channels, neuronal excitatory interactions, and PI3K-AKT downstream signaling for neuronal survival [5,6].

The hippocampus, critical for long-term memory and declarative memory, is vital for cognitive function. It consists of distinct regions, including the dentate gyrus (DG) and the Cornu Ammonis (CA), further divided into CA1 to CA4 subfields. Damage or disruptions in the hippocampus lead to deficits in spatial learning, object recognition, and factual recall [7].

Curcumin, derived from turmeric, is a compound traditionally used for its anti-inflammatory and diabetes-curing properties. Experimental studies show promising results for curcumin in declining type 2 diabetes mellitus development, improving pancreatic β -cell function, preventing β -cell death, and reducing insulin resistance [8].

Notably, India, with high curcumin consumption through turmeric, has a low incidence of Alzheimer's disease [9]. Curcumin has demonstrated its potential in reducing oxidative damage, inflammation, amyloid accumulation,

synaptic marker loss, and stimulating amyloid deposit removal [10,11]. The compound also plays a role in improving cognitive function and insulin signaling in Alzheimer's disease through the suppression of amyloid oligomers and effects on tau protein phosphorylation and insulin receptor substrate degradation via the c-Jun N-terminal kinase (JNK) signaling pathway in hippocampal neurons. These findings suggest curcumin's potential as a therapeutic agent against cognitive decline in Alzheimer's disease [12,13].

In this study, researchers investigated curcumin's potential as an intervention for hyperglycemia, insulin resistance, β -amyloid accumulation, and its role in the PI3K/AKT signaling pathway, focusing on the hippocampus in a rodent model of insulin resistance. The research underscores curcumin's potential to lower blood sugar and fat levels, making it an affordable, safe, and accessible therapeutic candidate. This study's findings contribute to our understanding of dietary impacts on cognitive health and the potential for curcumin to address challenges associated with Alzheimer's disease and diabetes-related complications [3,5,12].

METHODS

This study was done in full compliance with standard guidelines for animal use in research as approved by The University of Ilorin Ethical Review Committee (UERC) with approval number (UERC/ASN/2016/654). Experimental rats were allowed to acclimatize in the animal holding facility for 14 days before the commencement of the experiments. We accommodated rats in plastic cages, exposed to 12 hours of light/dark cycle, and rat chow and water were freely available. The Streptozotocin and curcumin used for animal treatments, was bought from Sigma Aldrich (USA). Olive oil was sourced locally from Goya Ltd., and the High-fat diet feed of 17.5% lard, 17.5% beef tallow, and 40% full-fat soya was compounded locally, as adapted from research from [3,4]. The digital glucometer was utilized to measure the fasting blood glucose level. Enzyme-linked immunoabsorbent assay (ELISA) kits purchased from (eBioscience, USA) were used to measure insulin concentration in the hippocampus across the groups according to the manufacturer's instructions. The Glial Fibrillary Acidic Protein (GFAP) expression assessment was done using the Avidin-Biotin Complex (ABC) method, while the antibody used was a product of

Elabscience USA.

Animal treatment and tests conducted: A group of 36 male Wistar rats were divided randomly into six groups and subjected to various treatments. The control group was administered olive oil, while the curcumin group received 200mg/kg body weight of curcumin. Meanwhile, the diabetic group was given a combination of HFD, STZ thrice in doses of 40 mg/kg BW, whereas the protective group underwent HFD, three doses of STZ concurrently treated with curcumin for protection. Moreover, there were two other groups that underwent preventive treatment -- first pre-treatment with curcumin followed by an intake of HFD and three shots each time administered with STZ while secondly receiving HFD plus three treatments involving administration via injection to be followed by *Curcuma Longa* (curry root) extract for therapeutic purposes.

Fasting blood glucose was assessed via a glucometer; animals were euthanized with 10ml Ketamin prior to organ excision, and hippocampal sections were prepared for staining. The H&E staining method and the Cresyl fast violet stain technique were employed to analyze the samples collected in this study.

Congo red staining and immunohistochemical demonstration of Glia fibrillary acidic protein demonstration methods were also employed for histomorphological and histochemical evaluations. We used ELISA for quantifying the hippocampal levels of active forms of PI3K, AKT, and GSK3 β .

The data was assessed by making use of a one-way analysis of variance along with Turkey's post hoc examination. The significance level for the study was established as lower than 0.05 to indicate statistical significance.

RESULTS

A high-fat diet and Streptozotocin promote hyperglycemia and insulin resistance:

Experiments have shown that diets high in fat, as well as the diabetes-causing drug Streptozotocin, can cause fasting blood glucose levels to rise and lead to insulin resistance. Upon review of Table 1 data, it was found that both control group rats and those treated with curcumin had normal blood glucose levels. However, diabetic rats experienced a noteworthy increase in their blood glucose level. Further analysis indicated that when STZ, HFD, and

curcumin were given concurrently, hyperglycemia occurred; moreover, pre-treatment with curcumin before HFD and STZ administration did not produce the expected hypoglycaemic effect.

It should be noted that the therapeutic group of rats experienced a considerable decline in blood glucose levels compared to their diabetic counterparts. The curcumin intervention resulted in a significant decrease in the HOMA-IR (Homeostatic Model Assessment of Insulin Resistance) Index among these rats. The control group showed less insulin resistance than the diabetic rats, whereas there was an evident twofold increase seen in insulin resistance amongst those with diabetes. Upon administering curcumin to the therapeutic group, a significant reduction was observed in the insulin resistance index, resulting in a 7.20 ± 1.48 value ($p < 0.05$).

Table 1: Assessment of Fasting Blood Glucose and Insulin Resistance Using the HOMA-IR Method

Groups	FBG	HOMA-IR
Olive oil	82.17 \pm 5.27	5.33 \pm 0.24
CUR	82.33 \pm 3.33	5.85 \pm 0.27
HFD+STZ	225.30 \pm 45.59***	14.89 \pm 0.50***
STZ+CUR+HFD	200.80 \pm 31.76**	7.49 \pm 0.28
CUR+STZ+HFD	223.30 \pm 51.41***	8.64 \pm 0.43
STZ+HFD+CUR	154.0 \pm 50.86*	7.20 \pm 0.74

Hyperglycemia and insulin insensitivity promote hippocampal cytoarchitectural deficits and chromatolytic changes:

Microscopic examination of the hippocampal cytoarchitecture, along with the photomicrographs of Olive oil and curcumin-treated rats, revealed a distinct histoarchitectural appearance of the hippocampus, exhibiting accurate delineation and staining characteristics. Figure 1a displayed normal cellularity and staining intensity in the control and curcumin-treated rats, indicating the absence of any histopathological alterations. In contrast, the plate representing photomicrographs of STZ+HFD-treated rats exhibited poor histomorphological presentation, sparse cellular density, and distinctive histopathological features. However,

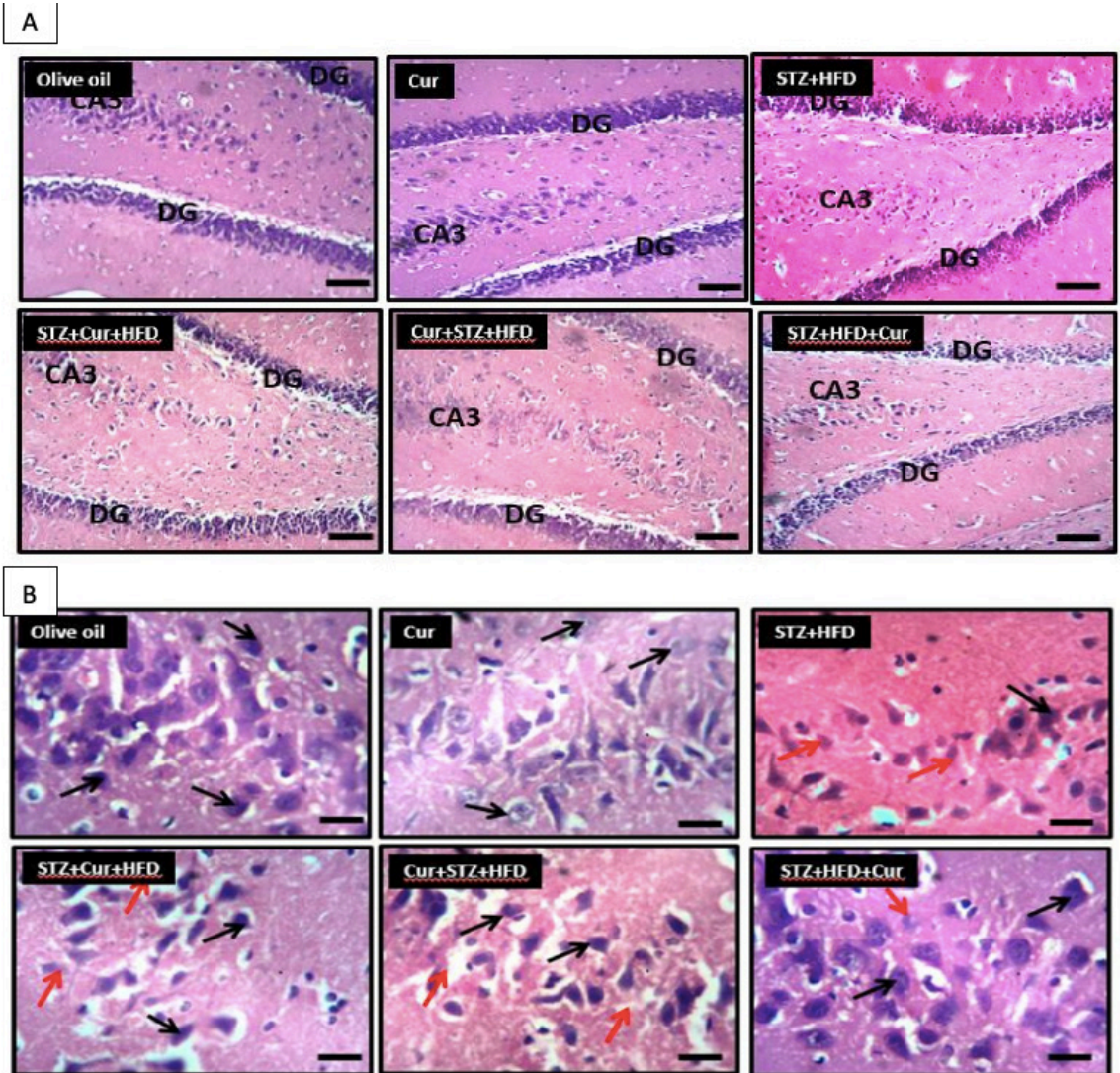


Figure 1: Histological photomicrograph (A) Hippocampal morphology of control, diabetic and curcumin treated rats, presentation of the dentate gyrus (DG) and (CA3) with characteristic staining morphology of the molecular layer of DG and pyramidal layer of CA3.

Scale bar: 100µm Stain: H&E (B) High-power magnification of the CA3 region with a focus on the pyramidal layer characterized by large soma with apical and basal dendrites. Notable findings observed are neuronal distortions, shrinkage of the nucleus, vacuolation, and pyknosis (as indicated by red arrows) within the diabetic group. Conversely, the cytoarchitecture of the hippocampus in both the control group and the group treated with curcumin revealed normal characteristics. H&E staining; scale bar = 25 µm

the photomicrographs representing STZ+Cur+HFD, Cur+STZ+HFD, and STZ+HFD+Cur treatments displayed histomorphology similar to that of Olive oil and curcumin-treated rats, characterized by normal cellular appearance, cell morphology, staining intensity, and hippocampal arrangement. Nevertheless, these treated groups showed reduced cellular density and the presence of halo-spaced neutrophils, particularly in the CA3 region,

as well as a few darkly stained nuclei.

Further examination at higher magnification of the CA3 region of the hippocampus, as depicted in Figure 1b, demonstrated that Olive oil and curcumin-treated rats exhibited intact pyramidal cells with standard cellularity and staining features without any noticeable histopathological alterations. Conversely, photomicrographs representing STZ+HFD and STZ+Cur+HFD treatments displayed

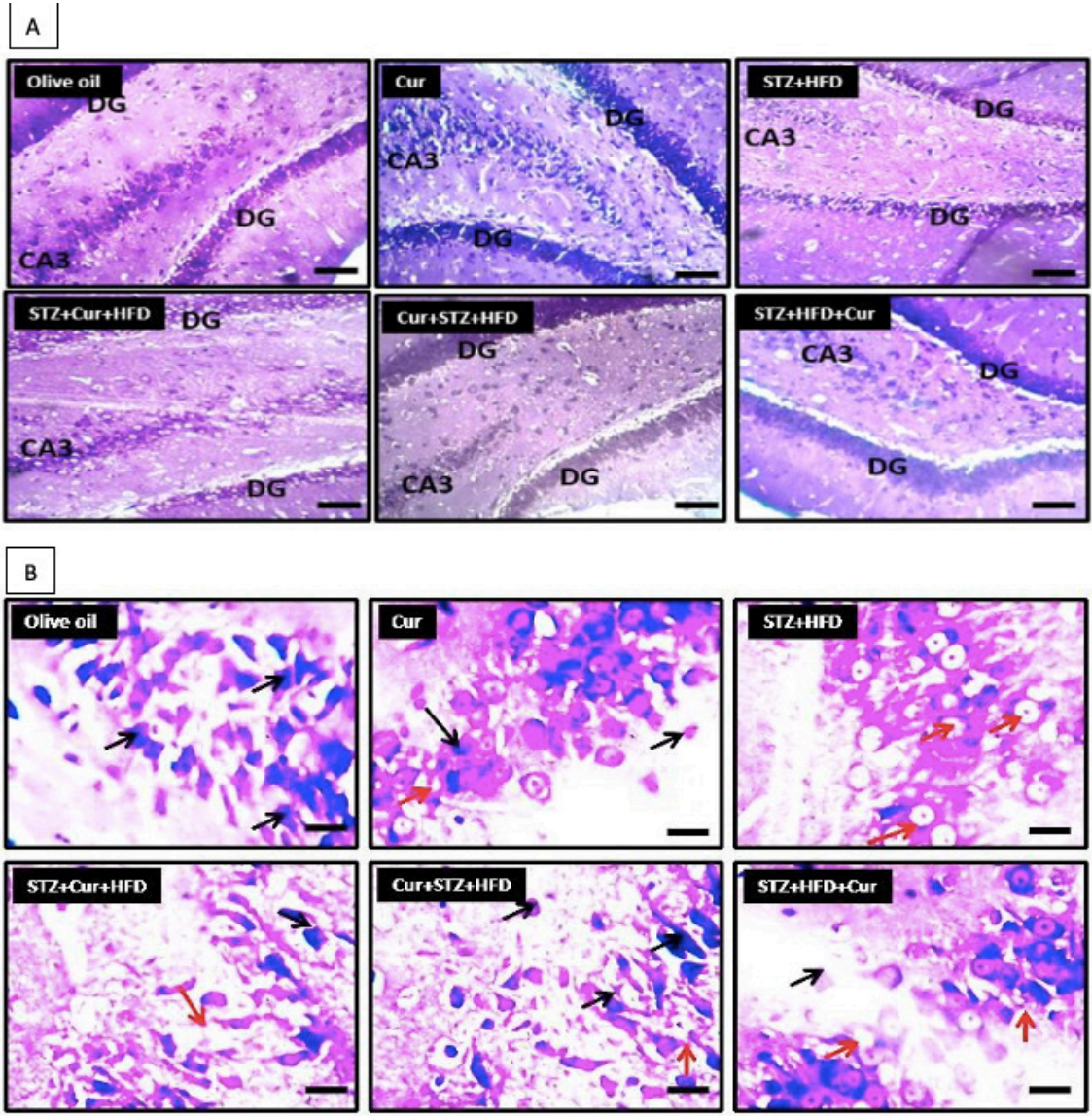


Figure 2: Histological examination (A&B) of amyloidogenesis in the groups after varied treatment regimen

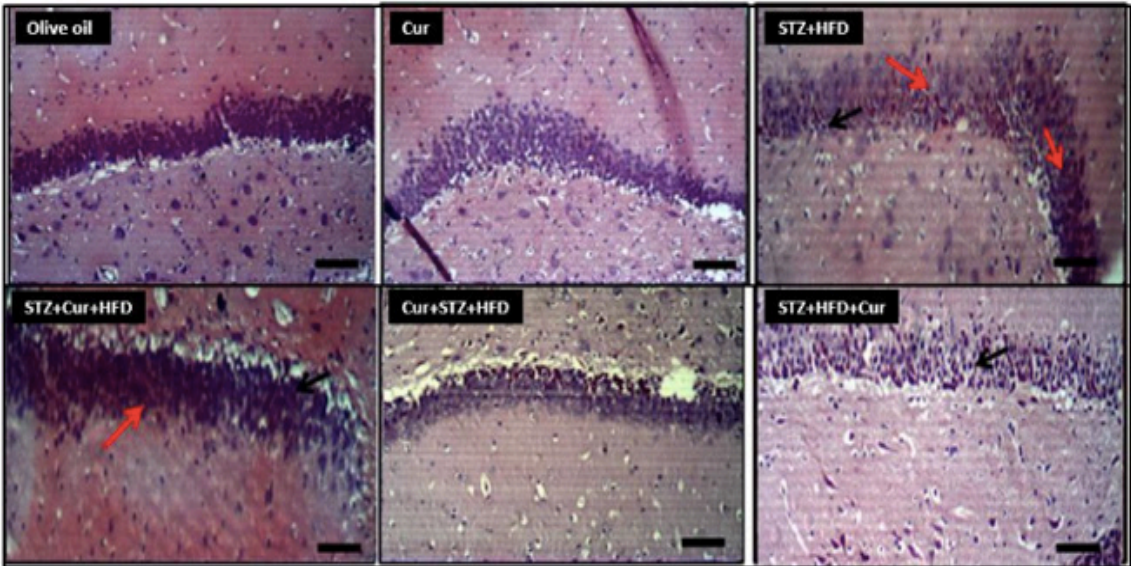
Investigation of the association between amyloid accumulation, dentate gyrus molecular cell layer integrity and insulin resistance. Normal molecular characteristics devoid of amyloid deposits were observed in both control and curcumin-treated rat groups at the hippocampal region. Conversely, diabetic/insulin-resistant rats showed localized areas of deposit formations (indicated by red arrows), indicating an apparent relationship between diabetes condition and amyloid deposition. Congo red staining; scale bar =50 μm. A more magnified image displayed in Figure 3B best revealed erosion of pyramidal cells' structure within the CA3 section among diabetic rodents comparable with well-defined ones seen amidst curcumin-treated and plain-control. Congo red stain, scale bar = 50 μm

shrunken pyramidal cells, indicated by large neutrophils (black arrow), as well as degenerative tendencies, evidenced by white halo spaces (red arrows). Representative photomicrographs for Cur+STZ+HFD and STZ+HFD+Cur treatments exhibited increased cellularity with improved staining intensity and more intact pyramidal cells,

resembling the cellular patterns observed in Olive oil and curcumin-treated rats.

As a consequence, the evaluation of cellular integrity in both non-diabetic rats treated with curcumin and control groups had an apparent impact on Nissl profiles' soundness seen in cornus ammonis Area 3 as well as dentate gyrus regions

A



B

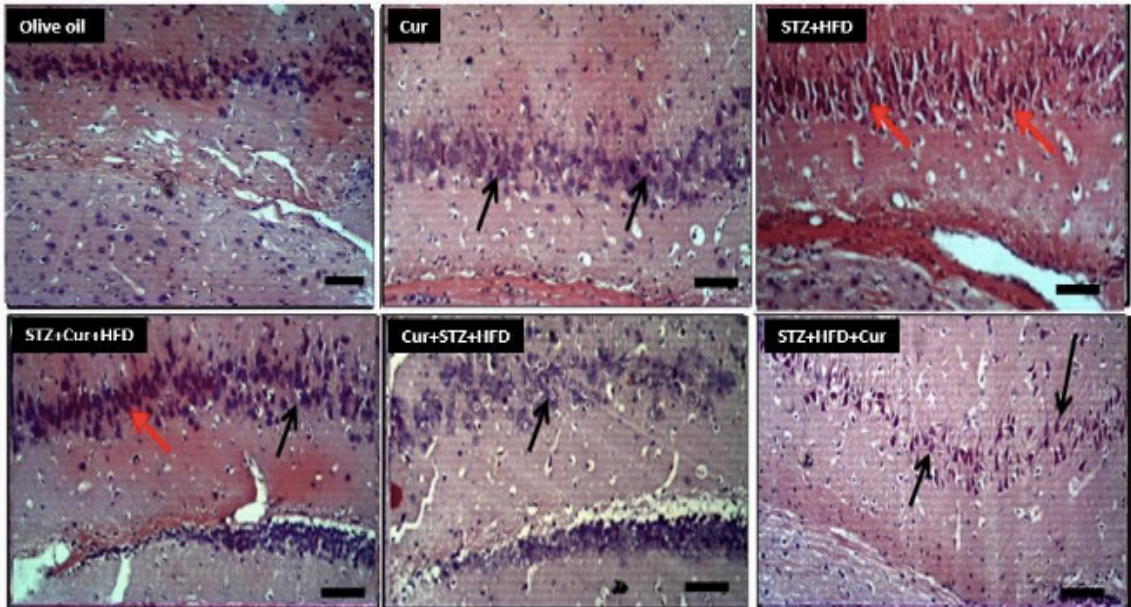


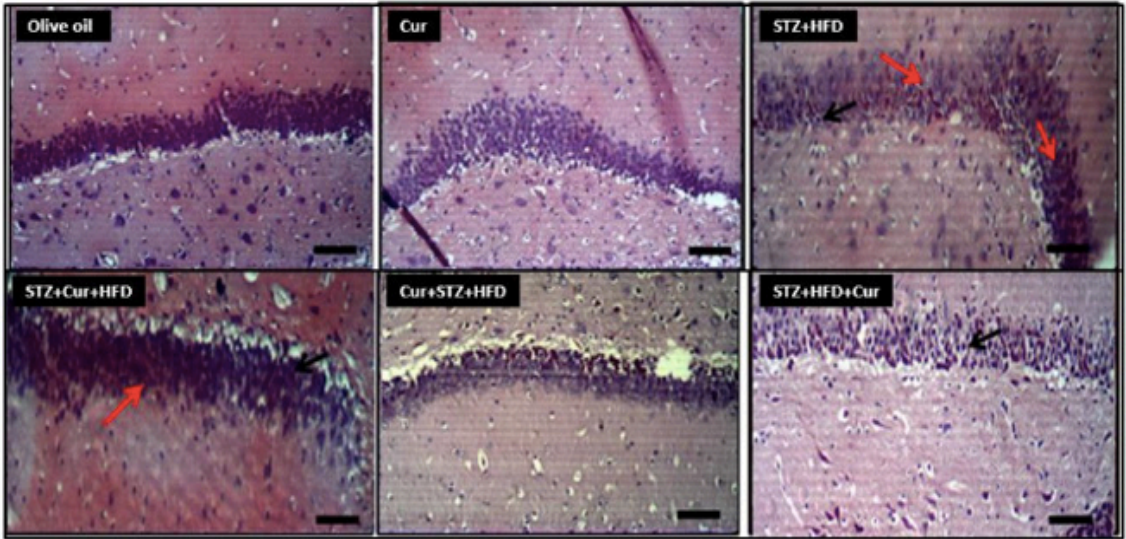
Figure 3: Histological examination (A&B) of amyloidogenesis in the groups after varied treatment regimen

Investigation of the association between amyloid accumulation, dentate gyrus molecular cell layer integrity and insulin resistance. Normal molecular characteristics devoid of amyloid deposits were observed in both control and curcumin-treated rat groups at the hippocampal region. Conversely, diabetic/insulin-resistant rats showed localized areas of deposit formations (indicated by red arrows), indicating an apparent relationship between diabetes condition and amyloid deposition. Congo red staining; scale bar =50 µm. A more magnified image displayed in Figure 3B best revealed erosion of pyramidal cells' structure within the CA3 section among diabetic rodents comparable with well-defined ones seen amidst curcumin-treated and plain-control. Congo red stain, scale bar = 50 µm

within the hippocampal tissue examined. Figure 2a illustrates the typical staining intensity and undamaged Nissl substances through sections from Olive oil-treated and curcumin-treated rat

samples in CA3 or DG. Contrastingly, portions extracted from STZ+HFD administered animal subjects showed reduced stained areas observed in both DG region along with CA3 area within

A



B

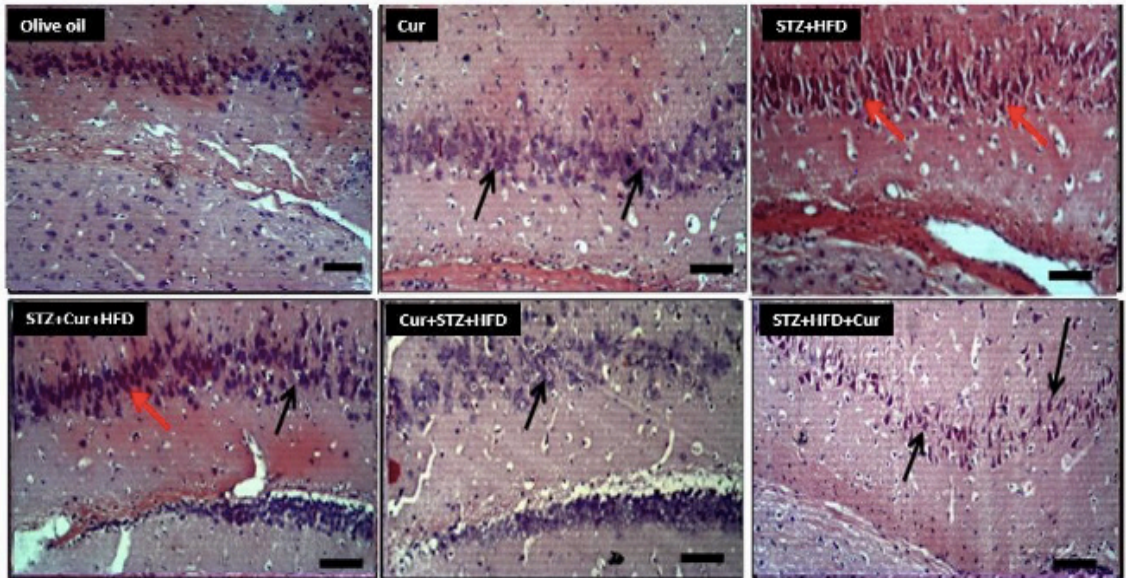


Figure 4: Immunohistochemical examination of (A&B) hippocampal astrocytic profile measured using GFAP

The dentate gyrus (DG) region, revealed an increase in GFAP positive cells in the diabetic/insulin-resistant group, compared to the control, curcumin-only, and therapeutic group rats. Furthermore, Figure 4B presents the astrocyte profile of the CA3 region in control, diabetic, and curcumin-treated rats. Remarkably, a greater number of activated astrocytes were observed in the diabetic group rats relative to the control and curcumin-treated groups. These findings indicate enhanced astrocyte reactivity in response to the diabetic condition. GFAP, Scale bar = 100 μm.

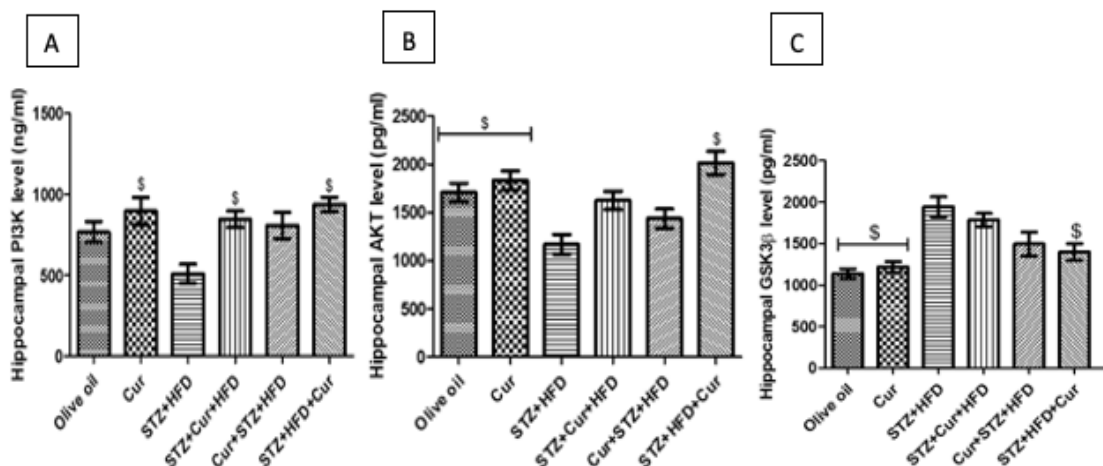


Figure 5: Quantification of Hippocampal PI3K (A), AKT (B), and GSK3 β (C) Activities in the Rat Model

The activities of PI3K, AKT, and GSK3 β were quantified in the hippocampus of the rat model. ELISA results demonstrated significant differences among the experimental groups. The control group and rats treated with curcumin exhibited increased levels of PI3K and AKT, while displaying decreased levels of GSK3 β compared to the rats treated with STZ+HFD. These findings suggest that both the control group and curcumin-treated rats exhibited enhanced PI3K and AKT activities, which are associated with the activation of the PI3K/AKT signaling pathway. Conversely, the STZ+HFD-treated rats displayed decreased GSK3 β activity, indicating altered signaling pathways in the diabetic condition. #compared to the Cur group. STZ=Streptozotocin, HFD=High Fat Diet, Cur=Curcumin, Data were mean \pm SEM ($p < 0.05$) $n=4$

the hippocampus exhibiting chromatolysis phenomena together with weakly tinted cells noticeably illustrated by pale visual appearance present at such section's DG area. Sections from diabetic animals after treatment using curcumin exhibited higher staining intensities across distinct segments of their hippocampus when compared to unmedicated diabetic rodent models that simply received STZ+HFD without any external intervention involving curcumin administration.

A closer examination at higher magnification of the CA3 hippocampal region, represented in Figure 2b, revealed the characteristic staining intensity of the pyramidal cells in the control group, while abundant chromatolytic pyramidal neurons and several poorly stained neurons (red arrows) were observed in the STZ+HFD administered rats. Sections from the STZ+Cur+HFD, Cur+STZ+HFD, and STZ+HFD+Cur treated rats displayed chromogenic distortions but exhibited better-staining intensities and suppressed chromatolysis compared to the STZ+HFD treated rats.

High glucose level promotes hippocampal neuronal amyloidogenesis and hippocampal astrogliosis: Investigating the presence of amyloid deposition in the CA3 region of the hippocampus among different experimental groups, as depicted

in Figure 3a, yielded interesting findings. Control rats treated with olive oil exhibited no amyloid deposition in the CA3 region. Similarly, curcumin-treated rats displayed comparable staining intensity and an absence of amyloid deposits, resembling the control group. Conversely, STZ+HFD-treated rats revealed numerous amyloid deposition spots (indicated by red arrows) in the CA3 region. Figure 3b demonstrated a reduction in amyloid deposition across the three curcumin intervention groups. While the STZ+Cur+HFD group, receiving concurrent curcumin intervention with STZ and HFD, exhibited a noticeable level of deposition, the groups receiving pre- and post-treatment curcumin displayed fewer deposits.

Furthermore, a closer examination of the hippocampal sections, presented in Figure 4b, provided insights into the histomorphometry of the CA3 region. Olive oil and curcumin-treated rats exhibited normal pyramidal neurons, indicative of normal histomorphometry, along with normal surrounding astrocytes. In contrast, STZ and high-fat treatment induced astrocytic hypertrophy, characterized by activated astrocytes observed in the sections. STZ+Cur+HFD and Cur+STZ+HFD treated rats displayed fewer activated astrocytes compared to the STZ+HFD group, with more visible pyramidal neurons. The STZ+HFD+Cur group

exhibited normal pyramidal cells with supporting astrocytes, devoid of any signs of astrocytic hypertrophy, astrocytic activation, or astrogliosis. Additionally, an evaluation of the astrocytic profile in the DG region, depicted in Figure 4a, revealed noteworthy observations. Olive oil and curcumin-treated rats exhibited characteristic normal granular neurons in the dentate gyrus, accompanied by normal supporting astrocytes. STZ+HFD-treated rats displayed fewer granular cells and prominent activated and reactive astrocytes. Rats receiving curcumin intervention concurrently as a pre- and post-treatment displayed normal granular neurons with fewer activated astrocytes compared to the STZ+HFD group.

Elevated glucose level impacts neuronal insulin signaling molecules: The impact of curcumin treatment on the downstream neuronal insulin signaling cascade is elucidated through Figures 5a, b, and c. The activities of key components, including Phosphatidylinositol-3-Kinase (PI3K), Protein Kinase B (AKT), and Glycogen Synthase Kinase-3- β (GSK3 β), were significantly influenced by the different treatments administered across the groups.

Figure 5a illustrates a notable decrease in PI3K activity in the untreated diabetic rats subjected to a high-fat diet (HFD) and Streptozotocin (STZ) alone. However, curcumin treatment successfully restored PI3K levels in the treated diabetic rats, reaching a comparable level to that observed in the control rats.

Moreover, the expression level of hippocampal Protein Kinase B (AKT) was augmented by curcumin, as depicted in Figure 5b. The untreated diabetic rats presented a marked reduction in AKT expression compared to both the control group and the curcumin-treated rats. This implies that curcumin treatment effectively upregulates AKT activation in diabetic rats.

Consequently, the activation of AKT exerts inhibitory effects and downregulates the expression level of hippocampal Glycogen Synthase Kinase-3- β (GSK3 β) in both the control group and the diabetic group treated with curcumin. This relationship is illustrated in Figure 5c, where the untreated diabetic group, characterized by a low level of AKT activation, displayed a marked increase in GSK3 β expression.

Overall, the findings demonstrate that curcumin treatment has a significant impact on the

downstream neuronal insulin signaling cascade, including the restoration of PI3K activity and the upregulation of AKT expression. These effects contribute to the inhibition of GSK3 β expression, highlighting the probable therapeutic potential of curcumin in moderating the insulin signaling pathway in the hippocampus.

DISCUSSION

The proper regulation of glucose metabolism and energy homeostasis is essential for an organism's overall health. Insulin and its signaling pathways play a key role in maintaining this balance. Disruptions in these pathways, as seen in conditions like type 2 diabetes and insulin resistance, have been associated with cognitive decline, a common feature of Alzheimer's disease (AD). AD is characterized by impaired cerebral glucose utilization and energy metabolism, contributing to the cognitive deficits observed in patients [1,2,13]. Our study aimed to investigate the potential of curcumin, a compound derived from turmeric, in regulating glucose metabolism and insulin resistance, and their potential impact on cognitive function. We used an experimental rat model to explore these aspects. Our findings indicate that curcumin effectively regulated blood glucose levels, with the most significant effect observed when curcumin intervention was administered after an insult. This suggests that curcumin's hypoglycemic properties may result from several mechanisms, including reducing hepatic glucose production, suppressing hyperglycemia-induced inflammation, enhancing glucose uptake, activating AMP kinase, and improving pancreatic cell functions [8,14,15]. These results align with previous studies that have reported curcumin's potential to address deficits in glucose energy metabolism and oxidative stress associated with cognitive impairment [1,12,15]. The observed reduction in glucose utilization, as seen in our study, is believed to be related to glycolytic pathway defects and mitochondrial respiration abnormalities, highlighting the need for further investigation into these aspects. Mitochondrial dysfunction is closely linked to glucose imbalance, oxidative stress, and cognitive decline, making it an important area of study [1]. Our study employed the HOMA-IR index to assess insulin resistance levels among different treatment groups. We found that rats receiving Streptozotocin and a high-fat diet displayed

significantly higher HOMA-IR indices, indicating disturbed metabolic homeostasis and decreased insulin action. Curcumin intervention, on the other hand, improved insulin sensitivity and restored proper insulin activity [8].

Our data strongly suggests that curcumin may play a role in activating downstream insulin signaling pathways due to its anti-hyperglycemic and insulin-regulating properties. Curcumin effectively ameliorated insulin resistance (IR) and metabolic abnormalities observed in obese diabetic rats. Future studies should focus on glucose transporter genes to gain a better understanding of the mechanisms underlying type 2 diabetes pathogenesis [1].

Additionally, our findings support previous research indicating that diets high in fructose and fat can lead to decreased insulin sensitivity and disruptions in glucose metabolic processes, ultimately resulting in systemic insulin resistance [1,4]. This underlines the importance of diet in maintaining metabolic health.

Microscopic examination of the hippocampus revealed significant differences in histomorphology among the treatment groups. Rats treated with olive oil and curcumin displayed a typical histo-architectural definition of the hippocampus, with normal neuronal cell layers and morphology. In contrast, rats exposed to a high-fat diet and Streptozotocin exhibited poor histomorphological presentation, characterized by neuronal degeneration and distorted neuronal morphology. Curcumin intervention reversed these deleterious effects observed in diabetic rats, further highlighting its potential in preserving and safeguarding neurons [2,16,17].

Inflammatory alterations, such as astrogliosis and microgliosis, are commonly observed in Alzheimer's disease. Our study showed that curcumin reduced the proliferation of reactive astrocytes in diabetic rats. Astrocytes play a vital role in protecting against central nervous system injury and tissue repair. Curcumin's reparative effects were evident in the reduction of astrocytic activation and the prevention of glial scars [12,18,19].

Moreover, our investigation explored the role of the PI3K-AKT pathway, a crucial signaling cascade associated with cell protection and glucose metabolism. Curcumin increased the expression of PI3K and phosphorylated AKT while reducing the expression of glycogen synthase kinase 3 beta (GSK3 β), a downstream target of AKT. These

results suggest that curcumin activates an anti-apoptotic pathway, promotes glucose regulation, and reduces hyperphosphorylation of tau proteins and beta-amyloid accumulation, contributing to healthier cellular processes, neuronal survival, and improved cognitive functions [6,11,15,17].

CONCLUSION

Our study provides compelling evidence of the potential therapeutic benefits of curcumin in addressing hyperglycemia, insulin resistance, and cognitive decline. Curcumin effectively regulated blood glucose levels, improved insulin sensitivity, and restored histological integrity in the hippocampus. These findings emphasize the role of curcumin as a multifaceted compound with anti-inflammatory, antioxidant, and insulin-regulating properties. While our study was conducted using an experimental animal model, it paves the way for further research into curcumin's potential as a therapeutic agent for diabetes and its complications, as well as its role in preserving cognitive function. These findings hold promise for developing interventions that may mitigate the impact of diabetes on brain health and cognitive decline, ultimately improving the quality of life for individuals with these conditions.

REFERENCES

1. Cheng, X.; Zheng, J.; Lin, A.; Xia, H.; Zhang, Z.; Gao, Q.; Lv, W.; Liu, H. A Review: Roles of Carbohydrates in Human Diseases through Regulation of Imbalanced Intestinal Microbiota. *J. Funct. Foods* 2020, 74, 104197, doi:10.1016/j.jff.2020.104197.
2. Terzo, S.; Amato, A.; Mulè, F. From Obesity to Alzheimer's Disease through Insulin Resistance. *J. Diabetes Complications* 2021, 35, 108026, doi:10.1016/j.jdiacomp.2021.108026.
3. Nuzzo, D.; Amato, A.; Picone, P.; Terzo, S.; Galizzi, G.; Bonina, F.P.; Mulè, F.; Di Carlo, M. A Natural Dietary Supplement with a Combination of Nutrients Prevents Neurodegeneration Induced by a High Fat Diet in Mice. *Nutrients* 2018, 10, 1130, doi:10.3390/nu10091130.
4. Keshk, W.A.; Ibrahim, M.A.; Shalaby, S.M.; Zalat, Z.A.; Elseady, W.S. Redox Status, Inflammation, Necroptosis and Inflammasome as Indispensable Contributors to High Fat Diet (HFD)-Induced Neurodegeneration; Effect of N-Acetylcysteine

- (NAC). *Arch. Biochem. Biophys.* 2020, 680, 108227, doi:10.1016/j.abb.2019.108227.
5. Tramutola, A.; Lanzillotta, C.; Di Domenico, F.; Head, E.; Butterfield, D.A.; Perluigi, M.; Barone, E. Brain Insulin Resistance Triggers Early Onset Alzheimer Disease in Down Syndrome. *Neurobiol. Dis.* 2020, 137, 104772, doi:10.1016/j.nbd.2020.104772.
 6. Maiti, P.; Dunbar, G.L. Use of Curcumin, a Natural Polyphenol for Targeting Molecular Pathways in Treating Age-Related Neurodegenerative Diseases. *Int. J. Mol. Sci.* 2018, 19, 1637, doi:10.3390/ijms19061637.
 7. Knierim, J.J. The Hippocampus. *Curr. Biol.* 2015, 25, R1116–R1121, doi:10.1016/j.cub.2015.10.049.
 8. Abrahams, S.; Haylett, W.L.; Johnson, G.; Carr, J.A.; Bardien, S. Antioxidant Effects of Curcumin in Models of Neurodegeneration, Aging, Oxidative and Nitrosative Stress: A Review. *Neuroscience* 2019, 406, 1–21, doi:10.1016/j.neuroscience.2019.02.020.
 9. Bhat, A.; Mahalakshmi, A.M.; Ray, B.; Tuladhar, S.; Hediya, T.A.; Manthiannem, E.; Padamati, J.; Chandra, R.; Chidambaram, S.B.; Sakharkar, M.K. Benefits of Curcumin in Brain Disorders. *BioFactors* 2019, 45, 666–689, doi:10.1002/biof.1533.
 10. Mandal, M.; Jaiswal, P.; Mishra, A. Role of Curcumin and Its Nanoformulations in Neurotherapeutics: A Comprehensive Review. *J. Biochem. Mol. Toxicol.* 2020, 34, e22478, doi:10.1002/jbt.22478.
 11. Benameur, T.; Giacomucci, G.; Panaro, M.A.; Ruggiero, M.; Trotta, T.; Monda, V.; Pizzolorusso, I.; Lofrumento, D.D.; Porro, C.; Messina, G. New Promising Therapeutic Avenues of Curcumin in Brain Diseases. *Molecules* 2022, 27, 236, doi:10.3390/molecules27010236.
 12. Amato, A.; Terzo, S.; Mulè, F. Natural Compounds as Beneficial Antioxidant Agents in Neurodegenerative Disorders: A Focus on Alzheimer's Disease. *Antioxidants* 2019, 8, 608, doi:10.3390/antiox8120608.
 13. Folch, J.; Olloquequi, J.; Ettcheto, M.; Busquets, O.; Sánchez-López, E.; Cano, A.; Espinosa-Jiménez, T.; García, M.L.; Beas-Zarate, C.; Casadesús, G.; et al. The Involvement of Peripheral and Brain Insulin Resistance in Late Onset Alzheimer's Dementia. *Front. Aging Neurosci.* 2019, 11.
 14. Athauda, D.; Foltynie, T. Insulin Resistance and Parkinson's Disease: A New Target for Disease Modification? *Prog. Neurobiol.* 2016, 145–146, 98–120, doi:10.1016/j.pneurobio.2016.10.001.
 15. Sripetchwandee, J.; Chattipakorn, N.; Chattipakorn, S.C. Links Between Obesity-Induced Brain Insulin Resistance, Brain Mitochondrial Dysfunction, and Dementia. *Front. Endocrinol.* 2018, 9.
 16. Sundaram, J.R.; Poore, C.P.; Sulaimi, N.H.B.; Pareek, T.; Cheong, W.F.; Wenk, M.R.; Pant, H.C.; Frautschy, S.A.; Low, C.-M.; Kesavapany, S. Curcumin Ameliorates Neuroinflammation, Neurodegeneration, and Memory Deficits in P25 Transgenic Mouse Model That Bears Hallmarks of Alzheimer's Disease. *J. Alzheimers Dis.* 2017, 60, 1429–1442, doi:10.3233/JAD-170093.
 17. Hoffman, J.D.; Yanckello, L.M.; Chlipala, G.; Hammond, T.C.; McCulloch, S.D.; Parikh, I.; Sun, S.; Morganti, J.M.; Green, S.J.; Lin, A.-L. Dietary Inulin Alters the Gut Microbiome, Enhances Systemic Metabolism and Reduces Neuroinflammation in an APOE4 Mouse Model. *PLOS ONE* 2019, 14, e0221828, doi:10.1371/journal.pone.0221828.
 18. Mohammadi, A.; Hosseinzadeh Colagar, A.; Khorshidian, A.; Amini, S.M. The Functional Roles of Curcumin on Astrocytes in Neurodegenerative Diseases. *Neuroimmunomodulation* 2021, 29, 4–14, doi:10.1159/000517901.
 19. Frost, G.R.; Li, Y.-M. The Role of Astrocytes in Amyloid Production and Alzheimer's Disease. *Open Biol.* 2017, 7, 170228, doi:10.1098/rsob.170228.