

## Anterior jugular vein variations in two cadavers and clinical implications: A case report

**Authors:** A. Omodan<sup>1\*</sup>; E. Sindikubwabo<sup>2</sup>; J. Gashegu<sup>1</sup>

**Affiliations:** <sup>1</sup>Department of Human Anatomy, College of Medicine and Health Sciences, University of Rwanda; <sup>2</sup>Department of Surgery, College of Medicine and Health Sciences, University of Rwanda

### ABSTRACT

**INTRODUCTION:** Anterior jugular veins are a paired structure found on either side of the neck and are responsible for other veins in draining the head and neck regions.

**CASE:** The variations reported here are from two male cadavers about 45 and 50 years of age who were being dissected routinely in the dissecting room. The first cadaver, which was the 50-year-old, had the normal formation of both anterior jugular veins (AVJ), but down in its course, the left and the AVJs join around the cricoid cartilage and continue down as a single vein running in the mid-line of the neck but ending by piercing deep to drain into the external jugular vein. The second cadaver was 45 years old. After forming the left AJV, the vein immediately crosses over to the right to run parallel to the right AJV before both joining to form a common vein and then piercing to drain in the external jugular vein (EJV).

**CONCLUSION:** The knowledge of these variations has become very important for all health workers dealing with the neck surgically, radiologically or otherwise.

**Keywords:** Jugular veins, cardiac catheterization, anatomic variations

### INTRODUCTION

The anterior jugular vein is made from tributaries of small submandibular veins that coalesce and runs down near the midline on both sides of the neck medial to the anterior border of the sternocleidomastoid muscle [1]. The paired veins are then connected to each other in their inferior path by the jugular venous arch before passing deep to the sternocleidomastoid muscle and draining into the external jugular vein [1]. The following case reports are a variant of this anatomy and the clinical implication of such variants.

### CASE PRESENTATION

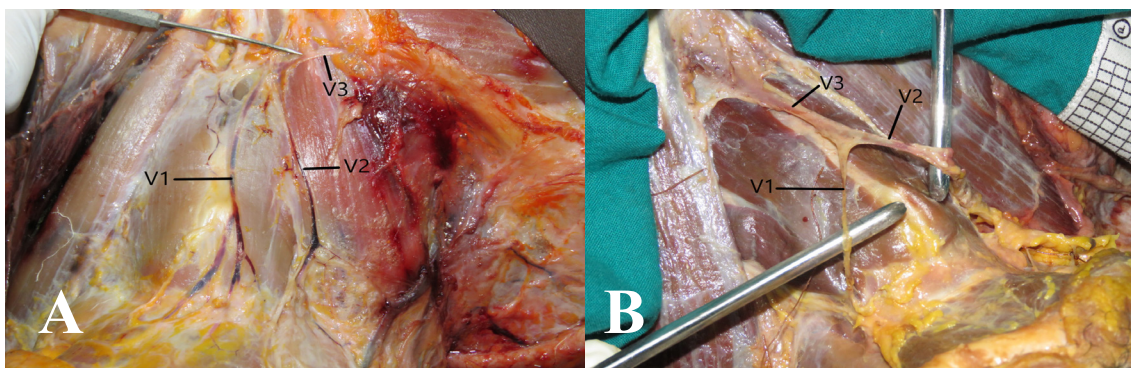
These variations were encountered during routine gross lab dissections in the Department of Human Anatomy of the University of Rwanda on two male cadavers of approximately 50 and 45 years of age. In the first cadaver, a 50-year-old male, the anterior jugular veins were formed from the collection of the submandibular veins. The left and the right anterior jugular veins (V1 and V2) ran down the neck just medial to the anterior borders of the sternocleidomastoid muscles but joined together in the midline at the level of the cricoid cartilage

**\*Corresponding author:** A. Omodan, asking4biola@yahoo.com; **Potential Conflicts of Interest (Col):** All authors: no potential conflicts of interest disclosed; **Funding:** This study was conducted as a part of the first anatomy annual congress in Rwanda, October 13-15, 2022 sponsored by the MoH, UR, UGHE, AUCA-ASOME, Operation Smile, CHUK and MMI; **Academic Integrity.** All authors confirm that they have made substantial academic contributions to this manuscript as defined by the ICMJE; **Originality:** All authors: this manuscript is original has not been published elsewhere; **Review:** This manuscript was peer-reviewed by two reviewers of the S-CAR committee

**Received:** 27<sup>th</sup> November 2022; **Accepted:** 18<sup>th</sup> February 2023.

**Copyright:** © The Author(s). This is an Open Access article distributed under the terms of the Creative Commons Attribution License (CC BY-NC-ND) ([click here](#)) which permits unrestricted use, distribution, and reproduction in any medium, provided the original work is properly cited. **Publisher:** Rwanda Biomedical Centre (RBC)/Rwanda Health Communication Center, P. O. Box 4586, Kigali. ISSN: 2079-097X (print); 2410-8626 (online)

**Citation for this article:** A. Omodan; E. Sindikubwabo; J. Gashegu. Anterior jugular vein variations in two cadavers and clinical implications – Case report. Rwanda Medical Journal, Vol. 80, no. 1, p. 84-86, 2023. <https://dx.doi.org/10.4314/rmj.v80i1.11>



**Figure 1:** The left anterior jugular vein (AJV) (V1) and the right AJV (V2) both meeting at the region of the cricoid cartilage and joining together to continue as a common vein (V3) before going to drain into the EJV (A). The left AJV (V1) after formation, crossing over to the right side of the neck to run parallel with the right AJV (V2) before joining to form a common vein (V3) and then piercing deep to drain into the EJV (B).

before continuing down the midline as a single vein (V3) (Figure 1A).

The continuation (V3) goes ahead to pierce underneath on its way to draining into the external jugular vein. In the second 45-year-old male cadaver, the anterior jugular veins are formed from the submandibular veins coalescing to form the left and right anterior jugular veins (V1 and V2). Immediately on formation, V1 is seen to cross the midline over to the right, where it runs parallel to V2 (Figure 1B). The two veins, later in their course, join together to form V3 before piercing deep to empty into the external jugular vein. In the second cadaver, the left side is devoid of any anterior jugular vein, as this had crossed over to the right side early in its formation.

## DISCUSSION

The clinician needs the knowledge of the anterior jugular vein as it is used in various situations, from venous manometer to cardiac catheterization and cardiac diseases assessment to their importance of being ligated during neck surgeries [2,3]. Our first case in this present study reported a variation in which the left AJV (V1) crossed over to the right AJV (V2). This is similar to the case presented by Primavethi et al., where the two AJVs had come together to form a common trunk at the midline around the 3rd tracheal cartilage [4]. The importance of this variation comes forward in another case described by Sooby et al. in a woman who required an emergency tracheostomy but was taken for a non-routine neck ultrasound which revealed the presence of an AJV right on

the midline [5]. It is instructive to know that due to the attachments of these superficial veins to the platysma above and the fascia below, they do not retract when injured; hence a cut could lead to severe blood loss [6]. The second case presented here showed a variation in the course of the Anterior jugular vein. A course that totally leaves the left side of the neck bare of the AJV while the right side has two. There has been a whole lot of variations of the Anterior jugular vein reported in the literature, ranging from a case of the AJV being a continuation of the facial vein [7] to the size of the AJV reported as larger than the External jugular and the Internal jugular veins [8] and also variations in the termination of the AJV [9,10].

## CONCLUSION

These go to show that in the anatomy of the AJV, there is a high rate of variability and hence underlines the importance of its knowledge in the surgery of the neck as well as in catheterization procedures for every surgeon, anesthetist, and radiologist.

## REFERENCES

1. Hacking, C.; Knipe, H. Internal Jugular Vein. In Radiopaedia.org; Radiopaedia.org, 2013.
2. Balach; ra, N.; Padmalatha, K.; Bs, P.; Ramesh, B.R. Variation of the Veins of the Head and Neck â External Jugular Vein and Facial Vein. International Journal of Anatomical Variations 2012, 5.
3. Schummer, W.; Schummer, C.; Bredle, D.; Friber, R. The Anterior Jugular Venous System:

Variability and Clinical Impact: Anesthesia & Analgesia 2004, 1625–1629, doi:10.1213/01.ANE.0000138038.33738.32.

4. Premavathy, D.; Seppan, P. Anatomical Variation in the Anterior Jugular Veins and Its Clinical Implications – A Case Report. *Journal of the Anatomical Society of India* 2015, 64, S40–S43, doi:10.1016/j.jasi.2015.06.003.

5. Sooby, P.; Pocock, L.; King, T.; Manjaly, G. An Anterior Jugular Vein Variant in a Patient Requiring Tracheostomy, Demonstrating the Importance of Preoperative/Procedural Ultrasound. *BMJ Case Rep* 2016, 2016, bcr2016214599, doi:10.1136/bcr-2016-214599.

6. *Surgical Anatomy and Technique: A Pocket Manual*; Skandalakis, L.J., Ed.; Fifth edition.; Springer: Cham, Switzerland, 2021; ISBN 978-3-030-51312-2.

7. Gupta, V.; Tuli, A.; Choudhry, R.; Agarwal, S.; Mangal, A. Facial Vein Draining into External Jugular Vein in Humans: Its Variations, Phylogenetic Retention and Clinical Relevance. *Surgical and Radiologic Anatomy* 2003, 25, 36–41, doi:10.1007/s00276-002-0080-z.

8. Panagouli, E.; Tsaraklis, A.; Gazouli, I.; Venieratos, D. An Unusual Termination of Seven Veins in the Jugulo-Subclavian Junction. *Int. J. Morphol.* 2009, 27, doi:10.4067/S0717-95022009000400046.

9. Chauhan, N.K.; Rani, A.; Chopra, J.; Rani, A.; Srivastava, A.K.; Kumar, V. Anomalous Formation of External Jugular Vein and Its Clinical Implication. *Natl J Maxillofac Surg* 2011, 2, 51–53, doi:10.4103/0975-5950.85854.

10. Fabian, F.M.; Gesase, A.P. Anomalous Jugular Veins System in an Adult Male Cadaver. *Ital J Anat Embryol* 2006, 111, 215–220.