

## A rare anatomical origin of the inferior thyroid artery from the common carotid artery: A case report

**Authors:** V. Archibong<sup>1\*</sup>; A. Omodan<sup>1</sup>; J. Gashegu<sup>1</sup>

**Affiliations:** <sup>1</sup>Department of human anatomy, school of medicine and pharmacy, College of medicine and health sciences, University of Rwanda.

### ABSTRACT

**INTRODUCTION:** The inferior thyroid artery (ITA) usually originates from the thyrocervical trunk in the majority of the human population (90.5%), or from the subclavian artery in a few populations of humans (7.5%). It is quite rare to find the ITA originating from the common carotid artery (CCA).

**CASE:** This study was a case report of a cadaveric dissection at the anatomy department, university of Rwanda. The case was a 54-year-old male who had 2 inferior thyroid arteries on the left side, with one originating from the thyrocervical trunk and the other taking a rare anatomical origin from the CCA.

**CONCLUSION:** It is important that such anatomical arterial patterns be documented in order to create awareness that is useful to surgeons and imaging specialists. This will help reduce the risk of iatrogenic complications during the surgical intervention to the thyroid gland.

**Keywords:** Inferior Thyroid Artery, Anatomical Variation, Cadaveric Dissection, Case Report

### INTRODUCTION

The use of cadavers is the core model in medical education for the training of surgeons because it offers hands-on practice of surgical procedures before live operations. One such advantage of gross dissection is the opportunity it offers to understand the anatomical variations in the vascular system, especially in critical regions such as the neck [1]. Surgeons and interventional radiologists need this knowledge to limit the incidence of possible iatrogenic complications. The thyroid gland is an endocrine gland located in the cervical region. It consists of a right and left lobe connected by a narrow isthmus [2]. The arterial supply to the thyroid gland consists of 4 pedicle

vessels, 2 superior thyroid arteries originating from the external carotid arteries, and 2 inferior thyroid arteries originating from the thyrocervical trunk, a branch of the subclavian artery [3,4]. In some individuals, anatomical vascular variation exists in the arterial supply to this gland. The commonest variation is the thyroid Ima artery (TIA), which, when present (0.4% - 12.2%), originates from the brachiocephalic trunk (43.3% - 86.7%), from the common carotid artery (2% - 50%) or from the aortic arch (0-66%) [5,6]. The thyroid Ima artery is rarely present in humans but can be found in some animals such as guinea pigs, rabbits, and budgerigar [7,8]. Another rare variation in the supply to this gland is the inferior thyroid artery which originates from the thyrocervical trunk

**\*Corresponding author:** Victor Archibong, victorarchibong3@gmail.com; **Potential Conflicts of Interest (Col):** All authors: no potential conflicts of interest disclosed;

**Funding:** This was a part of the first anatomy annual congress in Rwanda, October 13-15, 2022 sponsored by the MoH, UR, UGHE, AUCA-ASOME, Operation Smile, CHUK and MMI; **Academic Integrity.** All authors confirm that they have made substantial academic contributions to this manuscript as defined by the ICMJE; **Originality:** All authors: this manuscript is original has not been published elsewhere; **Review:** This manuscript was peer-reviewed by two reviewers of the S-CAR committee

**Received:** 27<sup>th</sup> November 2022; **Accepted:** 18<sup>th</sup> February 2023.

**Copyright:** © The Author(s). This is an Open Access article distributed under the terms of the Creative Commons Attribution License (CC BY-NC-ND) ([click here](https://creativecommons.org/licenses/by-nc-nd/4.0/)) which permits unrestricted use, distribution, and reproduction in any medium, provided the original work is properly cited. **Publisher:** Rwanda Biomedical Centre (RBC)/Rwanda Health Communication Center, P. O. Box 4586, Kigali. ISSN: 2079-097X (print); 2410-8626 (online)

**Citation for this article:** V. Archibong; A. Omodan; J. Gashegu. A rare anatomical origin of the inferior thyroid artery from the common carotid artery: A case report. Rwanda Medical Journal, Vol. 80, no. 1, p. 63-65, 2023. <https://dx.doi.org/10.4314/rmj.v80i1.6>

in 90.5% of the human population; in 7.5% of humans, it arises from the subclavian artery, and very rarely does it arise from the common carotid, aortic arch, brachiocephalic, internal thoracic, pericardiophrenic or vertebral arteries [1]. Good knowledge of the thyroid vascular supply is important for surgeons to prevent hemorrhagic complications and nerve injuries in surgery [9]. This is a case report of an inferior thyroid artery variation found in a cadaveric dissection at the surgical anatomy course at the department of human anatomy, University of Rwanda.

### CASE PRESENTATION

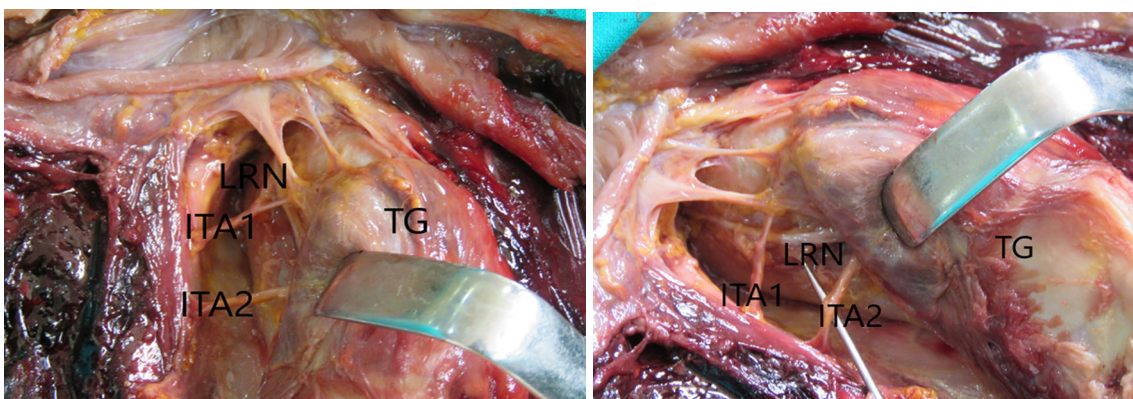
An embalmed cadaver was used for gross dissection during the surgical anatomy course for resident doctors at the department of human anatomy, University of Rwanda. The neck region of a 54-year-old male cadaver was dissected following the steps outlined in the Grant dissector handbook of Sauerland [10]. The case report presented two inferior thyroid arteries on the left side, with one branch originating directly from the left thyrocervical trunk going to the inferior pole of the thyroid gland (ITA1).

Another branch of the inferior thyroid artery originated from the left common carotid artery (ITA2). This variation was documented with the aid of a canon SX60HS camera. The relationships to the inferior thyroid artery registered were the left recurrent laryngeal nerve (LRN) (Figure 1 and 2). The inferior thyroid artery on the right side was one and from the normal source.

### DISCUSSION

The thyroid artery has 2 superior thyroid arteries from the external carotid arteries and 2 inferior thyroid arteries coming from the thyrocervical trunk, a branch of the subclavian artery. Our case report had 2 inferior thyroid arteries on the left side, with one originating from the thyrocervical trunk and another branch originating directly from the left common carotid artery (Figure 1 and 2). An inferior thyroid artery rarely originates from the common carotid artery; this is why our case is worth reporting. The inferior thyroid artery is closely related to the recurrent laryngeal nerve, which plays an important role in vocal cord mobility, phonetic function, and respiratory tract protective function as a sphincter. For this reason, the visualization of the anatomical relationship of recurrent laryngeal nerve with the inferior thyroid artery is essential for its preservation [10].

Toni et al. proposed that the inferior thyroid artery (ITA) can originate from the thyrocervical trunk and less frequently from the subclavian artery directly, but originally from the common carotid artery is rarely documented [11]. In the report by Toni et al., the ITA takes origin from the thyrocervical trunk in 90% of cases, from the subclavian artery in 10%, and from the vertebral artery in 0.6% cases, and from the common carotid artery in 0.2% of cases. These statistics show a rare anatomical variation (14). Ngo Nyeki et al. [3] reported a rare anatomical variation of the ITA originating directly from the common carotid artery instead of the thyrocervical trunk. A recent report by Novakov and Delcheu [1] also documented 2 rare cases of the ITA. The first



**Figure 1: Inferior thyroid artery (ITA1)**

*Originating from the thyrocervical trunk, and a second inferior thyroid artery (ITA2) originating from the common carotid artery. Note the relation to the left recurrent laryngeal nerve (LRN) and Thyroid gland (TG).*

case was an aberrant origin of the ITA from the left common carotid artery, and the second case was an absent ITA which was replaced by the thyroid Ima artery from the brachiocephalic trunk.

## CONCLUSION

Our case report has a similar trend of ITA variation to previous studies' reports. This anatomical variation poses a risk of perioperative bleeding and nerve injuries, especially during surgical intervention in the neck region. Therefore, the knowledge of this variation is useful to surgeons as it may help reduce complications during surgery.

## REFERENCES

1. Novakov, S.S.; Delchev, S.D. Two Cases of Variations in Inferior Thyroid Arterial Pattern and Their Clinical Implications. *Folia Morphol* 2022, VM/OJS/J/88401, doi:10.5603/FM.a2022.0032.
2. Snell, R.S.; Snell, R.S. *Clinical Anatomy by Regions*; 8th ed.; Wolters Kluwer (Health)/Lippincott Williams & Wilkins: Philadelphia, 2008; ISBN 978-0-7817-6404-9.
3. Ngo Nyeki, A.-R.; Peloni, G.; Karenovics, W.; Triponez, F.; Sadowski, S.M. Aberrant Origin of the Inferior Thyroid Artery from the Common Carotid Artery: A Rare Anatomical Variation. *Gland Surg* 2016, 5, 644–646, doi:10.21037/gs.2016.12.03.
4. Tang, J.; Zhang, W. Dorian Gray's Spiritual Ecological Crisis and the Inspiration to Modern People. *ALS* 2013, 01, 5–9, doi:10.4236/als.2013.12002.
5. Bergman's *Comprehensive Encyclopedia of Human Anatomic Variation*; Bergman, R.A., Tubbs, R.S., Shoja, M.M., Loukas, M., Eds.; John Wiley & Sons, Inc: Hoboken, New Jersey, 2016; ISBN 978-1-118-43035-4.
6. Yohannan, D.G.; Rajan, R.; Chandran, A.B.; Krishnapillai, R. An Unusual Origin and Course of the Thyroidea Ima Artery, with Absence of Inferior Thyroid Artery Bilaterally. *Surg Radiol Anat* 2019, 41, 235–237, doi:10.1007/s00276-018-2122-1.
7. Won, H.-S.; Han, S.-H.; Oh, C.-S.; Chung, I.-H. Superior and Middle Thyroid Arteries Arising from the Common Carotid Artery. *Surg Radiol Anat* 2011, 33, 645–647, doi:10.1007/s00276-011-0781-2.
8. Radek, T.; Piasecki, T. The Topographical Anatomy and Arterial Supply of the Thyroid and Parathyroid Glands in the Budgerigar (*Melopsittacus Undulatus*). *Folia Morphol (Warsz)* 2004, 63, 163–171.
9. Mariolis-Sapsakos, T.; Kalles, V.; Papapanagiotou, I.; Bonatsos, V.; Orfanos, N.; Kaklamanos, I.G.; Manolis, E. Bilateral Aberrant Origin of the Inferior Thyroid Artery from the Common Carotid Artery. *Surg Radiol Anat* 2014, 36, 295–297, doi:10.1007/s00276-013-1153-x.
10. Ray, B.; Pugazhandhi, B.; D'Souza, A.S.; Saran, S.; Fasil, M.; Srinivasa, R.S. Analysis of the Arterial Anatomical Variations of Thyroid Gland: Anatomic Guide for Surgical Neck Dissection. *BLL* 2012, 113, 669–672, doi:10.4149/BLL\_2012\_151.
11. Toni, R.; Della Casa, C.; Castorina, S.; Roti, E.; Ceda, G.; Valenti, G. A Meta-Analysis of Inferior Thyroid Artery Variations in Different Human Ethnic Groups and Their Clinical Implications. *Annals of Anatomy - Anatomischer Anzeiger* 2005, 187, 371–385, doi:10.1016/j.aanat.2005.04.004.