

Alcohol-Diazepam Combination: Implication on the Histoarchitectural Profile of the Hippocampus in Male Rats.

Adekomi DA^{1,2}, Adewole OS², Muhammed OA³, Oyesomi TO¹, Oremosun Aa¹

Original Article

ABSTRACT

Objective: Damage to hippocampal neurons has not been described as a constant finding in studies addressing the effects of alcohol and diazepam in laboratory based studies, the present study aimed to elucidating the changes in the histoarchitectural changes of the hippocampus following separate and combined diazepam and alcohol administration in male Wistar rats.

Methodology: Twenty male Wistar rats were randomly divided into four groups (n=5): control (A), 3 mg/kg diazepam (B), 30% v/v ethanol (C), and 30% v/v ethanol plus 3 mg/kg diazepam (D). All administration was done orally for 30 days.

Major findings: There were no distortions in the hippocampal profile of the rats in the control group. The histoarchitectural profile of the hippocampus of the rats in group B showed less significant damage. The histoarchitectural profile of the hippocampus of the rats in group C was disrupted with evidence of enlarged cell bodies and distorted membrane. The hippocampal profile of the rats in group D were with marked neuronal necrosis and variable neuronal loss within the hippocampal subfield.

Conclusion: It was observed that co-administration of ethanol and diazepam conferred neurodegenerative effects on the neuronal profile of the hippocampus in rats.

Key words: Addiction, abuse, use, dependence, drug.

Corresponding author: Adekomi D. A. (alexquye@gmail.com)

¹Department of Anatomy, College of Medicine, Ekiti State University, Ado Ekiti, Nigeria.

²Department of Anatomy and Cell Biology, Obafemi Awolowo University, Ile-Ife, Osun State, Nigeria.

³Histopathology Unit, Pathology Department, University of Ilorin Teaching Hospital, Ilorin, Kwara State, Nigeria.

Alcohol-Diazepam combinaison: Implication sur le profil Histoarchitectural de l'hippocampe chez le rat mâle.

Adekomi DA^{1,2}, Adewole OS², Muhammed OA³, Oyesomi TO¹, Oremosun Aa¹

L'article d'origine

RÉSUMÉ

Objectif : Dommages aux neurones hippocampique n'a été décrite comme une constante dans les études portant sur les effets de l'alcool et le diazépam en laboratoire en fonction des études, la présente étude vise à élucider les changements dans la histoarchitectural changements de l'hippocampe suivant séparés et combinés le diazépam et l'alcool en administration mâle Wistar rats.

Méthodologie : Vingt hommes rats Wistar ont été aléatoirement répartis en quatre groupes (n= 5): contrôle (A), 3 mg/kg le diazépam (B), 30% v/v d'éthanol (C), et 30% v/v d'éthanol plus 3 mg/kg le diazépam (D). Toutes les tâches d'administration a été fait oralement pendant 30 jours.

Principales conclusions : Il n'y a pas de distorsion dans le profil hippocampique des rats dans le groupe contrôle. Le profil histoarchitectural de l'hippocampe du rat dans le groupe B a montré moins d'importants dommages. Le profil histoarchitectural de l'hippocampe du rat dans le groupe C a été perturbée par des éléments de preuve élargie des corps cellulaires et membrane déformée. Le profil hippocampique des rats en groupe D ont été marqués avec nécrose neuronale et variable perte neuronale au sein du sous-champ hippocampique.

Conclusion : Il a été observé que la co-administration de l'éthanol et le diazépam conférés neurodégénératives effets sur le profil neuronale de l'hippocampe chez le rat.

Mots clés :- toxicomanie, abus, consommation, dépendance, la toxicomanie.

*Auteur correspondant: Adekomi D. A. (alexquye@gmail.com)

¹Department of Anatomy, College of Medicine, Ekiti State University, Ado Ekiti, Nigeria.

²Department of Anatomy and Cell Biology, Obafemi Awolowo University, Ile-Ife, Osun State, Nigeria.

³Histopathology Unit, Pathology Department, University of Ilorin Teaching Hospital, Ilorin, Kwara State, Nigeria.

INTRODUCTION

In modern medicine, benzodiazepines have been used in the medical and dental field, for the relief of anxiety and tension due to their amnesic, muscle relaxant, and sedative properties. Diazepam acts by enhancing GABA-ergic neurotransmission through an allosteric interaction at the benzodiazepine- GABAA-barbiturate-chloride ionophore receptor complex (1). It is the most commonly used anticonvulsant drug followed by phenobarbitone and pentobarbital. Overdoses of many of the over-the-counter drugs often happen either accidentally or may be due to excessive administration by a well-meaning owner. Extensive studies in Man and animals have shown that the use of diazepam has replaced that of barbiturates, making them one of the most commonly prescribed category of drugs (2).

According to (3), diazepam is reported to be effective in treating both acute and chronic convulsion in some mammals. Clinically, diazepam is the most commonly used anticonvulsant followed by phenobarbitone and pentobarbital. In 2002, (4) reports that diazepam is effective in treating maladies such as anxiety, agitation, tremor, delirium, hallucination, anxiety, tension, fear, aggression, stress and in alcohol withdrawal. Most importantly, overdoses of over the counter drugs happen either accidentally or may be due to excessive administration by a non-professional medical personnel resulting into addiction, abuse and/or misuse.

Ethanol is a central nervous system depressant and, at higher concentrations, it may cause coma, respiratory depression and death. It is one of the incessantly abused neurotoxic drugs and it is also known to have deleterious effect(s) as seen in Korsakoff's patients (5). It has also been reported by (6), that the abuse, addiction and misuse of alcohol is capable of reducing the mean volume of Purkinje cell perikaryon in alcoholics.

The particular processes presumed to underlie the abuse, addiction and misuse of alcohol and its manifestations involve

functions such as attention, cognition, emotion, learning and memory. The normal brain must carry out these functions at the same time in order to comprehend the environment, assess the importance of environmental stimuli in terms of survival, and start behavioral reactions. These actions require efficient communication and interaction among different regions of the brain and at multiple levels within those areas. It is now known that the abuse of alcohol results into impaired medical conditions such as alcohol-induced persisting amnesic disorder known as Wernicke-Korsakoff syndrome, dementia, impaired language reasoning and less effective problem-solving skills (7). Studies have shown, (8,9,10) that the central nervous system is severely affected by alcohol consumption and this causes sedation and relief of anxiety and at higher concentrations, the severity of the effect of alcohol may include slurred speech, ataxia, and impaired judgment and/or reasoning.

The hippocampus is anatomically one of the oldest regions of the brain. It is made up of interconnected layers of the dentate gyrus and cornu ammonis. Each of the layers and/or subfields of the hippocampus has been shown to be involved in different hippocampal functions and tasks. The best known of the hippocampal functions and tasks include the ability of the hippocampus to express current self-location in spatial and other cognitive dimensions (11), and its involvement in the storage and retrieval of memory (12). The hippocampus has been implicated in other areas such as learning, motivation, and the control of appetite (13).

Unfortunately, little is known about the effect of combined use of alcohol and diazepam on the histological outline of the hippocampus. Taking into account the reported implication(s) of abuse of alcohol and that of diazepam on the neuroanatomical structure (14 -17). The aim of this study is to observe the changes in the histoarchitectural profile of the hippocampus following separate and combined diazepam and ethanol administration.

MATERIALS AND METHODS

Animal Care and Treatment

This study was carried out at Ekiti State University according to the Helsinki Guidance for Animal Practice published in 1964. This study included 20 male rats (Wistar strain) with body weights ranging from 164 to 220 g. The rats were housed in four polycarbonate cages with stainless steel wire lids, under a cycle with a light phase of 12 h from 7 a.m. to 7 p.m. with free access to food and water. Four treatment groups were established:

Group A (control): treated with double-distilled water,

Group B: treated with 3 mg/kg diazepam,

Group C: treated with 30% v/v ethanol, and;

Group D: treated with 30% v/v ethanol plus 3 mg/kg diazepam.

The vehicle for drug delivery in this study was double-distilled water and all administration was done orally for 30 days (18)

Tissue Preparation for Light Microscopy

Twenty-four hours after the last administration, all rats were sacrificed by cervical dislocation. The skulls were cracked, brains were excised and removed open with a bone forceps. The hippocampi were dissected out for histopathological studies. The dissected hippocampi were rinsed with normal saline followed by 50 ml of 4% paraformaldehyde in PBS, postfixed in neutral buffered formalin for 24 hours. For cresyl violet staining, the method of Stranahan (19) was adopted. Briefly, a 1:5 series of sections was stained in 2.5% cresyl violet acetate (Sigma, St. Louis, MO). Stained sections were observed by using a Leica DM2500 microscope.

RESULTS

The histological outlines of the hippocampi of the rats used in this study are presented in figures 1-4. The hippocampal outline of the rats in group A (control) were with no observable neuronal disruption as seen in Fig 1A and 1B. The hippocampal profile of the rats in group B treated with 3 mg/kg of diazepam was presented in Fig 2A

and 2B. The neuronal profile of the rats were relatively well preserved (black arrows) compared with the control group. The hippocampal section of the rats in group C treated with 30% v/v ethanol as seen in Fig 3A and 3B were with degenerative characteristics such as loss of neuronal connections and loss of Nissl's substances with complete loss of cytoplasmic content and nuclear materials (white arrows) but with peri-nuclear Nissl granules. Fig 4A and 4B displayed the hippocampal outline of the representative rat treated with 30% v/v ethanol and 3 mg/kg diazepam. The neuronal structure in the hippocampus was markedly distorted with loss of neuronal connections, loss of cytoplasmic contents and Nissl's substance (green arrows), neuronal vacuolation (blue arrow), loss of peri-nuclear Nissl granules, degeneration of the axonal systems and loss of connections to adjacent neurons, and atrophy of the neurons; these observed characteristics are features of necrotic cell death.

DISCUSSION

In recent years, there has been an excessive increase in the abuse and use of psychotropic drugs by the general public, these include the use of minor tranquilizers. However, there are dearth of information to determine the impact of such drugs on the hippocampus.

Muhammed et al., (20) documented that some of the advantages of preclinical assessment studies are the resultant responses of experimental species, the controlled conditions under which they can be maintained and studied, and the validation of appropriate measures, such as tissue volume grades, which can be applied to inferences of observations and results in laboratory animals for evaluation of possible side effects in Man. Similarly, it was observed that the response(s) of experimental animals is similar to that of Man, with significant exceptions to peroxisome proliferators and α_2 u globulin nephropathy inducers that do not increase in human the same effects as in rodents. (21,22)

Drug intoxication is always related to a

generation of free radicals that cause membrane damages and alteration of the calcium homeostasis. This seems to be a common unspecific mechanism in toxic responses which may cause cell death (23). CNS cells are extremely sensitive and vulnerable to the action of free radicals. The impairment of neuronal function may be irreversible.

Reports from both clinical and laboratory studies have shown that diazepam overdose can cause CNS depression which may lead to coma and death. In a study, it was observed that acute administration of high doses of diazepam is capable of causing a cascade of oxidative changes which may significantly decrease some of the cell's antioxidant defense. (24)

The main finding of this study includes a significant overall degeneration in the neuronal profile of the hippocampus of rats treated with a combination of diazepam and ethanol for a duration of 30 days. This effect was markedly significant in the CA1 region of the hippocampus of the rats in group D.

The distortion and neuronal disruption of the hippocampus of the rats co-treated with ethanol and diazepam may be related with some alteration in some neuronal functions associated with the hippocampus that could be detrimental to normal well being.

The observed alterations in the hippocampi of the rats in group D occur as a result of the heightened and/or marked neurotoxic effect(s) of the combined effect of ethanol and diazepam.

Studies has shown that alcohol confer deleterious effects on several regions of the brain (5, 25). In this study, it was observed that oral administration of 30% v/v of ethanol for thirty days conferred necrotic characteristics on the neurons in CA1 region of the hippocampi of the ethanol treated rats. Pathological cell death is known as necrosis and could occur from extrinsic factor such as toxins and trauma (26). In cellular necrosis, there is marked disruption of cellular membranes and structural and the functional integrity of the cell is altered.

It had been reported that combined use of ethanol and diazepam exerts marked effects upon behavior and causes a decreased content mainly of 5-HT and 5-HIAA in many regions of the brain (27).

This study found a marked significant distortion in the neuronal outline of the neurons in the CA1 region of the hippocampus of the alcohol and diazepam co-treated group compared with the control and as well compared with the diazepam treated group. Rats administered with alcohol via oral gavage during the period of this study displayed a comparatively slight alteration in the neuronal outline of the neurons in the CA1 region of the hippocampus and this is in support of the outcome of the study of (5, 25).

CONCLUSION

This study identified that co-administration of alcohol and diazepam caused deleterious alterations on the histological profile of the CA1 region of the hippocampus of the treated rats and this may compromise the integrity of the neuronal profile of the hippocampus. These finding suggest that combined use of alcohol and diazepam is deleterious on the hippocampus.

Future studies are needed in order to observe if these alterations are reversible, the relationship between these neuronal alterations and their connections and/or interconnections with the subfields of the hippocampus and their relationship to hippocampal integrity in learning, emotion, amnesia and memory.

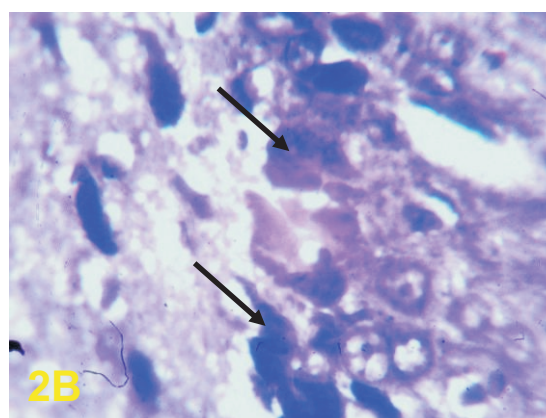
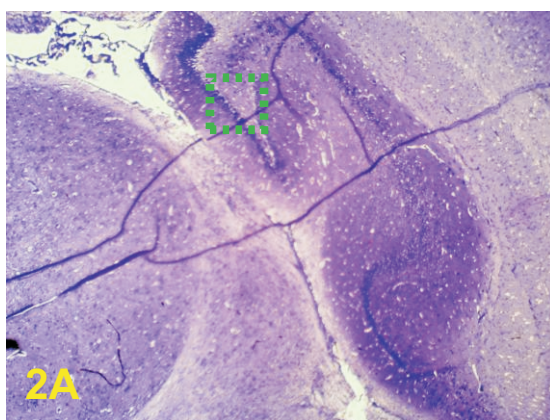
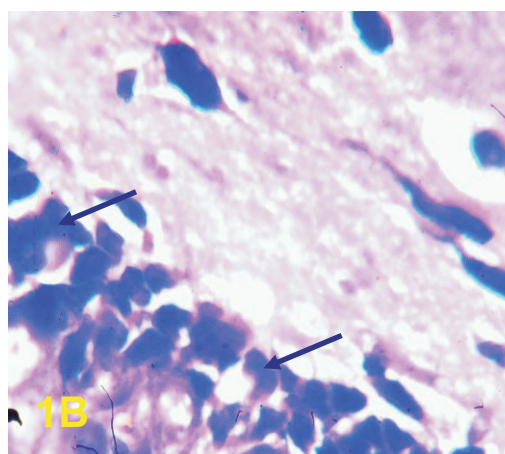
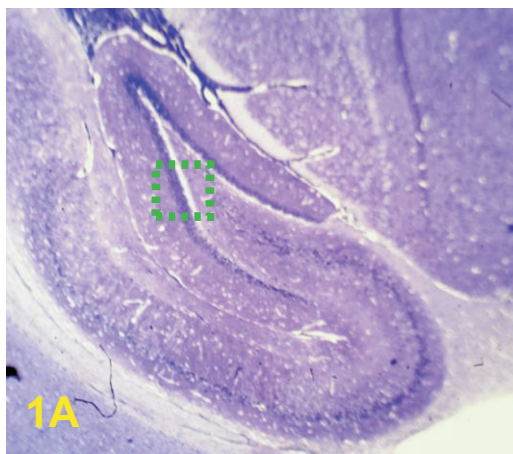
REFERENCES

1. Slavana D, Natasa S, Ljubica G and Varagic V. Behavioural and Endocrine responses of socially isolated rats to long-term diazepam treatment. *Acta Veterinaria (Beograd)* 2007. 57(4): 291-302.
2. Murray JB. Effects of valium and librium on human psychomotor and cognitive functions. *Genet Psychol Monogr.*, 1984. 109 (2): 167-97

3. Mosallanejad B, Avizeh R, Najafzadeh VH, Pourmedhi M. Evaluation of prophylactic and therapeutic effects of silymarin on mebendazole-induced hepatotoxicity in cats. *Comp. Clin Pathol.*, 2011.10: 1157-64
4. Maddison JE, Page SW, Church DB. *Small Animal Clinical Pharmacology*. Elsevier Health Sciences, 2002; p. 575
5. Mitra NK and Nagaraja HS. Effect of chronic ethanol exposure on the count of cerebellar Purkinje cells and motor coordination in adult mice. *Eur J Anat*, 2008. 12 (2): 67-71.
6. Andersen BB. Reduction of Purkinje cell volume in cerebellum of alcoholics. *Brain Res*, 2004. 1007: 10-18.
7. Marlene O and Ksenija M. Alcoholism and the Brain: An Overview. *Alcohol and Health Res.*, 2003. 27(2):125-133.
8. Alderazi Y and Brett F. Alcohol and the nervous system. *Curr. Diag. Pathol.*, 2007. 13(3): 203-209.
9. Johnsen-Soriano S, Bosch-Morell F, Miranda M, Asensio S, Barcia JM, Roma J, et. al., Ebselen prevents chronic alcohol-induced rat hippocampal stress and functional impairment. *Alcohol Clin. Exp. Res.*, 2007. 31(3): 486-92
10. Chin VS, Van SCE, Matthews DB. Effects of ethanol on hippocampal function during adolescence: a look at the past and thoughts on the future. *Alcohol*. 2010. 44(1): 3-4
11. Leutgeb S, Leutgeb JK, Treves A, Moser MB, Moser EI. Distinct ensemble codes in hippocampal areas CA3 and CA1. *Science*. 2004. 305:1295-98.
12. Samsonovich AV and Nadel L. Fundamental principles and mechanisms of the conscious self. *Cortex*. 2005. 41(5): 669-89
13. Tracy AL, Jarrard LE, Davidson TL. The hippocampus and motivation revisited: appetite and activity. *Behav. Brain Res.*, 2001. 127: 13-23.
14. Garcia-Moreno LM, Santin LJ, Rubio S, Gonzalez-Pardo H, Arias JL. Effects of ethanol and diazepam on AgNOR neuronal activity in the medial mammillary nucleus. *Psicotherma*. 1993. 5(1): 125-134.
15. Kalynchuk LE and Beck CHM. Behavioral analysis of diazepam-induced memory deficits: evidence for sedation-like effects. *Psychopharmacol.*, 1992. 106: 297-302.
16. Nixon K and Crews FT. Temporally specific burst in cell proliferation increases hippocampal neurogenesis in protracted abstinence from alcohol. *J Neurosci.*, 2004. 24(43):9714-22.
17. Shikanai H, Izumi T, Matsumoto M, Togashi H, Yamaguchi T, Yoshida T, Yoshioka M. Diazepam-induced increases of synaptic efficacy in the hippocampal-medial prefrontal cortex pathway are associated with its anxiolytic-like effect in rats. *J. Pharmacol. Sci.*, 2010. 114(3): 341-6
18. Lauing K, Himes R, Rachwalski M, Strotman P, Callaci JJ. Binge alcohol treatment of adolescent rats followed by alcohol abstinence is associated with site-specific differences in bone loss and incomplete recovery of bone mass and strength. *Alcohol*. 2008. 42(8): 649-656
19. Stranahan AM, Jiam NT, Spiegel AM, and Gallagher M. Aging Reduces Total Neuron Number in the Dorsal Component of the Rodent Prefrontal Cortex. *The J. Comp. Neurol. Res in Sys. Neurosci*. 2012. 520:1318–1326
20. Muhammed OA, Adekomi DA, Enaibe BU and Ademosun AA. Histological, histochemical and immunohistochemical evaluation of the effects of seed and pulp of *Carica papaya* on the visual relay centres in animal model. *J. Med. Plants Res.*, 2013. 7(16); 1030-1038.

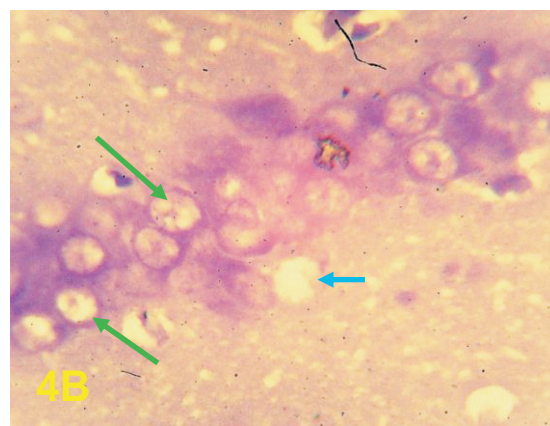
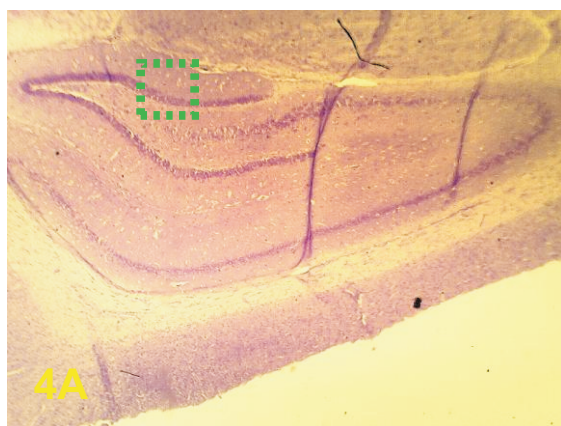
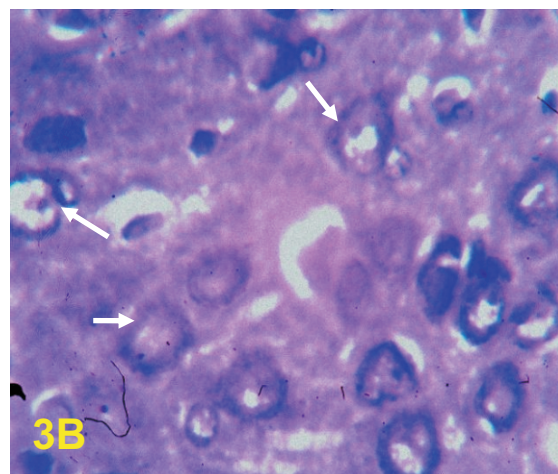
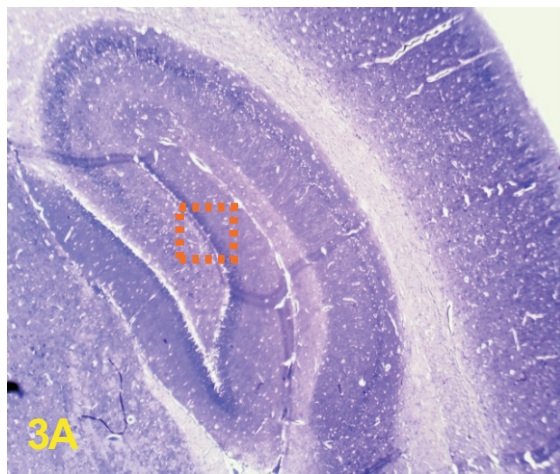
21. Avwioro OG. *Histochemistry and Tissue Pathology: Principles and techniques*. 2002. 1st ed, Claverianum Centre.
22. Olson H, Betton G, Robinson D, Thomas K, Monro A, Kolaja G. Concordance of the toxicity of pharmaceuticals in humans and in animals. *Regal Toxicol. pharmacol.*, 2000. 32:56-67
23. Kakkar P, Musavi S, Mehrotra S. Mitochondrial responses under chemical stress. *Polish J. Env. Stud.*, 2000. 9(4): 285-290.
24. Musavi S and Kakkar P. Effect of diazepam treatment and its withdrawal on pro/antioxidative processes in rat brain. *Mol. Cell Biochem.*, 2003. 245(1-2):51-56.
25. Kumar S, Dhankhar N, Goyal S, Kar V, Shrivastava M. Hippocampal Injury at Mitochondrial Level Provoked by Iminodipropionitrile, Neuroprotective Effect of Alpha Lipoic Acid. *Int. J. Res. in Pharm and Sci.* 2011. 1(2): 67-76
26. Farber JL, Chein KR, Mitnacht S. The pathogenesis of Irreversible cell injury in ischemia; *Amer. J. Pathol.* 1981. 102:271-281
27. Felinska W, Pyka U, Szkilnik R, Czechowicz K, Siekierska E, Pilsniak U, Brus R. Effect of ethanol and diazepam given to pregnant rats on the behavior and catecholamine content in the brain of offspring. *Pol. J. Pharmacol. Pharm.*, 1989. 41(3):223-5.

HISTOLOGICAL ILLUSTRATIONS



Section 1A Cresyl violetstained neurons in the hippocampus of the representative rat in the control group treated with double distilled water. The neuronal outline were well preserved. Note: The panoramic view of the green bordered region (1A = 400x) is presented on the right (1B = 1000x).

Section 2A: Cresyl violet-stained neurons in the hippocampus of the representative rat in the diazepam treated group. The neuronal outline were relatively well preserved (black arrows). Note: The panoramic view of the green bordered region (2A = 400x) is presented on the right (2B = 1000x).



Section 3A: Cresyl violet-stained neurons in the hippocampus of the representative rat in the alcohol treated group. The neuronal outline were with loss of neuronal connections and Nissl's substances with complete loss of cytoplasmic content and nuclear materials (white arrows). Note: The panoramic view of the brown bordered region (3A = 400x) is presented on the right (3B = 1000x).

Section 4A: Cresyl violet-stained neurons in the hippocampus of the representative rat co treated with ethanol and diazepam . The neuronal outline were with markedly distorted neuronal connections, loss of cytoplasmic contents and Nissl's substance (green arrows), neuronal vacuolation (blue arrow), loss of peri-nuclear Nissl granules, degeneration of the axonal systems and loss of connections to adjacent neurons, and atrophy of the neurons. Note: The panoramic view of the green bordered region (4A = 400x) is presented on the right (4B = 1000x).