

## Paediatric ocular and adnexa malformation in Birnin Kebbi, north-western Nigeria

Monsudi KF<sup>1</sup>, Ayanniyi AA<sup>2</sup>, Lawal TO<sup>3</sup>, Adepoju FG<sup>4</sup>, and Saka ES<sup>1</sup>

### Original Article

#### ABSTRACT

**Objectives:** Congenital eye and adnexa malformations although rare, are however a major challenge to health professionals in terms of diagnosis. There are also emotional, financial and stigmatization challenges experienced by the patients and their relatives. Appropriate management of these patients requires multidisciplinary approach. The study is to determine the pattern and presentation; and also create awareness among health workers and the public on the congenital eye/adnexal malformation.

**Methods:** A 3-year retrospective review of all patients who presented at our hospital on account of congenital eye/adnexal malformations from 1st January 2011 through 31st December 2013 was done. Information on socio-demographics, laterality, type of malformation, presentation and Visual acuity were extracted from patients' folders. The data was analyzed by SPSS version 18.

**Results:** 78 cases of congenital eye/adnexal malformations were recorded during the study period. There were equal numbers of males and females (39 each). Most of the patients were 1 year and above (57.7%) at the time of diagnosis. Both eyes were involved in 54 (69%) patients and right eye were 17 (22%). The common congenital eye/adnexal defects identified were congenital ptosis 12 (15.4%), glaucoma 10 (12.8%) and esotropia 9 (11.5%). Majority of the mothers were between 21 and 25 years of age (65.4%) as at the time of giving birth to these patients.

**Conclusion:** Congenital ptosis and glaucoma were the commonest types of congenital eye/adnexal defects seen in this environment. These defects were important causes of poor vision and blindness. Parents/caregivers and health professionals awareness on examination, early presentation and treatment is highly required.

**Key words:** Congenital eye/adnexal malformations, paediatric, parent/caregiver

\*Corresponding author: Dr. Kehinde Fasasi Monsudi. E-mail: [kfmoshood@yahoo.com](mailto:kfmoshood@yahoo.com)

<sup>1</sup>Department of Ophthalmology, Federal Medical Centre, Birnin Kebbi, Nigeria

<sup>2</sup>Department of Ophthalmology, College of Health Sciences, University of Abuja, PMB 117, Abuja, Nigeria

<sup>3</sup>Department of Paediatric, Federal Medical Centre, Birnin Kebbi, Nigeria

<sup>4</sup>Department of Ophthalmology, University of Ilorin, Kwara State, Nigeria

## **Oculaire de pédiatrie et de ses annexes malformation au Birnin Kebbi, du nord - ouest du Nigeria**

**Monsudi KF<sup>1</sup>, Ayanniyi AA<sup>2</sup>, Lawal TO<sup>3</sup>, Adepoju FG<sup>4</sup>, and Saka Es<sup>1</sup>**

### **Article Original**

#### **RÉSUMÉ**

**Objectif:** Yeux congénitales et formations adnexales bien que rares, sont cependant un défi majeur pour les professionnels de la santé en termes de diagnostic. Il y a aussi, les défis financiers et la stigmatisation émotionnelle subis par les patients et les proches des patients. Une gestion appropriée de ces patients nécessite une approche multidisciplinaire. Pour déterminer le modèle et la présentation et de sensibiliser les agents de santé et le public sur le congénital des yeux/annexes malformation.

**Méthode:** Une étude rétrospective de tous les patients qui se sont présentés à notre hôpital à cause de malformations congénitales des yeux/annexes de l'1er Janvier 2011 jusqu' à 31 Décembre 2013 a été faite. Informations sur socio-démographiques, la latéralité ; le type de malformation la présentation et l'acuité visuelle ont été extraites des dossiers des patients. La donnée était analysée par la version SPSS 18.

**Résultat:** 78 cas de malformations congénitales des yeux/annexes ont été enregistrés pendant la période d'étude. Il y avait un nombre égal d'hommes et de femmes (39 chaque). La plupart des patients étaient de un an et plus (57.7%) au les deux ont été impliqués en 54 (69%) patients et l'oeil droit était 17 (22%). Les anomalies congénitales des yeux/annexes identifiées étaient Ptose congénitale 12 (15.40%), et le glaucome 10 (12.8%), l'estropie 9 (11.5%). La majorité des mères étaient entre 21 – 25 ans de l'âge (65.4%) pendant la naissance de ces patients.

**Conclusion:** Ptose congénitale et glaucome étaient les types les plus courants de l'œil/défauts congénitaux annexes vus dans cet environnement ces défauts étaient des causes importantes de mauvaise vision et la cécité. Les parents/fournisseurs de soins et la prise de conscience de professionnels de santé à l'examen la présentation et le traitement précoce est fortement nécessaires.

**Mots Cles:** œil congénital/formations adnexales, pédiatrie, parent/fournisseurs de soins.

\* Auteur correspondant: Dr. Kehinde Fasasi Monsudi. E-mail: kfmoshood@yahoo.com

<sup>1</sup>Department of Ophthalmology, Federal Medical Centre, Birnin Kebbi, Nigeria

<sup>2</sup>Department of Ophthalmology, College of Health Sciences, University of Abuja, PMB 117, Abuja, Nigeria

<sup>3</sup>Department of Paediatric, Federal Medical Centre, Birnin Kebbi, Nigeria

<sup>4</sup>Department of Ophthalmology, University of Ilorin, Kwara State, Nigeria

## **INTRODUCTION**

Congenital eye and adnexal malformations are anatomical abnormalities or defects that present at birth. The causes of this malformations may be genetic (familial/sporadic) and non-genetic (environmental). It may present as a single entity or part of systemic syndromes (1). Eye and adnexa development becomes evident at approximately 22 days and 28 days respectively (1). During these periods any changes in gene expression or “insults” will lead to disruption in organogenesis and cellular differentiation resulting in malformation with associated visual impairment, blindness, physical or mental derangement in the affected individual. In developed countries the prevalence of ocular malformation from previous studies (2-7) ranges between 0.04 to 6.8/10,000 live births. However studies from Nigeria by Lawan (8) and Adekoya et al. (9) reported prevalences of 1.7% and 9.7% respectively. The management of a patient with this condition is challenging to the parent, patient and health profession. Some of the diagnostic challenges posed by the congenital ocular malformations include; history taken, visual acuity assessment in children, examination under anaesthesia with its complications, laboratory investigations and non-availability of skill manpower to operate on these patients. Many “homes” have collapsed following emotional, financial and stigmatization experienced by the patient, parent and relatives.

To the best knowledge of the authors no study on the pattern of congenital ocular /adnexal malformations has been done previously in Kebbi State therefore, the aim of this study was to determine the pattern and presentation; and also create awareness among health workers and the public on the congenital eye/adnexal malformation.

## **MATERIALS AND METHODS**

A 3-year retrospective study conducted

between 1st January 2011 through 31st December 2013. The folders of all paediatric patients aged (0-16 years) who presented at our hospital through Accident and Emergency (A&E), paediatric clinic and directly to our eye clinic were retrieved through our hospital health records unit.

Congenital ocular and /adnexa malformation is anatomical eye and or adnexa abnormality detected or present at birth. The Federal Medical Centre is the only tertiary eye centre in Kebbi State and a referral centre for the surrounding states (Sokoto, Niger and Zamfara) and countries (Benin and Niger Republic).

For this study a patient with multiple ocular/adnexal malformations, each abnormality was counted separately. From each folder information on socio-demographics (age at presentation, sex, occupation), laterality, type of congenital eye/adnexal malformation, presenting complaints and maternal age at birth of the baby were extracted. These information were entered into data collection forms. The visual acuity of the patients was assessed by ophthalmologist using various methods according to patient age. These includes: occlusion method, fixation and follow (using pen torch), picture chart and Snellen's chart. The data was analyzed with SPSS version 18 statistical software (SPSS Inc., Chicago, IL, USA). Simple descriptive statistics was done and frequency tables generated for variables. Fischer's exact test was used to test for statistical significant variables. P-value < 0.05 was considered statistically significant.

Federal Medical Centre Health and Research committee gave approval for the study.

## **RESULTS**

Of 1110 paediatric patients seen at our eye clinic during the 3 years study periods 78 (7%) of them presented on account of congenital eye/adnexal malformations.

Males and females were equal in number (39 each) with M:F ratio of 1:1. The mean age was 1.58 (SD± 0.5). The minimum age at presentation was a day old and maximum age was 16 years.

Table 1 shows the socio-demographics and laterality in the patients. The oldest patient was a 16 year old girl with bilateral congenital ptosis. Majority of the subjects were 1 year old (57.7%) at presentation to our hospital with twenty three (29.5%) being students and 5 (6.4%) house wives. Both eyes were affected in 54 (69%) patients followed by right eye 17 (22%). Congenital ptosis 12 (15.4%) was the commonest type of malformation seen, followed by congenital glaucoma 10 (12.8%).

Figure 1 shows the type of congenital eye/adnexal malformation seen in the patients. Drooping of the upper lid 12 (15.4%), followed by whitish speck in the eye 10 (12.8%) were the commonest presenting complaints. Figure 2 shows the presenting complaints of the patients at presentation. In about half of the patients, the visual acuities (VA) were not recorded. Among those with recorded VA, most of them had severe visual impairment in one or both eyes.

Table 2 visual acuity of the patients at presentation. Majority of the mothers were between 21 and 25 years old (65.4%) at the birth of the patient with congenital eye/adnexal malformation, Figure 3.

## DISCUSSION

The prevalence of congenital eye and or adnexa varies from developing to developed countries. Many studies (2-7) from developed countries reported a range of 0.04-6.8/10,000 live birth. In this study congenital eye/adnexal malformations accounts for 7% of 1110 of paediatric patients seen in the 3-year-study-period. This was different from studies from Nigeria by Lawan (8) and Adekoya et al. (9) who reported prevalence of 1.7% and 9.7% respectively,

while KaimboWaKaimbo et al. (10) from Democratic Republic of Congo and Eballe et al. (11) from Cameroon reported 2.2% and 6.7% respectively. The difference in these results may be because of geographic location of the study population. In our study there were equal number of males and females. This was similar to Eballe et al. (11) but different from previous studies in Nigeria (9), Hawaii (12) and China (13) where female preponderance was reported. Several authors have also reported male preponderance (8,10,14,15). In this study majority (57.7%) of patients presented at our hospital at one year and above similar to previous studies from Nigeria (9), Cameroon (11) and United Kingdom (16). But different from studies carried out in Europe where diagnosis rates of 80% were reported during the first week of life (17, 18). The difference might be because of ignorance of the parent/caregiver about the hospital's ability to manage these defects and lack of attention given to suspicious eye malformations by the health professionals.

Congenital ptosis was the commonest malformation seen and accounted for 15.4%, with 2/3 of the cases being unilateral. This was contrary to the study by Adekoya et al. (9) and Eballe et al. (11) where congenital ptosis was 2nd and 5th commonest type of malformation seen. Worldwide the prevalence of congenital ptosis is unknown. Severe unilateral congenital ptosis usually covers the visual axis which may result in Amblyopia and subsequently affect the quality of life of the affected individual. In half of our patients visual acuity (VA) were not recorded in similarity to a previous study (9). This could explain the challenges faced by eye care worker in visual acuity assessment in children. Those with recorded VA had visual impairment. This could explain the deteriorating effect of congenital eye/adnexa defects on VA. In this study Congenital glaucoma was the second commonest type of congenital malformation seen in this study it accounted for 10 (12.8%).

This was contrary to the study by Adekoya et al. (9) and Eballe et al. (11) where congenital glaucoma was 3rd commonest type of malformation seen. The average age of diagnosed congenital diagnosis in this study was 11 months this was a little high than average months reported by Adekoya et al. (9). Congenital glaucoma was diagnosed in 60% of cases within one year after birth in this study. This percentage was less than previous studies from other African countries (11, 19, 20, 21) and Lyon in France (17) in which the diagnosis was made in 73%-82% of cases within 1 year after birth and 80% before one month old respectively. The delay in diagnosis of congenital glaucoma in African might be because of lack of knowledge about the signs of the condition among the parents and caregivers. In our study, it was observed that mothers with ages between 21 and 25 years had more babies with congenital ocular malformations, this was in agreement with Dutta and Bhattacharjee (22) who reported maternal age of 24 years - 29 years for congenital cataract in India but difference from a study in northern Nigeria by Onankpa and Adamu (23) who reported majority of congenital malformation in maternal age of below 20 years and above 35 years. However previous study by Nishimura (24) showed no statistically significant association between birth maternal age and congenital ocular malformation.

## CONCLUSION

Congenital ptosis and glaucoma were the common types of congenital eye/adnexa defects seen in our environment. These defects were important causes of visual impairment and blindness. Health education on neonatal screening and examination, early presentation and management options is an important tool that can raise awareness and increase early hospital presentation.

**Conflicts of interest:** No conflicts of interest declared.

## REFERENCES

1. Brian PB, Elias IT. Congenital malformation of the Eye. In; William T editor. Duane's Ophthalmology, (6th edn). Philadelphia: Lippincott William & Wilkins (Chapter 40). 2006
2. Campbell H, Holmes E, MacDonald S, et al: A capture-recapture model to estimate prevalence of children born in Scotland with developmental eye defects. *J Cancer Epidemiol Prev.* 2002; 7(1):21–8
3. Morrison D, FitzPatrick D, Hanson I, K Williamson, V van Heyningen, B Fleck, I Jones, J Chalmers, H Campbell. National study of microphthalmia, anophthalmia, and coloboma (MAC) in Scotland: investigation of genetic aetiology. *J Med Genet.* 2002; 39(1):16–22
4. Hornby SJ, Gilbert CE, Rahi JK, Sil AK, Xiao Y, Dandona L, Foster A. Regional variation in blindness in children due to microphthalmos, anophthalmos and coloboma. *Ophthalmic Epidemiol.* 2000; 7(2):127–38
5. Busby A, Dolk H, Collin R, et al: Compiling a national register of babies born with anophthalmia/microphthalmia in England 1988–94. *Arch Dis Child Fetal Neonatal Ed.* 1998; 79(3):168–73
6. Bermejo E, Martinez-Frias ML: Congenital eye malformations: clinical- epidemiological analysis of 1,124,654 consecutive births in Spain. *Am J Med Genet.* 1998; 75(5):497–504
7. Stoll C, Alembik Y, Dott B, Roth MP: Congenital eye malformations in 212,479 consecutive births. *Ann Genet.* 1997; 40(2):122–28
8. Lawan A. Congenital eye and adnexal anomalies in Kano, a five year review. *Niger J Med.* 2008; 17(1):37–39

9. Adekoya BJ, Balogun MM, Balogun BG, Ngwu RA. Spectrum of congenital defects of the eye and its adnexial in the pediatric age group; experience at a tertiary facility in Nigeria. *Int. Ophthalmol.* Published ahead of print 18th April 2014; DOI 10.1007/s10792-014-9946-4
10. Kaimbo Wa Kaimbo D, Mwilambwe Wa Mwilambwe A, Kayembe DL, Leys A, Missoten L. Congenital malformations of the eyeball and its appendices in Zaire. *Bull Soc Belge Ophthalmol.* 1994;254:165-170
11. Eballe AO, Ellong A, Koki G, Nanfack NC, Dohvoma VA, Mvogo CE. Eye malformations in Cameroonian children: a clinical survey. *Clin. Ophthalmol.* 2012; 2012(6):1607–1611
12. Forrester MB, Merz RD. Descriptive epidemiology of anophthalmia and microphthalmia, Hawaii, 1986–2001. *Birth Defects Res A Clin Mol Teratol.* 2006; 76(3):187–192
13. Zhu J, Wang Y, Zhou G, Liang J, Dai L. A descriptive epidemiological investigation of anophthalmos and microphthalmos in China during 1988–1992. *Zhonghua Yan Ke Za Zhi.* 2000; 36(2):141–144
14. Bodunde OT, Ajibode HA. Congenital eye diseases at Olabisi Onabanjo University Teaching Hospital, Sagamu, Nigeria. *Niger J Med.* 2006; 15(3):291–294
15. Chuka-Okosa CM, Magulike NO, Onyekonwu GC. Congenital eye anomalies in Enugu, South-Eastern Nigeria. *West Afr J Med.* 2005; 24(2):112–114
16. Papadopoulos M, Cable N, Rahi J, Khaw PT. The British Infantile and Childhood Glaucoma (BIG) Eye Study. *Invest Ophthalmol Vis Sci.* 2007; 48(9):4100–4106
17. Zech JC, Ravault M. Traitement chirurgical du glaucome congenital. *J Fr Ophthalmol.* 1994;1: 57-59
18. Detry-Morel M, Feron EM. La trabeculectomie dans le traitement du glaucome congenital: experience retrospective a moyen et a long terme [Trabeculectomy in the treatment of congenital glaucoma: retrospective experience in the medium and long term]. *Bull Soc Belge Ophthalmol.* 1997;262:143-151
19. Tchabi S, Sounouvou I, Yehouessi L, Doutetien C, Bassabi SK. Le glaucome congenital au CNHU de Cotonou: a propose de 27 cas (Congenital glaucoma at CNHU, Cotonou: a series of 27 cases). *Mali Med.* 2007;22:14-17
20. Safede K, Koffi KV, Kouassi FX, et al. Glaucome congenital: aspects cliniques et therapeutiques (Congenital glaucoma: clinical and therapeutic aspects). *Med Afr Noire.* 1999;46:264-267
21. Nacef L, Daghfous F, Marrakchi S. Le glaucome congenital en Tunisie. Profilepidemiologique, aspects cliniques et resultats therapeutiques (Congenital glaucoma in Tunisia. Epidemiological profile, clinical aspects and therapeutic results). *Ophthalmologie.* 1994;8:28-32
22. Dutta L C, Bhattacharjee H. Influence of birth rank and parental age on congenital and colobomatous defects. *Indian J Ophthalmol* 1984;32:81-84
23. Onankpa BO, Adamu A. Pattern and outcome of gross congenital malformations at birth amongst newborns admitted to a tertiary hospital in northern Nigeria. *Niger J Paed* 2014; 41 (4): 337–340
24. Nishimura H. Congenital Malformation. Ed. Frammer CF, ME Kkuick VA. *Excerpta Medica.* Amsterdam Princeton, 1969, 275-281

Table 1: Socio- demographics and laterality of the patients

Variables	N	(78)	%
Age range 1 day - 16years			
<b>Age of the patient at the presentation</b>			
Within 1year	33		42.3
1 year	45		57.7
<b>Sex</b>			
Male	39		50
Female	39		50
<b>Occupation of the patients</b>			
Dependant (child)	50		64.1
Student	23		29.5
House wife	5		6.4
<b>Laterality</b>			
Both eye	54		69.2
Right eye	17		21.8
Left eye	7		9

Table 2: Visual Acuity of the patients

Visual Acuity (VA)	Right eye frequency	Left eye frequency
PL	18	11
HM	18	16
CF	10	19
6/60	7	6
NPL	7	7
Not asses	18	19
Total	78	78

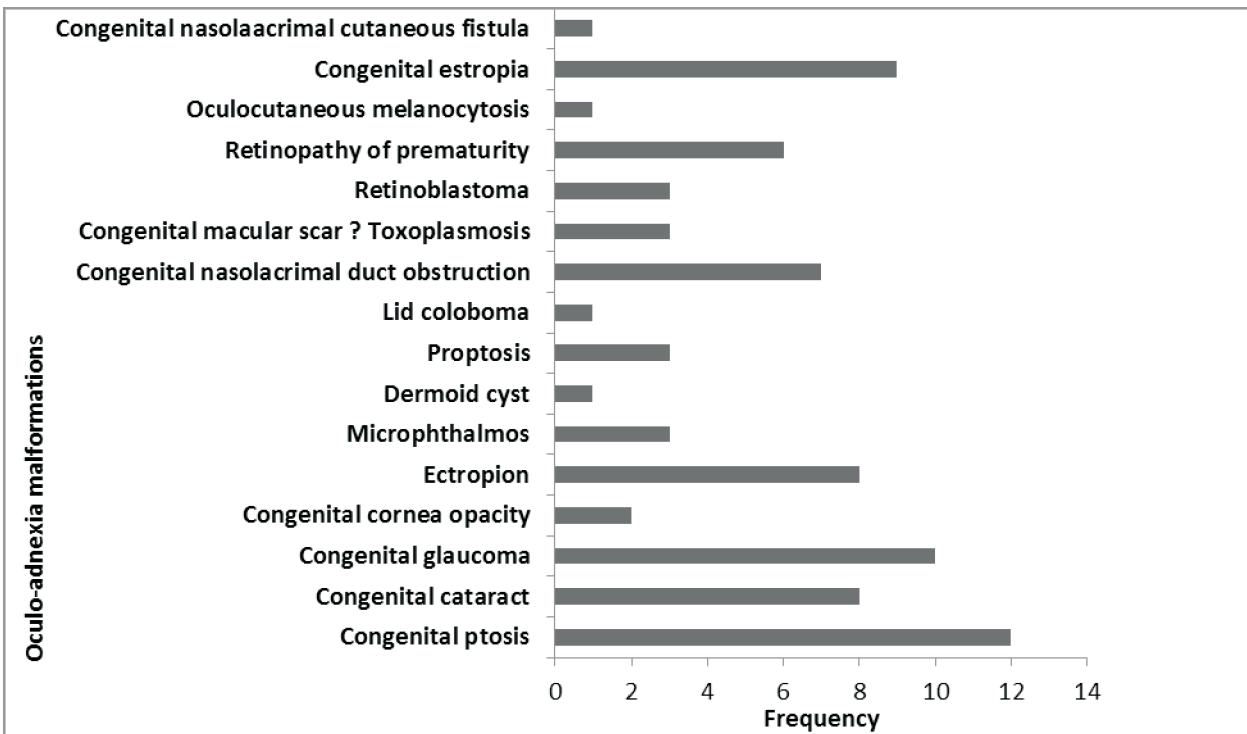


Figure 1: Types of oculo-adnexia malformations presented by the cohort (patients)






Figure 2: Presenting complaints of the cohort (patients)

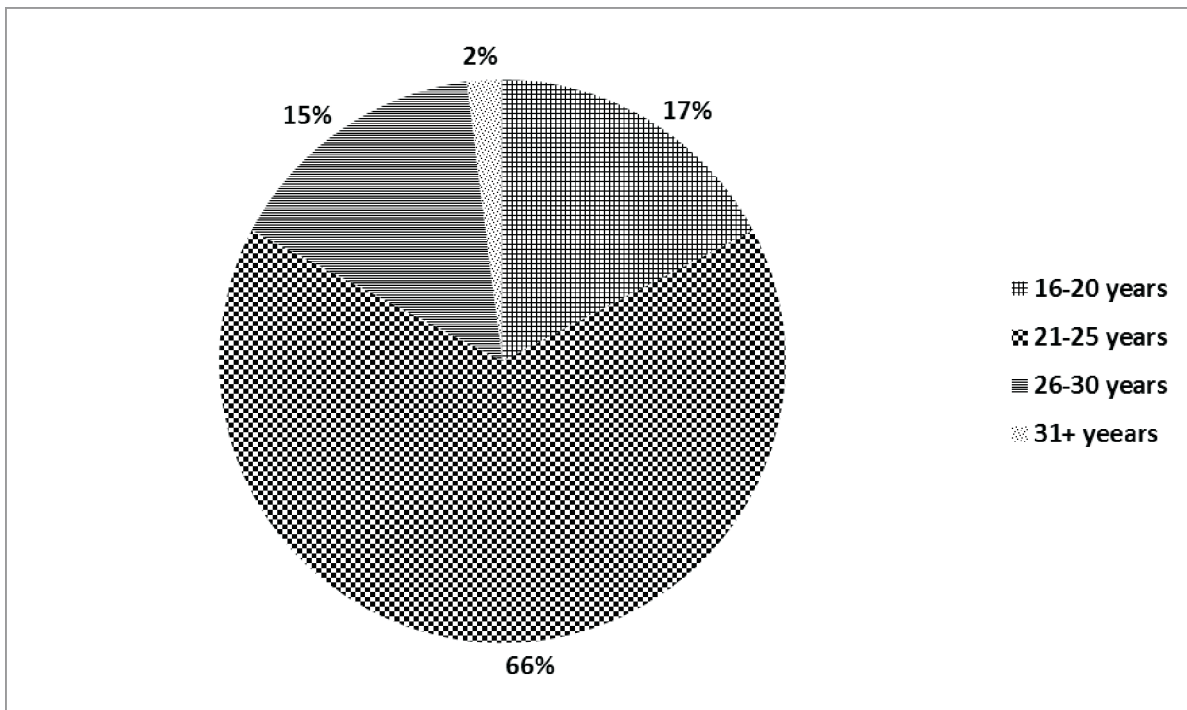


Figure 3: Distribution of maternal ages at birth of the cohort (patients)