

# PROPELLER FLAP: A FEASIBLE FLAP FOR DISTAL THIRD OF LEG DEFECTS – TWO CASES DONE AT THE PLASTIC SURGERY UNIT OF THE GREATER ACCRA REGIONAL HOSPITAL

Asiedu CK<sup>1</sup>; Ngissah RK<sup>2</sup>; Asamani D<sup>1</sup>; Awere-Kyere L<sup>2</sup>

<sup>1</sup>Plastic Surgery and Burns Unit; <sup>2</sup>Trauma and Orthopaedics Unit, Greater Accra Regional Hospital  
Accra, Ghana

## Abstract

**Introduction:** The traditional way of reconstructing soft tissue defects of the lower limb utilized muscle flaps as the ‘gold standard’ for Gustillo Anderson Grade III B fractures of the upper and middle thirds of the leg. Defects of the lower third of the leg are usually reconstructed with free flaps because of paucity and decreased reach of muscles. In resource constrained environments where free flaps are not routine with high failure rates, fasciocutaneous flaps are the only option left. We present our experience with the novel pedicled propeller perforator flaps for reconstruction of soft tissue defects in the lower limb.

**Case Presentation:** Between June and October 2020, 2 consecutive patients - a 34-year-old male and a 51-year-old female, were referred for cover for their distal leg defects from the Orthopaedics and trauma Unit. All patients were operated on under spinal anaesthesia.

Perforators from posterior tibial and peroneal arteries respectively, were identified pre-operatively with hand-held doppler and the propeller-pattern skin paddle was designed around the perforator closest to defect.

After elevation of flaps and skeletonization of perforators, they were then rotated (180 degrees) and inset into defects. Case 1 had whole flap (104 cm<sup>2</sup>) surviving with only minor marginal epidemolysis at tip whilst the second flap (58.5cm<sup>2</sup>) had necrosis of only the business end of the flap but subsequently healed by secondary intention after serial dressings. Both had secondary defects proximally after the rotation, which were skin grafted with 100% take.

**Conclusion:** Propeller flap in our experience, is a feasible versatile option for reconstruction of soft tissue defects in the distal third of the leg.

**Keywords:** propeller flap, perforators, distal third of leg

## Introduction

To the plastic and orthopaedic surgeon management of soft tissue loss of the distal third of the leg can be very challenging especially to those in Low- and Middle-Income countries where equipment for complex free flap reconstruction are largely unavailable. The subcutaneous nature of the tibia with the concomitant poor vascularity and attendant paucity of the muscle cover in lower third of the leg results in bone exposure whenever fractures occur in that part of the body.

The traditional way of reconstructing soft tissue defects of the lower limb utilized muscle flaps has the ‘gold standard’ for Gustillo Anderson Grade III B fractures of the proximal two-thirds of the leg. Defects in the distal third of the leg (“no man’s land”) are elsewhere reconstructed with free flaps which require finesse in microsurgery and availability of operating microscope. In resource constraint environments such as ours, free flaps are done only occasionally and because of that failure rates are high and so is not a viable option for such defects. Currently in our environment, reverse sural flap (unreliable), cross leg flaps (cumbersome) and

local distally based transposition fasciocutaneous flaps – which maybe in the trauma zone and hence unreliable or unavailable have been used. The use of these fasciocutaneous flaps minimize morbidity from muscle inclusion into the flap. The perforator concept by Saint-Cyr et al.<sup>1</sup>(2009) popularized the use of free and pedicled perforator flaps based on perforators which are tiny connecting vessels from major source vessels to the skin and other intervening structures. The propeller flap is a perforator flap which has been raised and rotated 90 or 180 degrees into a defect for cover.

## Cases Presentation

Two patients with distal third of leg defects were referred to the Plastic Surgery and Burns Unit of the Greater Accra Regional Hospital between June and October 2020, having been seen earlier by the Orthopaedics and Trauma Unit of the same hospital. Case 1 was a 34-year-old man, two weeks post fall from a height with Gustillo 3B opened fracture just above the medial malleolus (figure 1). Figure 2 and 3 shows intraoperative pictures and figure 5, post-operative picture with flap in place and consolidated skin graft proximally. Case 2, a 51-year-old woman with chronic osteomyelitis and ankylosed ankle joint who had sequestrectomy with non-healing ulcer in the area of the lateral malleolus. Perforators from posterior tibial and peroneal arteries respectively, were identified pre-operatively with a 4-Hz hand-held doppler, and a propeller flap was designed around the identified

**Corresponding Author: Dr. Charles K. Asiedu**

Plastic Surgery and Burns Unit, Greater Accra Regional Hospital, P. O. Box GP 3194, Accra, Ghana

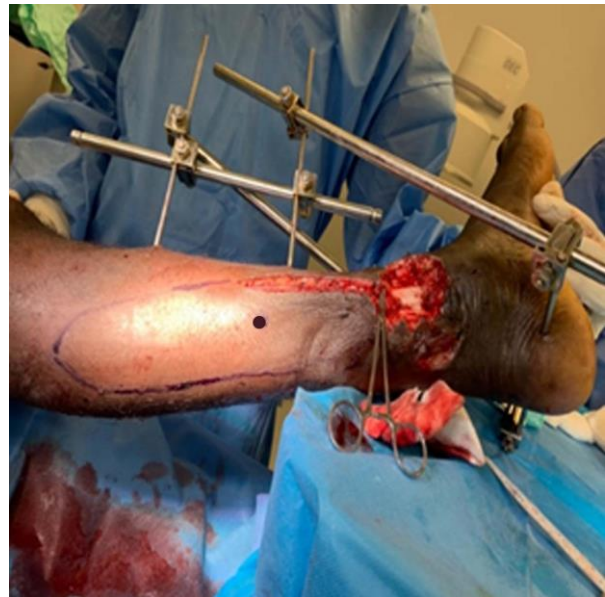**Email Address:** cakseries@yahoo.com

**Conflict of Interest:** None Declared

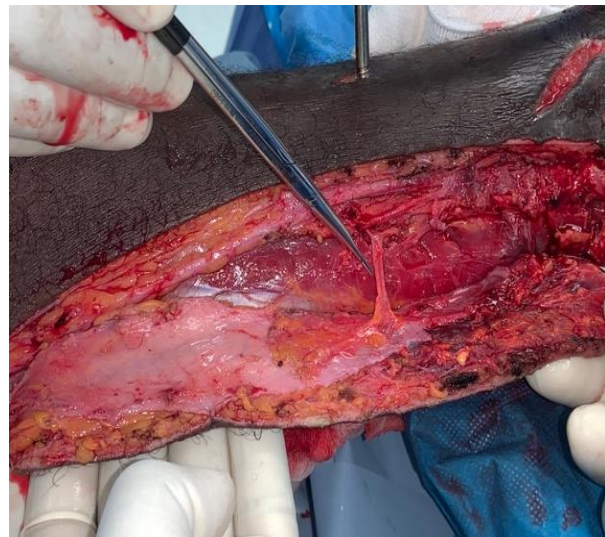perforator closest to defect. Intra-operatively the flap was designed with the length of the proximal limb (distance from perforator to the proximal tip) being equal to the remaining length of the of the flap plus the transverse length of the defect. Then, under spinal anaesthesia and tourniquet, an exploratory incision (Fig. 2) was made on one side of designed flaps down into subfascial plane to look for perforators. After identifying perforator of the right size in the right location (closest to defect), the whole marked flap was raised, care being taken to preserve the skeletonized perforator. Flaps were then rotated (180 degrees) and inset into defects care been taken not to put undue traction on pedicle. Table 1 gives the summary of the salient aspects of the two cases and the complications seen post-op.

**Table 1 – Intra-operative findings and post-operative complications**

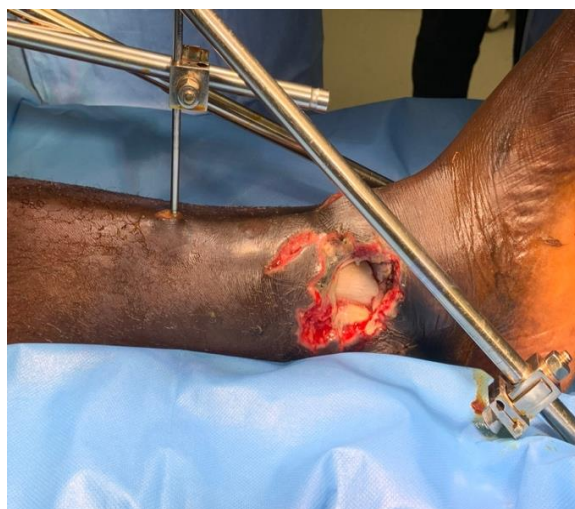	Case 1	Case 2
Size of defect	4.5 x 5 cm	3 x 3 cm
Location of defect	Medial malleolus	Lateral malleolus
Perforator source	Posterior tibial artery	Peroneal artery
Perforator location from proximal margin of defect	5cm	4.5 cm
Type of perforator	musculocutaneous	musculocutaneous
Total Flap size/Area	16 x 6.5(104cm <sup>2</sup> )	13 x 4.5(58.5cm <sup>2</sup> )
Proximal limb length	10	8 cm
Management of Secondary defect	Split Skin Grafting	Split Skin Grafting
Complications	Marginal epidermiolysis	Congestion, Wound infection, tip necrosis



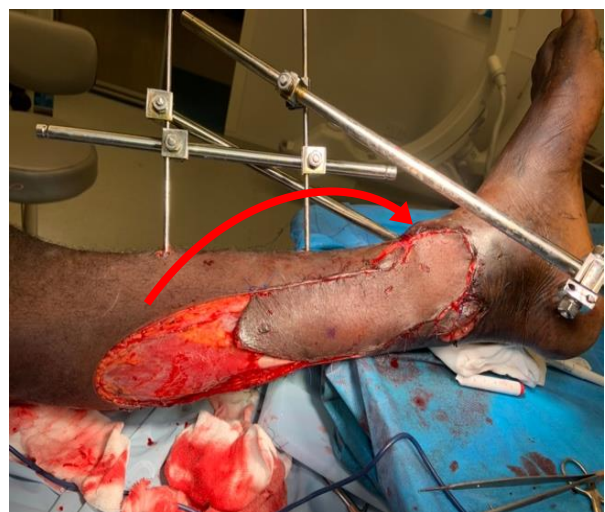**Figure 2: Flap marked out with pivot point (dotted)**



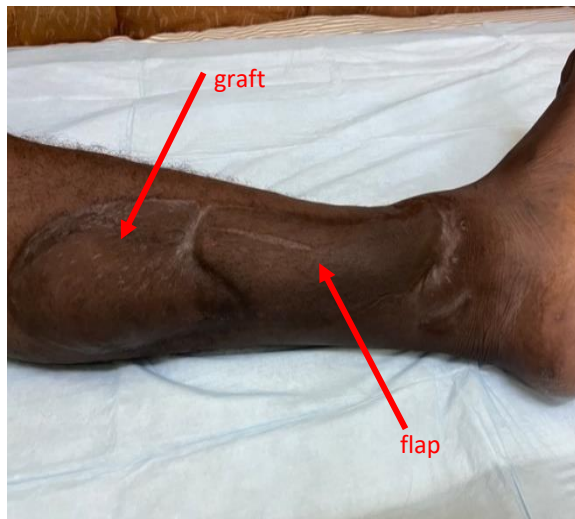
**Figure 3: Flap raised with perforator skeletonized**



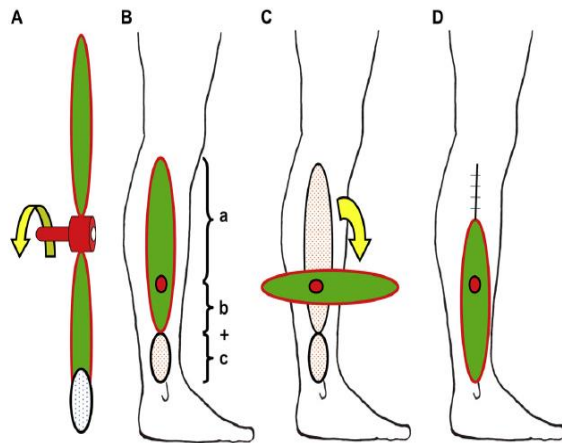
**Figure 1: Open tibial fracture distal third of leg**



**Figure 4: Flap inset after 180° rotation, shown with arrow**



**Figure 5: 2-years post operative with flap and Graft consolidated**



**Figure 6: Pictorial illustration of propeller flap concept (curled from Dr Teo's article)<sup>8</sup>**

## Discussion

The propeller perforator flap is useful addition to the armamentarium of plastic surgeons, especially in the local reconstruction of the lower leg. Arguably, the era of perforator flaps begun in 1989 when Koshima and Soeda published the survival of paraumbilical skin and subcutaneous fat based on islanded muscular perforator, used to reconstruct a groin and a tongue defect post tumour excision.<sup>2</sup>

It was Hyakusoku and colleagues who advanced the concept of propeller flaps with their raising of adipocutaneous flap based on a subcutaneous perforator, in which the flap was designed like the blades of the propeller of an aeroplane.<sup>3</sup> The propeller flap so described was made of two portions with the pedicle or perforator as the pivot point. The two portions of the skin paddle can rotate around the pedicle, like the propeller blades around the hub, from 90 to 180 degrees as required, taking care not to kink the pedicle. Hallock defines a perforator as any vessel that enters the

superficial plane through a defined opening in the deep fascia.<sup>4</sup> Perforators on their way from source vessels to supply superficial structures including skin may travel directly (Direct perforators) made traverse different structures (In direct perforators).

The in direct perforators may either pass through muscle or the intermuscular septum and are named accordingly, i.e., muscular and septal perforators respectively. The "Gent" consensus meeting on perforator vessels and perforator flaps grouped perforators into 5 different types.<sup>5</sup> With the increasing popularity of the propeller flap concept the first consensus meeting was held in Tokyo in 2009, it was classified based on:

1. the nourishing vessel (3 types: subcutaneous pedicled-, perforator pedicled - and supercharged propeller flap)
2. the degrees of skin island rotation (90 to 180 degrees) and,
3. when possible, the artery of origin of the perforator.<sup>6</sup>

Other factors used in their classification is the shape of flap and position of nourishing vessel.<sup>6</sup> In 2020, Pignatti et al. added two new subtypes based on the nourishing vessel in their comprehensive classification of propeller flaps (Table 2).<sup>7</sup> These are the muscle and chimeric propeller flap. At the inception, propeller flap was applied only to a skin island vascularized only by an isolated perforator, but with this new classification, the term has been expanded to include other tissues like muscle which can also be raised in a propeller fashion and rotated into defects.

A detailed knowledge of this vascular anatomy of skin perforators is required for successful flap elevation. In the lower limbs, the popliteal artery, which is a continuation of the common femoral artery after it pierces the adductor hiatus, gives of a number of branches around the knee joint and then trifurcates into – peroneal, anterior and posterior tibia arteries which supply the leg and foot.

They give off perforators to the skin along their course. At the ankle, the anterior tibial artery becomes the dorsalis pedis artery which, along with the terminal branches of the posterior tibial and peroneal arteries, supplies the ankle and foot. Saint Cyr et al. have identified 93 perforators from 21 vascular territories that supply the integument of the extremities with an average diameter and area supplied by a single perforator been approximately 0.7 mm and 47 cm<sup>2</sup> respectively.<sup>1</sup>

Perforator flaps and by extension propeller flaps can be raised based on all these identified perforators. The advantages include a much quicker procedure which can be performed with basic instrumentation.<sup>8</sup> This comes in handy to any plastic surgeon who may be working alone or in resource constraint areas without access to sophisticated microsurgical equipment.

**Table 2 – New comprehensive classification of propeller flaps**

Flap type	Pedicle	Rotation	Vessel of origin	Dissection technique	Details	Examples
1.Subcutaneous pedicled propeller flap	Random (perforator not visualized)	Up to 90 degrees	Not known	Macroscopic	The first defined as propeller	Elbow in burns (first described) Lotus flap1
2.Perforator pedicled propeller flap	Dissected perforator	Up to 180 degrees	Plausible or visualized	Magnification needed	The one mostly used	Propellers of the leg
2a. Supercharged perforator pedicled propeller flap	Dissected perforator + extra vein or artery	Up to 180 degrees	Known (constant)/visualized	Magnification needed + Microsurgical anastomosis	In case of congestion (venous anastomosis) or for larger flaps (artery / vein_)	Trunk, limbs
3. Axial pedicled propeller flaps	Known axial vessel	Up to 180 degrees	Known (constant)/visualized	Magnification needed	Evolution of axial flaps	Lingual artery propeller
4. Muscle propeller flaps	Main vessel or branch to the muscle	Up to 180 degrees	Known (constant)/visualized	Magnification advisable	Evolution of muscular flaps	Trapezius muscle propeller
5. Chimeric propeller flaps	Vessel to the first tissue + dissected perforator	180 degrees + 180 degrees	Known + visualized	Magnification needed	Bone or muscle flap + perforator pedicled propeller	Razor flap

### *Design of the flap*

Dr Tiew Chong Teo, an authority on propeller flaps who wrote the paper “The Propeller Flap Concept.” who as at the year 2010 had performed 130 propeller flap surgeries with only 3 cases of total flap loss, describes explicitly the design and raising of propeller flaps in his article.<sup>8</sup> The process starts with locating the best perforator in the vicinity of the defect with a handheld doppler and provisionally design the flap about the perforator as pivot. The distance between the perforator and the distal limit of the defect is measured (In Fig. 6 =b + c). This distance is then projected proximal to the perforator to mark the proximal extent of the flap (In Fig. 6= a; a=b+c). According to Dr Teo, 1cm and 0.5cm may be added to length and width to cover for retraction and avoid tension on closure.<sup>8</sup> It is also recommended not to exceed proximal limb length of 15cm to decrease incidence of tip necrosis.

### *Some hints on Raising the Propeller Flap*

The flaps can be raised under tourniquet exsanguination but retaining some blood in the perforator vessels to allow for easier identification during exploration. The perforators in the vicinity are located through an initial exploratory incision, which can be suprafascial or subfascial.<sup>8</sup> Beginners are advised to use the latter approach which is easier and safer in terms of vessel visualization. Dr Teo advises avoiding perforators encased in scar tissue because of difficulty of dissection and also perforators at a distance from defect to avoid unnecessarily long flaps which are prone to tip necrosis. If the final pedicle chosen may differ from the one located by pre-operative doppler then the flap should be redesigned using it as pivot point. The chosen perforator should be carefully prepared and

cleared of all muscular side branches for at least 2 cm to decrease kinking on rotation.<sup>8</sup> The relatively low-pressure venae comitantes are more susceptible to extrinsic compression during flap rotation. Dr Teo recommends release of tourniquet before rotation and allowing flap some time to perfuse and relax any spasm of vessel. The rotation direction which gives the least degrees of rotation is chosen, with a maximum allowable rotation of 180 degrees.<sup>3,8</sup>

Once the preferred rotation direction is determined and carried out, flap is initially secured with some stay sutures on either side of the transverse axis of the pedicle to ensure no traction on it during inset. The inset can be done with a drain underneath flap based on judgement of surgeon.

The donor defect can be closed primarily if there is no excessive tension or otherwise skin grafted in other to avoid tourniquet effect. In summary the steps for raising a propeller flap are:

1. Pre-operative evaluation of perforators
2. Identification of perforators and selection
3. Designing the flap
4. Flap elevation
5. Dissection of perforator
6. Rotation/ Insetting

### *Indications / reach*

Apart from the lower limbs, it can be used anywhere on the body as long as a near-by perforator is identified, and surrounding anatomy allows for its design. It can be applied for defects on any part of the leg but especially useful for distal third of leg and ankle defects. Can reach as far as defects of the lateral calcaneus.<sup>8</sup>

### Complications

Propeller flaps share same complications as other flaps. Venous congestion is the most common complication because of veins are at more risk of kinking on rotation.<sup>9</sup> This may also be due to inadequate flow in perforator vessel because of poor vessel selection or inadequate dissection. Partial necrosis occurs in 5% of cases and is usually restricted to skin.<sup>10</sup> This can be managed by debridement and skin grafting or allowing to heal by secondary intention. Total necrosis is rare but can occur in inexperienced hands.<sup>9</sup>

### Conclusions

Propeller flap surgery is a feasible alternative to free flap surgery especially useful in the armamentarium of a plastic surgeon in the developing world. It is straight forward with a low learning curve, quick to do and allows for reconstruction with local tissue with minimal donor site morbidity when traditional flaps are not an option. Finally, it presents several advantages over traditional pedicled/transposition flaps. We recommend that since on the legs it is a fasciocutaneous flap and it's a well-known fact that these fasciocutaneous flaps are not robust for infected beds, it should be used with caution in the setting of infection.

### References

1. Saint-Cyr M, Wong C, Schaverien M, Mojallal A, Rohrich RJ. The perforasome theory: vascular anatomy and clinical implications. *Plast Reconstr Surg.* 2009;124:1529-1544.
2. Koshima I, Soeda S. Inferior epigastric artery skin flaps without rectus abdominis muscle. *Br J Plast Surg.* 1989;42:645-648.
3. Hyakusoku H, Yamamoto T, Fumiiri M. The propeller flap method. *Br J Plast Surg.* 1991;44:53-54.
4. Hallock GG. Direct and indirect perforator flaps: the history and the controversy. *Plast Reconstr Surg.* 2003;111:855-865.
5. Blondeel PN, Van Landuyt KH, Monstrey SJ, Hamdi M, Matton GE et al. The "Gent" consensus on perforator flap terminology: preliminary definitions. *Plast Reconstr Surg.* 2003; 112:1378-1383.
6. Pignatti M, Ogawa R, Hallock GG, Mateev M, Georgescu AV, et al. The "Tokyo" consensus on propeller flaps. *Plast Reconstr Surg.* 2011; 127:716-722.
7. Pignatti M, Ogawa R, Mateev M, Georgescu AV, Balakrishnan G et al. Our definition of Propeller Flaps and their classification. *Semin Plast Surg.* 2020; 34:139-144.
8. Teo TC. The propeller flap concept. *Clin Plast Surg.* 2010; 37:615-626.
9. D'Arpa S, Toia F, Pirrello R, Moschella F, Cordova A. Propeller flaps: a review of indications, technique, and results. *Biomed Res Int.* 2014; 2014:1-7
10. S. D'Arpa, A. Cordova, M. Pignatti, and F. Moschella, "Freestyle pedicled perforator flaps: safety, prevention of complications, and management based on 85 consecutive cases," *Plast Reconstr Surg.* 2011;128: 892-906.