

CASE REPORTS

TRAUMATIC RUPTURE OF DERMOID CYST IN EARLY PREGNANCY: DIAGNOSIS AND MANAGEMENT IN PEKI GOVERNMENT HOSPITAL RESULTING IN A SUCCESSFUL DELIVERY AT TERM

Azanu WK^{1,4}; Appiah-Kubi A^{1,4}; Maalman RS²; Konney TO³; Amoh MY^{1,4}; Sakyi AT⁴; Agbeno EK⁵; Morhe ESK^{1,4}

¹Department of Obstetrics and Gynaecology, School of Medicine; ²Department of Basic Medical Sciences, School of Medicine, University of Health and Allied Sciences, Ho, Ghana; ³Department of Obstetrics and Gynaecology, School of Medicine and Dentistry, Kwame Nkrumah University of Science and Technology, Kumasi; ⁴Department of Obstetrics and Gynaecology, Ho Teaching Hospital, Ho, Ghana; ⁵Department of Obstetrics and Gynaecology, School of Medical Sciences, University of Cape Coast, Cape Coast

Abstract

Introduction: Dermoid cyst is the commonest germ cell tumour, constituting about 20% of adult ovarian tumours. They are mostly asymptomatic, but complications such as torsion, rupture, and malignant transformation have been reported. Only a few cases of ruptured mature cystic teratoma in early pregnancy have been described and even fewer are those in early pregnancy with the pregnancy successfully carried to term with successful delivery.

Case Presentation: We present a case of a grand multiparous woman who presented to Peki Government Hospital at 11 weeks gestation with an acute abdomen following a fall. She had been diagnosed with a dermoid cyst a week with dimensions of 20cm x15 cm before the

presentation. Ultrasound diagnosis of a possible rupture of the cyst was made on admission. Right oophorectomy was done at laparotomy. She had progesterone support for the succeeding 4 weeks and the pregnancy was successfully carried to term with good outcomes at delivery for both mother and baby. The APGAR score for the baby at 1minute and 5minute after birth were 7/10 and 8/10 respectively.

Conclusion: Traumatic rupture of dermoid cyst should be considered as a differential diagnosis in women presenting with acute abdomen in early pregnancy. Laparotomy with abdominal lavage is a viable management option in a low-resource setting.

Keywords: Dermoid cystic, Traumatic Rupture, Gestation, Delivery, Progesterone, laparotomy

Introduction

Dermoid cyst, also referred to as mature cystic teratoma, is the commonest germ cell tumour¹. It constitutes about 20 % of adult ovarian tumours¹ with no particular racial predilection². Embryologically, dermoid cysts develop along the lines of fusion with trapped ectodermal elements hence the macroscopic presence of hair, nails, and teeth². They are usually unilateral, but bilateral cysts have also been described²

Dermoid cysts are usually large at the time of diagnosis and often detected incidentally at routine pelvic examination³. They can be associated with various complications such as torsion (16% of ovarian teratomas), rupture (1%–4%), malignant transformation (1%-2%), infection (1%), and autoimmune haemolytic anaemia (<1%)⁴. The occurrence of rupture of dermoid cysts is between 0.2 to 2.5%⁵. The main cause of rupture is idiopathic⁵. Ruptured dermoid cysts may also be due

to torsion in conjunction with pregnancy because of changes to the position of the ovaries and increased vascularity⁵. However, on very rare occasions, blunt abdominal trauma, like in this case, can be the cause of a ruptured mature cystic teratoma of the ovary⁶. In this case report, the occurrence of the rupture in early pregnancy further makes it very important because its management involves the preservation of the life of the mother and pregnancy. We, present this case of traumatic rupture of a dermoid cyst in the first trimester of pregnancy and successful management of the pregnancy to term delivery of a live baby in a resource-deprived setting.

Case Presentation

A 36-year-old G6P5AA, presented at Peki Government Hospital with a grossly enlarged abdomen, 3 months amenorrhoea, and a positive pregnancy test at a booking visit. A routine ultrasound scan diagnosed a dermoid cyst measuring 20cm x 13 cm coexisting with an 11-week gestation. Five days later she was rushed to the hospital complaining of severe abdominal pain after having tripped and fallen on her abdomen at her farm. On further enquiry, she was not bleeding per vaginam and was not feeling dizzy. On general physical

Corresponding Author: Dr. Adu Appiah-Kubi
Department of Obstetrics and Gynaecology, School of Medicine, University of Health and Allied Sciences, PMB 31, Ho, Ghana.
Email Address: aappiah@uhas.edu.gh
Conflict of Interest: None Declared

examination, she was in pain, not pale, she was afebrile and anicteric. Her pulse rate was 90 beats per minute and her blood pressure, 110/60mmHg. Her abdomen was full, generally tender with positive shifting dullness.

An urgent ultrasound scan reported findings that were suggestive of a ruptured right ovarian cyst with an intact intra-uterine gestation at 12 weeks. Fluid was noted in the Pouch of Douglas. These findings were explained to her and she was counselled and prepared for an emergency laparotomy. Intraoperative findings of the laparotomy through a midline incision were consistent with a ruptured right ovarian dermoid cyst. There was approximately 300mls of brownish fluid in the peritoneal cavity as well as hair strands and multiple whitish fatty material deposited on the bowel and peritoneum. The uterus was bulky and was about 12 weeks in size. A right oophorectomy was performed. There was minimal handling of the uterus during the surgery. The findings are described in Figure 1-4 below.

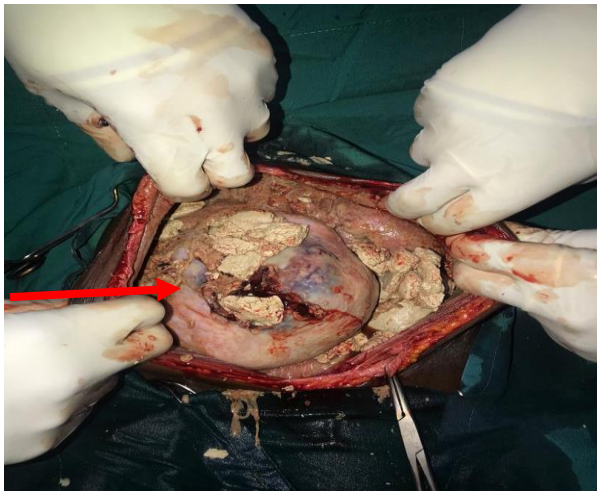


Figure 1: Ruptured ovarian cyst with multiple whitish fatty deposits scattered all over the peritoneum. (ruptured dermoid cyst indicated with arrow)

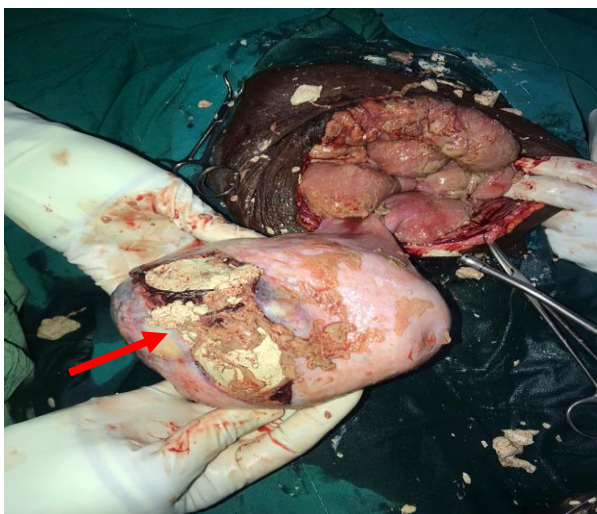


Figure 2: ruptured dermoid cyst being removed. (ruptured dermoid cyst indicated with arrow)

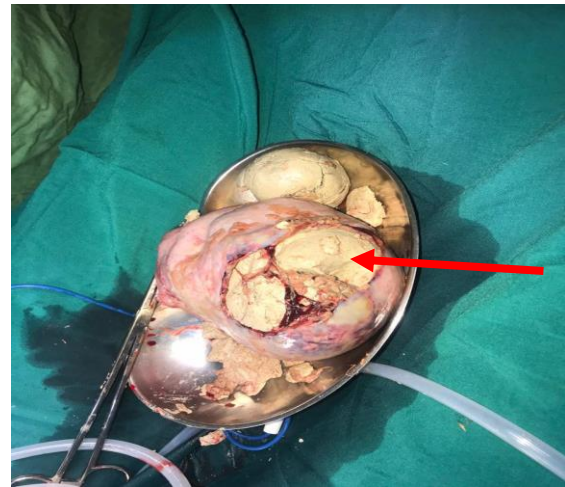

Figure 3: The dermoid cyst removed with the right ovary. (ruptured dermoid cyst indicated with arrow)

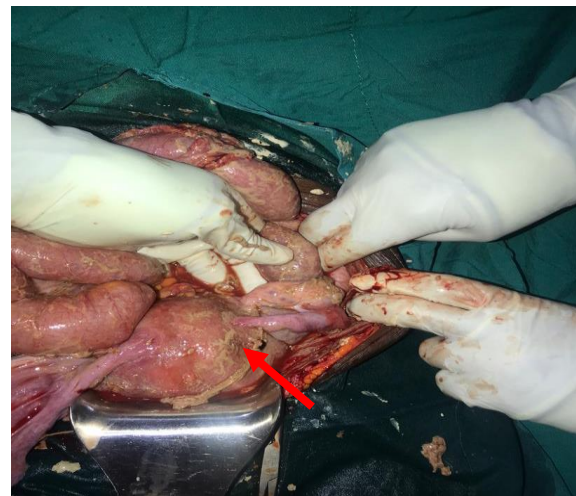


Figure 4: Bulky uterus, about 12 weeks in size. (bulky uterus indicated with arrow)

The abdomen was washed with about 3L of warm normal saline until it appeared clean. The specimen was sent for histology, findings of which revealed sections from the ovary showing multiloculated cystic ovary, lined by epidermal tissue and filled with keratin flakes, intestinal tissue, mature adipose tissue, smooth muscle, and bony tissue. No undifferentiated tissue was seen. The features were consistent with mature cystic teratoma. The patient was put on progesterone support (cyclogest® vaginal pessaries 400mg daily) for four weeks. Her subsequent care was uneventful through her regular antenatal visits until she went into labour at term. She later had an emergency Caesarean section on account of fetal distress. The outcome of this was the delivery of a live male baby weighing 2.9kg with good Apgar scores of 7/10 and 8/10 at 1 minute and 5 minutes after delivery respectively.

Discussion

Mature cystic teratomas are characterized by adult ectodermal, mesodermal, and endodermal tissue and

they may have skin, hair, teeth, fat and muscle, and in some cases thyroid and brain tissue⁷. The term dermoid cyst usually describes a mature cystic teratoma that contains primarily ectodermal tissue⁷. Although ovarian cysts have been known to undergo spontaneous rupture, external factors such as trauma, pelvic examination, coitus, and childbirth have also been documented as causes of rupture⁸. In our case, the suspicion of cyst rupture following the trauma was high due to the previous ultrasound diagnosis of a large dermoid cyst. The tenderness on palpation with the positive fluid thrill heightened our suspicion of a rupture. This acute presentation is one of two common presentations of ruptured dermoid cysts. The other is chronic presentation in which the patient may present with chronic granulomatous peritonitis with possible omental deposits which could be mistaken for ovarian carcinoma⁴. Collection of the sebaceous contents of a ruptured dermoid cyst could lead to peritonitis and fever⁸. Our patient did not develop a fever probably because she was managed early and had a thorough abdominal lavage. Blunt injury to other abdominal viscera could have been considered as a cause of her symptoms but the findings of the repeat ultrasound were suggestive of a ruptured ovarian cyst. More advanced radiological assessment could have been considered but they are not available in our facility. CT scans are thought of as being relatively unsafe in pregnancy due to exposure of the fetus to radiation. MRI although relatively safer to use in pregnancy, was not available in our facility.

It is advisable that any surgical intervention in the first trimester should be avoided, if possible, because of the high rate of spontaneous abortion⁹. The optimum time for surgical intervention is 16-18 weeks of gestation⁹ but we had to perform the laparotomy at 12 weeks because of the acute presentation. Conservative management was not possible. Fortunately, despite the risk of spontaneous abortion, she was successfully managed on progesterone for 4 weeks. Her recovery and antenatal care were uneventful after the laparotomy. Although this patient reported early enough after the rupture of the ovarian cyst, laparoscopic management with its benefit of being minimally invasive was not an option because that service was not available. Oophorectomy should be the standard operation in postmenopausal women and perimenopausal women with multiple cysts in the same ovary or with large teratoma where there is not much ovarian tissue to conserve¹⁰. Oophorectomy was done because of the intraoperative finding of rupture of the dermoid cyst with content spillage all over the abdomen. Cystectomy would have been considered if not for the rupture. A thorough lavage with warm saline was performed to minimise the risk of chemical peritonitis as this practice is known to reduce this risk. The risk of chemical peritonitis after contents spillage is extremely rare and can certainly be overcome with thorough peritoneal lavage using warm fluid.

Conclusions

Overall, we have highlighted the point that, although uncommon, in a pregnant woman diagnosed with a dermoid cyst who presents with acute abdomen following a fall, traumatic rupture of the dermoid cyst should be considered as a differential diagnosis. Prompt diagnosis, timely laparotomy, progesterone support, and continuous monitoring ensured that the pregnancy was successfully carried to term with a favourable outcome. Laparotomy remains an option for managing ruptured dermoid cysts with acute abdomen in a low-resource setting like ours.

Authors' Contribution

Azanu WK – conceptualization, data curation, investigation, resources, validation, writing original draft, review and editing. **Appiah-Kubi A** – conceptualization, data curation, investigation, resources, validation, writing original draft, review and editing. **Maalman RS** – writing review and editing. **Konney TO** – writing - review and editing. **Amoh MY**: writing review and editing. **Sakyi AT** – writing - review and editing. **Agbeno EK** - writing review and editing. **Morhe ESK** - writing review & editing.

Acknowledgement

Doctors, Midwives and theatre staff of Peki Government Hospital.

References

1. Bužinskienė D, Mongirdas M, Mikėnas S, Drašutienė G, Andreika L et al. Chemical peritonitis resulting from spontaneous rupture of a mature ovarian cystic teratoma: a case report. *Acta Med Litua*. 2019; 26:217-226.
2. Moin T, Ramsay B, Mckeown B, Astall E, Tapuria N. Ruptured ovarian dermoid cyst - an unusual cause for peritonitis in pregnancy: a case report. *JRSM Open*. 2020; 11:2054270417744502.
3. Chen VW, Ruiz B, Killeen JL, Coté TR, Wu XC et al. Pathology and classification of ovarian tumors. *Cancer*. 2003; 97:2631-2642.
4. Park SB, Kim JK, Kim KR, Cho KS. Imaging findings of complications and unusual manifestations of ovarian teratomas. *Radiograph*. 2008; 28:969-983.
5. Chaudhary, Himanshu; Jindal, Aditi; Sharma P. Ruptured dermoid cyst during pregnancy: a rare case report. *J Gynecol Womens Heal*. 2018;10:1-3.
6. Biwole DB, Kamla IJ, Tchuenkam LW, Nono J, Bwelle G et al. Blunt abdominal trauma ruptured ovarian dermoid cyst and chemical peritonitis. a case report and literature review. *Surg Case Rep Rev*. 2020; 1-4.
7. Sahin H, Abdullazade S, Sancı M. Mature cystic teratoma of the ovary: a cutting edge overview on imaging features. *Insights Imaging*. 2017;8:227-241.

8. Jyoti M. Accidents to ovarian cysts. *J Univers Coll Med Sci.* 2013;1:46–53.
9. Mandi D, Chandra R. Successful vaginal delivery despite a huge ovarian mucinous cystadenoma, complicating pregnancy : a case report. 2013;38:339–342.
10. Sinha A, Ewies AA. Ovarian mature cystic teratoma: challenges of Surgical management. *Obstet Gynecol Int.* 2016;2016:2390178. doi: 10.1155/2016/2390178.

