

## Images in medicine

### Erosive nappy erythema following sunitinib intake

Saoussane Kharmoum<sup>1,&</sup>, Hassan Errihani<sup>1</sup>

<sup>1</sup>Department of medical oncology, National institute of oncology, Rabat Morocco

<sup>&</sup>Corresponding author: Saoussane Kharmoum MD, Department of medical oncology, National institute of oncology, Rabat Morocco

Key words: Erosive, erythema, sunitinib, antiangiogenic drug

Received: 26/11/2012 - Accepted: 29/11/2012 - Published: 01/02/2013

**Pan African Medical Journal. 2013; 14:46. doi:10.11604/pamj.2013.14.46.2235**

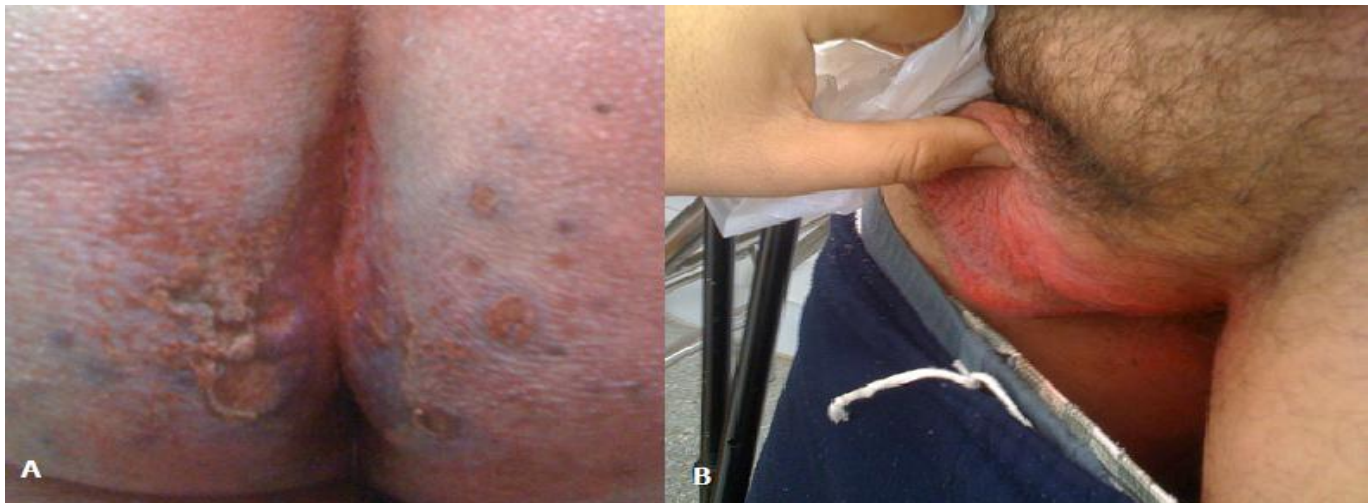
This article is available online at: <http://www.panafrican-med-journal.com/content/article/14/46/full/>

© Saoussane Kharmoum et al. The Pan African Medical Journal - ISSN 1937-8688. This is an Open Access article distributed under the terms of the Creative Commons Attribution License (<http://creativecommons.org/licenses/by/2.0>), which permits unrestricted use, distribution, and reproduction in any medium, provided the original work is properly cited.

### Image in medicine

We report on the case of a 54 years old man treating for a metastatic renal carcinoma who had experienced a dermatological toxicity referring to sunitinib intake. The antiangiogenic drug was delivered at a daily dose of 50mg for 4 weeks followed by two weeks of rest. By the second week of treatment the patient presented a nappy erythema evolving towards erosive lesions

bleeding at mild friction and extending to the perianal and scrotal area, the process fulfilled the maximal intensity at 4 weeks and improved after the discontinuation of sunitinib. The patient refused the reintroduction of the drug. No skin biopsy was developed seeing that the lesions disappeared 4 weeks later.



**Figure 1:** Erosive nappy erythema (A) and scrotal erythema (B)