

Images in clinical medicine



Congenital arteriovenous malformation (ISSVA classification for vascular anomalies)

 Subrat Narendra Samal, Snehal Subrat Samal

Corresponding author: Snehal Subrat Samal, Department of Neuro Physiotherapy, Ravi Nair Physiotherapy College, Datta Meghe Institute of Higher Education and Research, Sawangi, Meghe, Wardha, Maharashtra, India. snehalsamal11@gmail.com

Received: 25 Jul 2023 - **Accepted:** 15 Oct 2023 - **Published:** 12 Dec 2023

Keywords: Haemangioma, malformation, vascular anomalies

Copyright: Subrat Narendra Samal et al. Pan African Medical Journal (ISSN: 1937-8688). This is an Open Access article distributed under the terms of the Creative Commons Attribution International 4.0 License (<https://creativecommons.org/licenses/by/4.0/>), which permits unrestricted use, distribution, and reproduction in any medium, provided the original work is properly cited.

Cite this article: Subrat Narendra Samal et al. Congenital arteriovenous malformation (ISSVA classification for vascular anomalies). Pan African Medical Journal. 2023;46(103). 10.11604/pamj.2023.46.103.41202

Available online at: <https://www.panafrican-med-journal.com//content/article/46/103/full>

Congenital arteriovenous malformation (ISSVA classification for vascular anomalies)

Subrat Narendra Samal¹, Snehal Subrat Samal^{1,&}

¹Department of Musculoskeletal Physiotherapy, Ravi Nair Physiotherapy College, Datta Meghe Institute of Higher Education and Research, Sawangi, Meghe, Wardha, Maharashtra, India

&Corresponding author

Snehal Subrat Samal, Department of Neuro Physiotherapy, Ravi Nair Physiotherapy College, Datta Meghe Institute of Higher Education and Research, Sawangi, Meghe, Wardha, Maharashtra, India

Image in medicine

Presenting a Magnetic Resonance Imaging (MRI) finding of a 7 years, 5-month old male who was brought to our rural hospital by his father with chief complaints of swelling over his right hand since birth. His father narrated that the swelling is increasing significantly and the child has tenderness over swelling. The child underwent an angioembolism 1 month ago and has been brought for re-embolism. Now sclerotherapy has been planned for the patient. The physiotherapist received a call for a decreased range of motion at the elbow joint. Another haemangioma is also found in the forearm. MRI findings (sagittal T1W, T2W, STIR/PD) noted an altered signal intensity

oval lesion of size 5.4 x 5.6 x 6.2 cm appearing in the anterior intermuscular compartment and deep subcutaneous plane of the right arm displacing underlying muscles. Multiple prominent vascular channels are noted in the subcutaneous plane of the right arm. A similar signal with intensity was also noted in the intermuscular compartment of the proximal, a third of the right forearm. The

prevalence of Arteriovenous Malformations (AVM) is 1 per 100,000 populations per year. The patient is undergoing medications and physiotherapy rehabilitation exercises. The physiotherapy protocol started early and is continuing. Early medication and rehabilitation is the way to recover the range of motion in such patients.

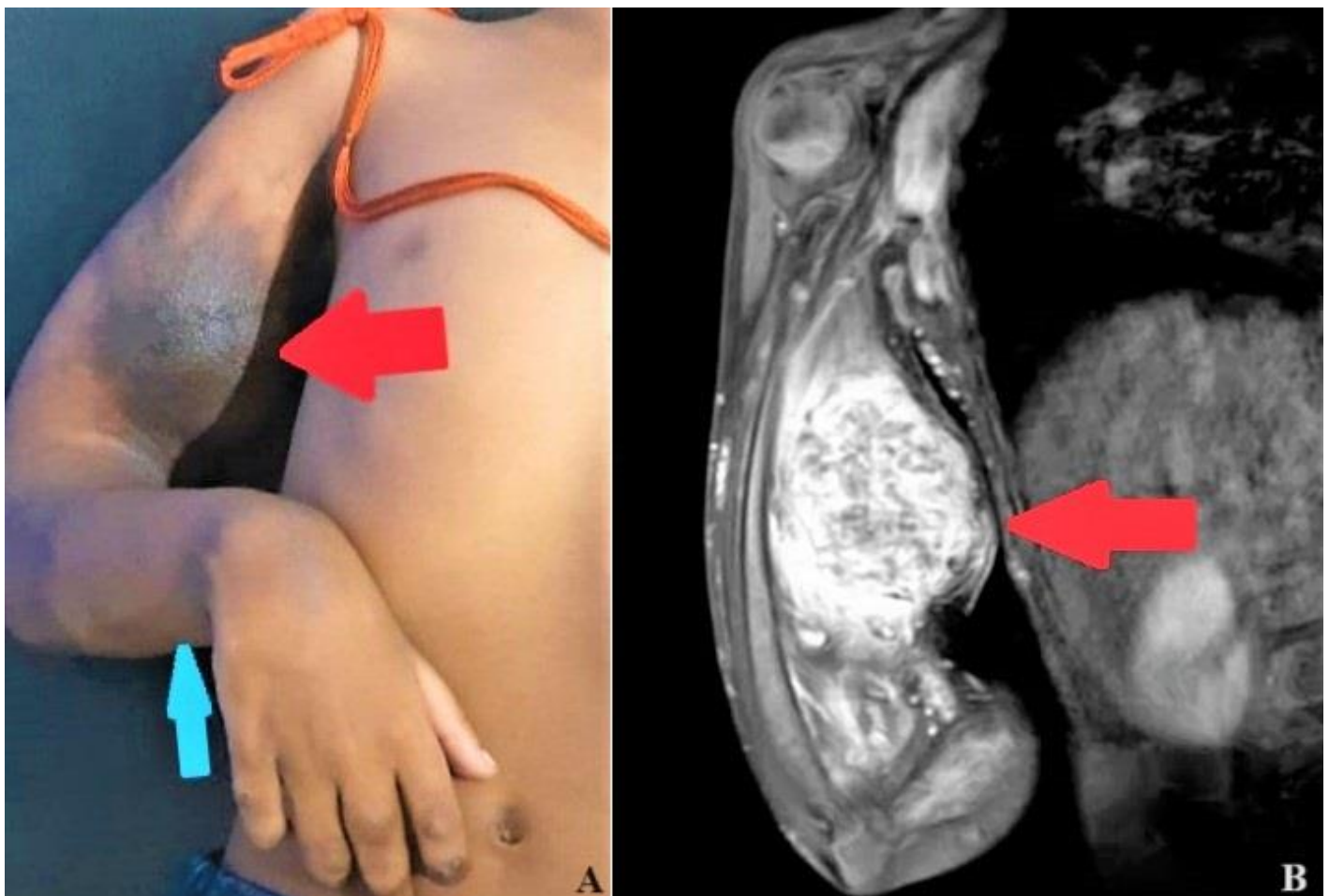


Figure 1: A) Magnetic Resonance Imaging (MRI) findings of bulging and blue-blackish discoloration, red arrows show oval lesion and blue arrow show skin blue colouration at intermuscular compartment of proximal 1/3rd of right forearm; B) MRI findings of arm arteriovenous malformation- red arrows show oval lesion of arteriovenous malformation