

Images in clinical medicine



Persistent Müllerian duct syndrome: a rare clinical image

 Yarraiahgari Maheswara, Revat Meshram

Corresponding author: Yarraiahgari Maheswara, Department of Pediatrics, Jawaharlal Nehru Medical College, Datta Meghe Institute of Health and Educational Research, Sawangi Meghe, Wardha, Maharashtra State, India. ymahesh963@gmail.com

Received: 11 Jan 2023 - **Accepted:** 17 Jan 2023 - **Published:** 24 Jan 2023

Keywords: Müllerian duct, undescended testis, fertility

Copyright: Yarraiahgari Maheswara et al. Pan African Medical Journal (ISSN: 1937-8688). This is an Open Access article distributed under the terms of the Creative Commons Attribution International 4.0 License (<https://creativecommons.org/licenses/by/4.0/>), which permits unrestricted use, distribution, and reproduction in any medium, provided the original work is properly cited.

Cite this article: Yarraiahgari Maheswara et al. Persistent Müllerian duct syndrome: a rare clinical image. Pan African Medical Journal. 2023;44(45). 10.11604/pamj.2023.44.45.38847

Available online at: <https://www.panafrican-med-journal.com//content/article/44/45/full>

Persistent Müllerian duct syndrome: a rare clinical image

Yarraiahgari Maheswara^{1,&}, Revat Meshram²

¹Department of Pediatrics, Jawaharlal Nehru Medical College, Datta Meghe Institute of Health and Educational Research, Sawangi Meghe, Wardha, Maharashtra State, India, ²Department of Paediatrics, Datta Meghe Institute of Higher Education and Research, Sawangi, Wardha, Maharashtra, India

[&]Corresponding author

Yarraiahgari Maheswara, Department of Pediatrics, Jawaharlal Nehru Medical College, Datta Meghe Institute of Health and Educational Research, Sawangi Meghe, Wardha, Maharashtra State, India

Image in medicine

Persistent Müllerian duct syndrome (PMDS) is a rare form of internal male pseudo-hermaphroditism in which Müllerian duct derivatives are seen in a male patient. The syndrome is caused by an insufficient amount of Müllerian inhibiting substance (MIS) or due to insensitivity of the target organ to MIS. It is usually discovered during surgery for hernia or undescended testis, as *hernia uteri inguinalis*. Persistent Müllerian duct syndrome is often familial, presenting as an autosomal recessive trait. It was characterized by the presence of Müllerian structures (fallopian tube by Nilson in 1939, as *hernia uteri inguinalis*. It has fallopian tubes, uterus and upper part of vagina) in phenotypically and genotypically male (46XY). The gene responsible is

chromosome 19. A 17-year-old male child presented with complaints of swelling in the right groin and associated with pain. On examination, an irreducible right inguinoscrotal swelling and right testis not palpable. Intraoperatively, the hernial sac was found to contain testis and uterus along with fallopian tubes and ovaries. The right testis was smaller compared to the opposite side. Excision of the Müllerian duct derived structures was done. This was followed by orchidopexy of right testis and right inguinal hernioplasty. Postoperative recovery of the patient was uneventful. It presents as inguinal hernia or undescended testis. A high index of suspicion is required when a patient presents with bilateral inguinoscrotal problems. Whenever possible, excision of Müllerian structures meticulously, avoiding injury to the vas, must be performed. The aim is to preserve fertility. Orchidopexy should be the goal of management.

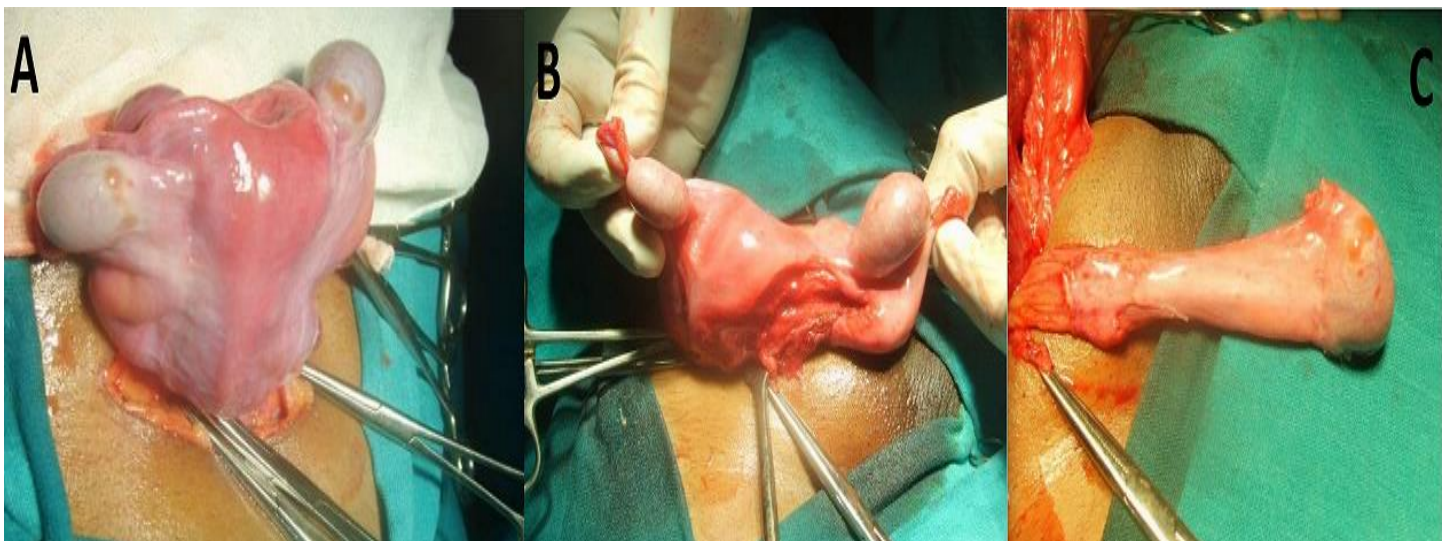


Figure 1: A) uterus with bilateral testis; B) surgical separation of uterus from testis; C) testis separated from uterus