


Images in clinical medicine

Acquired vulvar lymphangioma circumscriptum after cervical cancer

 Jiexia Qiu, Xinrong Chen

Corresponding author: Jiexia Qiu, Zhuji People's Hospital of Zhejiang Province, Shaoxing, China. qjx198710@163.com

Received: 17 Dec 2022 - **Accepted:** 09 Jan 2023 - **Published:** 16 Jan 2023

Keywords: Lymphangioma, vulvar, cervical cancer

Copyright: Jiexia Qiu et al. Pan African Medical Journal (ISSN: 1937-8688). This is an Open Access article distributed under the terms of the Creative Commons Attribution International 4.0 License (<https://creativecommons.org/licenses/by/4.0/>), which permits unrestricted use, distribution, and reproduction in any medium, provided the original work is properly cited.

Cite this article: Jiexia Qiu et al. Acquired vulvar lymphangioma circumscriptum after cervical cancer. Pan African Medical Journal. 2023;44(29). 10.11604/pamj.2023.44.29.38557

Available online at: <https://www.panafrican-med-journal.com//content/article/44/29/full>

Acquired vulvar lymphangioma circumscriptum after cervical cancer

Jiexia Qiu^{1,&}, Xinrong Chen¹

¹Zhuji People's Hospital of Zhejiang Province, Shaoxing, China

&Corresponding author

Jiexia Qiu, Zhuji People's Hospital of Zhejiang Province, Shaoxing, China

Image in medicine

A 72-year-old woman had a history of cervical cancer. She underwent a total hysterectomy twenty years ago and received chemotherapy for one year after surgery. She had lesions with swelling, mild pruritus, and watery secretion on the vulvar surface for two years. Then the lesions gradually increased, causing partial fusion. Histologic examination revealed the vulva had multiple dilated lymphatic vessels in the dermis. The histologic diagnosis was vulvar lymphangioma.

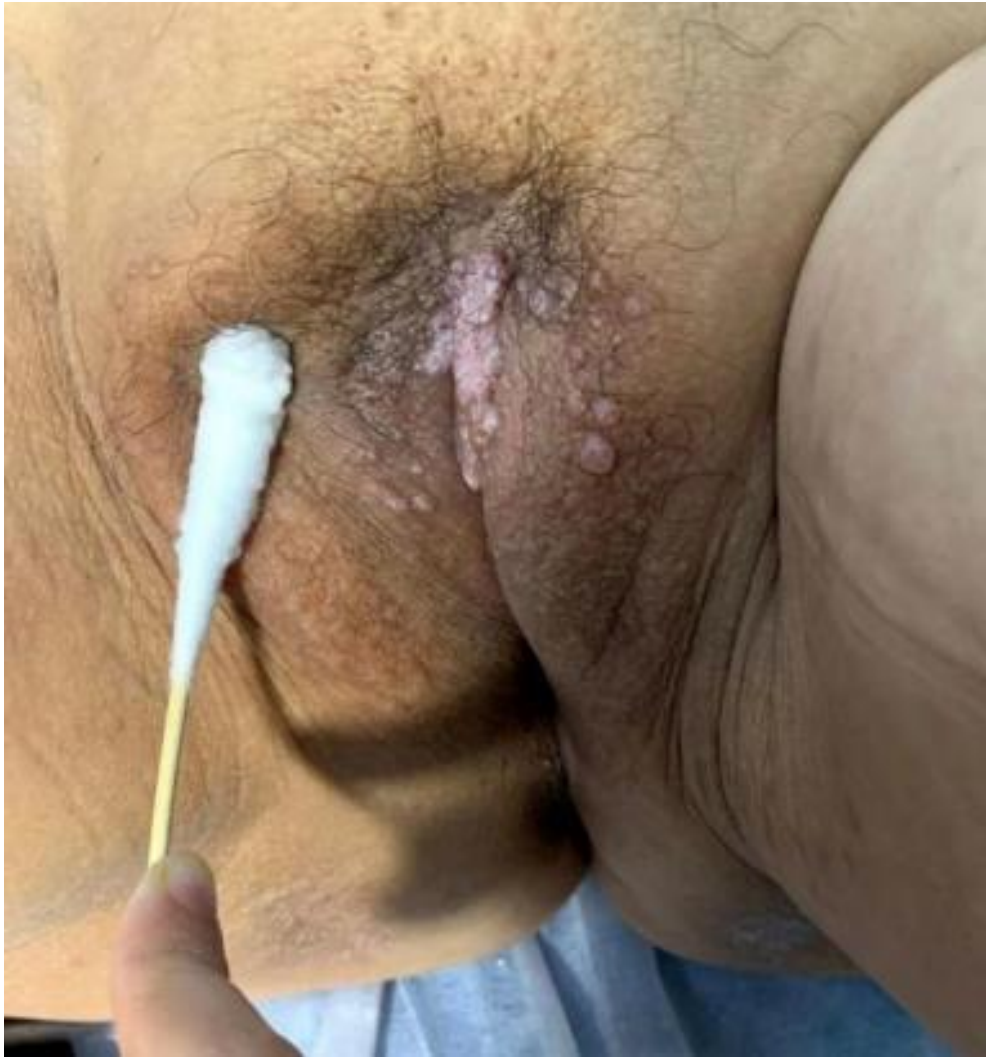

Figure 1: multiple papules and nodules of the vulva resemble false blisters