






Case report



Bladder rupture after pembrolizumab immunotherapy for bladder cancer: a case report

 Ahmed Badheeb,  Omar Alkhanbashi,  Slah Rakrouki, Tahir Mahmood, Mashhoor Alqannas,  Mohamed Badheeb,  Faisal Ahmed

Corresponding author: Ahmed Badheeb, Oncology Center, King Khalid Hospital, Najran, Saudi Arabia. Badheebdr@gmail.com

Received: 20 Feb 2022 - **Accepted:** 01 Jun 2022 - **Published:** 07 Jun 2022

Keywords: Perforation, bladder cancer, pembrolizumab, case report

Copyright: Ahmed Badheeb et al. Pan African Medical Journal (ISSN: 1937-8688). This is an Open Access article distributed under the terms of the Creative Commons Attribution International 4.0 License (<https://creativecommons.org/licenses/by/4.0/>), which permits unrestricted use, distribution, and reproduction in any medium, provided the original work is properly cited.

Cite this article: Ahmed Badheeb et al. Bladder rupture after pembrolizumab immunotherapy for bladder cancer: a case report. Pan African Medical Journal. 2022;42(98). 10.11604/pamj.2022.42.98.33911

Available online at: <https://www.panafrican-med-journal.com//content/article/42/98/full>

Bladder rupture after pembrolizumab immunotherapy for bladder cancer: a case report

Ahmed Badheeb^{1,&}, Omar Alkhanbashi², Slah Rakrouki², Tahir Mahmood³, Mashhoor Alqannas³, Mohamed Badheeb⁴, Faisal Ahmed⁵

¹Oncology Center, King Khalid Hospital, Najran, Saudi Arabia, ²Department of Urology, King Khalid Hospital, Najran, Saudi Arabia, ³Department of General Surgery, King Khalid Hospital, Najran, Saudi Arabia, ⁴Department of Internal Medicine, King Khalid Hospital, Najran, Saudi Arabia, ⁵Urology Research Center, Al-Thora General Hospital,

Department of Urology, School of Medicine, Ibb University of Medical Science, Ibb, Yemen

[&]Corresponding author

Ahmed Badheeb, Oncology Center, King Khalid Hospital, Najran, Saudi Arabia

Abstract

Pembrolizumab is a promising checkpoint inhibitor for advanced urothelial carcinoma. Like other immunotherapies, it can cause rare immune-related adverse events. The spontaneous rupture of the urinary bladder after the intravenous injection of pembrolizumab is rare and has not been reported. Here, we present a 74-year-old man patient case of locally advanced transitional cell carcinoma of the urinary bladder who presented severe abdominal pain the same day of the second dose of pembrolizumab administration. The exploratory laparotomy revealed intraperitoneal rupture of the urinary bladder associated with peritonitis. After surgical repair, the patient's condition improved. The purpose of this report is to discuss the possible association of bladder perforation in bladder cancer with pembrolizumab immunotherapy, its management, and the importance of early recognition to prevent more fatal complications.

Introduction

Injuries to the urinary bladder are rare and life-threatening events. Prompt diagnosis followed by surgical intervention is the key to a successful outcome [1]. The actual incidence of spontaneous rupture of the urinary bladder is uncertain; it is estimated to represent one in 126000 hospital admissions [2]. Pembrolizumab, a programmed cell death-1 checkpoint inhibitor, has high efficacy, low toxicity, and prolonged overall survival in platinum-refractory metastatic urothelial carcinoma [3]. It was approved for non-muscle-invasive bladder cancer (NMIBC) with carcinoma in situ patients who are not eligible or who have chosen not to undergo cystectomy [4]. Many cutaneous, endocrinological, and neurological side effects have been reported using pembrolizumab; in addition, gastrointestinal involvement was observed in the form of hepatitis, pancreatitis, intestinal perforation, and colitis [5]. Although infrequent, renal-related side effects associated with pembrolizumab, including; acute tubulointerstitial nephritis, nonbacterial cystitis,

and nephritis [6,7]. To our knowledge, this is the first reported case of spontaneous intraperitoneal urinary bladder perforation associated with peritonitis after pembrolizumab immunotherapy in a patient with transitional cell carcinoma (TCC) of the urinary bladder NMIBC.

Patient and observation

Patient information: a 74-year-old man with advanced TCC of the urinary bladder on immunotherapy with pembrolizumab presented to our emergency department with severe diffuse abdominal pain after administering the second dose of pembrolizumab. The patient was a known case of NMIBC with carcinoma in situ, who Bacillus Calmette-Guérin-unresponsive, elected not to undergo cystectomy. The patient decided to try pembrolizumab. He also a case of hypertension and diabetes mellitus on oral medication.

Clinical findings: regarding physical examination, the pulse rate was 105 beats per minute, the respiratory rate was 20 per minute, blood pressure was 90/60 mm/Hg, and the oral temperature was 38°C. The patient had diffuse abdominal tenderness, guarding, and detectable pelvic mass up to the umbilicus.

Diagnostic assessment: blood tests revealed a total white blood cell count: 12×10^3 ml with moderate leukocytosis and hemoglobin: 14.4 g/dl, blood urea nitrogen: 14 mg/dl, creatinine: 1.5 mg/dl. The chest radiograph demonstrated air under the diaphragm (Figure 1). The patient was diagnosed with acute abdomen and peritonitis. For that, the patient was prepared emergently for surgical operation without ultrasonography or computed tomography (CT) scan investigations.

Therapeutic interventions: the patient underwent an immediate exploratory laparotomy, and it was discovered that he had a frozen pelvis, an adherent bladder to the anterior abdominal wall. The methylene blue dye test showed a 2 cm intraperitoneal perforation and another approximately 4 cm extraperitoneal perforation

with urine leakage (Figure 2). The gastrointestinal tract was intact and wash-out was performed for the bladder for some necrotic tissue observed intraoperatively. Due to the unstable patient's condition during surgery, the intraperitoneal perforation was closed with a vicryl suture. The edges of the extraperitoneal perforation and the posterior abdominal wall were invaded by the tumor, difficult to recognize. In addition, a 36 French catheter scale was inserted as a drain in the retropubic space, and the foley catheter was kept inflated in place. The patient was kept on bilateral nephrostomy drain to complete diversion of the urine post-operatively.

Follow-up and outcome: at postoperative day 5, the patient was discharged home with Foley's catheter and bilateral nephrostomy drain.

Patient perspective: the patient said: before entering the hospital and due to the severe abdominal pain, I thought it was the end of life and that I was inevitably dead, but thanks to God and the doctors, the doctors were able to save my life. The patient thanked the doctors for all the care and medical advice they gave him.

Written informed consent: written informed consent was obtained from the patient for participation in our study.

Discussion

To our knowledge, this is the first reported case of urinary bladder perforation during pembrolizumab immunotherapy from a patient with NMIBC. The possible pathogenesis of bladder rupture in bladder cancer is the precipitation of perforation on the weakened body wall by the tumor. However, the most frequent location for intraperitoneal perforation was the bladder's dome or posterior wall [1]. Spontaneous bladder rupture is more common in men with squamous cell carcinoma, as their bladder is more distensible and subsequently more prone to perforation, especially in the dome or posterior wall [8,9].

High clinical suspicion is crucial for the timely diagnosis, and radiological confirmation should be established by abdominal CT and cystogram [1,10]. Our patient presented with symptoms of peritonitis and no time for additional radiologic investigation. For that, we decide on surgical exploration depending on our physical exam and plain radiographic image. Organ perforation in the setting of immunotherapy is a rare but life-threatening complication and should be considered in cancer patients receiving immunotherapy who present with acute abdomen. Its incidence rate in previous studies was 12% [1]. Colitis-induced colon perforation and fatal pneumonitis are rare but serious adverse events [11,12]. Like in our case, the main presenting symptoms are mainly those of peritonitis and, in some cases, may lead to false alarm of acute renal insufficiency, which is mainly due to the peritoneal absorption of urine [1,9].

The prognosis for spontaneous bladder rupture due to carcinoma is poor. In a previous review, most patients died within months, ranging from 10 days to 8 months. The mortality rate can range from 25% to 80%, depending on the time of diagnosis [8]. Our patient was diagnosed and operated in the same day of presentation. After confirmation of diagnosis, extraperitoneal rupture is usually treated conservatively, while intraperitoneal rupture should be treated surgically, such as primary closure, partial cystectomy, or radical cystectomy. However, a significant proportion of cases are unfit and managed conservatively using an indwelling urethral catheter and/or with bilateral nephrostomy [9,13]. Partial cystectomy was impossible in our case as the tumor was occupying most of the bladder, leaving no normal mucosa. For that, our case underwent primary repair of intraperitoneal rupture, internal foley insertion, and bilateral nephrostomy insertion. Although no pathological specimen was submitted for study at the time of perforation, which could support our hypothesis with the presence of increased lymphocytic infiltration/inflammation; or evidence of clinical response with necrosis increasing the risk of rupture, we hypothesize that

immunotherapy given with a weakened bladder wall played a significant role in the perforation.

Conclusion

Urinary bladder perforation in the setting of pembrolizumab immunotherapy for bladder cancer should be considered among the differential diagnosis of acute abdomen and peritonitis. This case report opens the door for further confirmative studies as a hypothesis-generating.

Competing interests

The authors declare no competing interests.

Authors' contribution

Patient management: AB, TM, and MB; data collection, manuscript drafting, and revision: OA, FA, MA, and SR. All the authors have read and agreed to the final manuscript.

Acknowledgments

The authors would like to thank the General Manager of King Khalid Hospital, Najran, Saudi Arabia, Dr Mohammed Almasabi, for editorial assistance.

Figures

Figure 1: chest X-ray showing air under the diaphragm

Figure 2: intraoperative photo showing perforation of the urinary bladder (arrow)

References

- Ahmed J, Mallick IH, Ahmad SM. Rupture of urinary bladder: a case report and review of literature. *Cases J.* 2009 May 14;2: 7004. **PubMed** | **Google Scholar**
- Dubey IB, Mohanty D, Jain BK. Diverse presentation of spontaneous rupture of urinary bladder: review of two cases and literature. *Am J Emerg Med.* 2012 Jun;30(5): 83e1-3. **PubMed** | **Google Scholar**
- Bellmunt J, de Wit R, Vaughn DJ, Fradet Y, Lee JL, Fong L *et al.* Pembrolizumab as second-line therapy for advanced urothelial carcinoma. *N Engl J Med.* 2017 Mar 16;376(11): 1015-26. **PubMed** | **Google Scholar**
- Wright KM. FDA approves pembrolizumab for BCG-unresponsive NMIBC. *Oncology (Williston Park).* 2020 Feb 20;34(2): 44. **PubMed** | **Google Scholar**
- Darnell EP, Mooradian MJ, Baruch EN, Yilmaz M, Reynolds KL. Immune-Related Adverse Events (irAEs): diagnosis, management, and clinical pearls. *Curr Oncol Rep.* 2020 Mar 21;22(4): 39. **PubMed** | **Google Scholar**
- Basnet S, Dhital R, Tharu B. Acute tubulointerstitial nephritis: a case report on rare adverse effect of pembrolizumab. *Medicina (Kaunas).* 2019 May 21;55(5): 176. **PubMed** | **Google Scholar**
- Elkbuli A, Ehrhardt JD, Hai S, McKenney M, Boneva D. Management of blunt intraperitoneal bladder rupture: case report and literature review. *Int J Surg Case Rep.* 2019;55: 160-3. **PubMed** | **Google Scholar**
- Addar MH, Stuart GC, Nation JG, Shumsky AG. Spontaneous rupture of the urinary bladder: a late complication of radiotherapy-case report and review of the literature. *Gynecol Oncol.* 1996 Aug;62(2): 314-6. **PubMed** | **Google Scholar**
- Al Edwan GM, Mansi HH, Atta ONM, Shaban MM. Squamous cell carcinoma of the bladder presented with spontaneous intraperitoneal bladder rupture: a case report. *Int J Surg Case Rep.* 2018;48: 61-4. **PubMed** | **Google Scholar**
- Titton RL, Gervais DA, Hahn PF, Harisinghani MG, Arellano RS, Mueller PR. Urine leaks and urinomas: diagnosis and imaging-guided intervention. *Radiographics.* 2003 Sep-Oct;23(5): 1133-47. **PubMed** | **Google Scholar**

11. Ueki Y, Matsuki M, Kubo T, Morita R, Hirohashi Y, Sato S *et al.* Non-bacterial cystitis with increased expression of programmed death-ligand 1 in the urothelium: an unusual immune-related adverse event during treatment with pembrolizumab for lung adenocarcinoma. *IJU Case Rep.* 2020 Nov;3(6): 266-9. [PubMed](#) | [Google Scholar](#)
12. Zhu L, Wang Z, Stebbing J, Wang Z, Peng L. Immunotherapy-related cystitis: case report and review of the literature. *Onco Targets Ther.* 2021;14: 4321-8. [PubMed](#) | [Google Scholar](#)
13. Asano T, Ohtsuka Y. Spontaneous bladder rupture due to bladder carcinoma: a case report required emergency radical cystectomy. *Urol Case Rep.* 2020 Nov;33: 101412. [PubMed](#) | [Google Scholar](#)

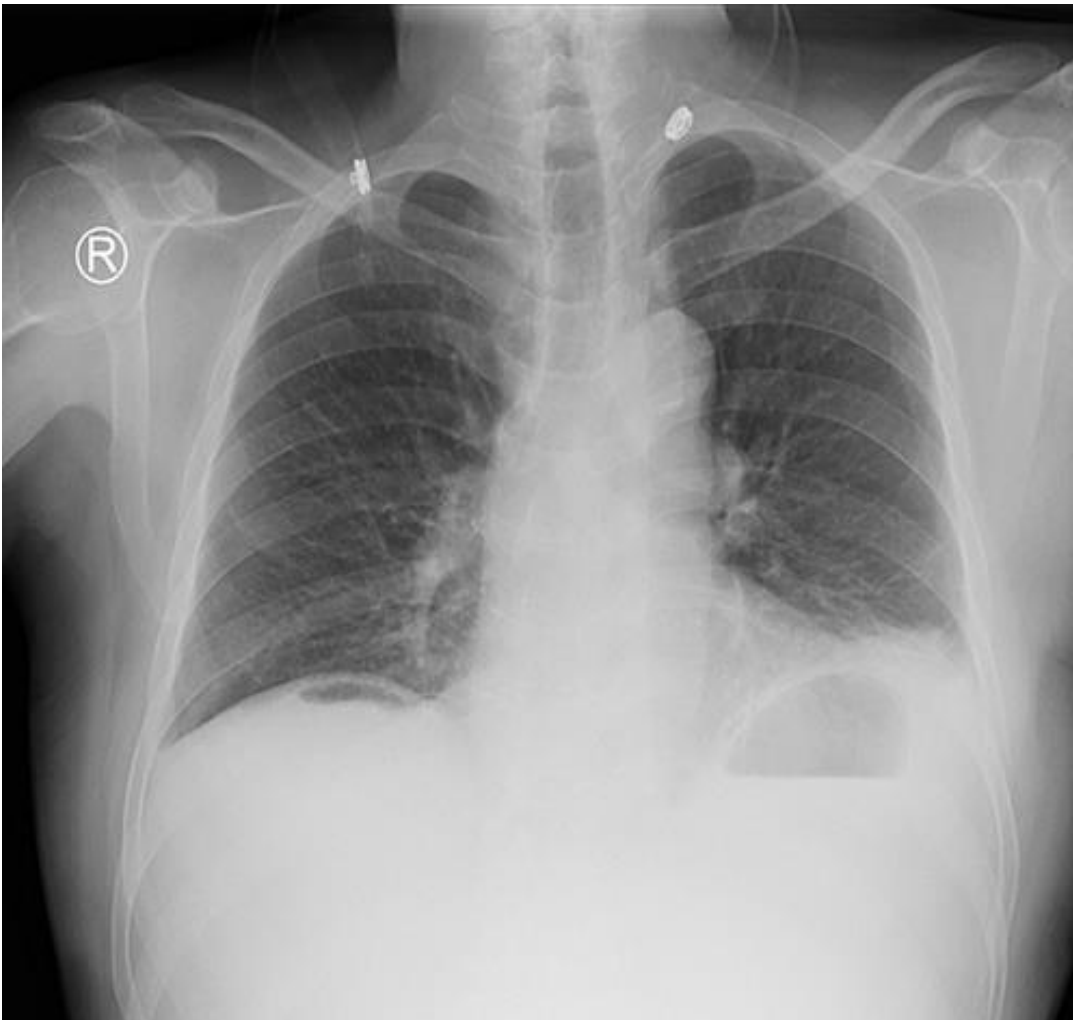


Figure 1: chest X-ray showing air under the diaphragm

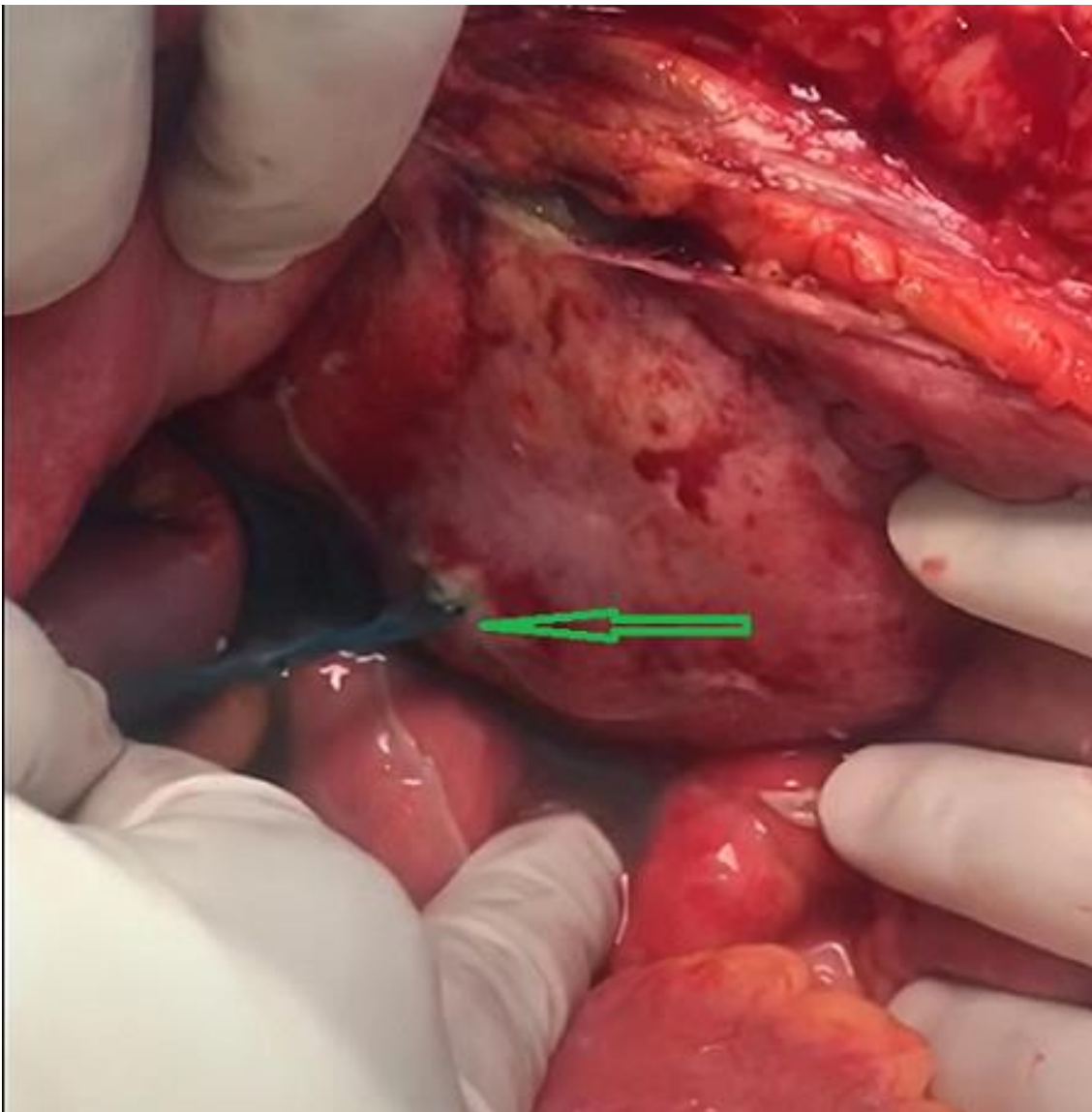


Figure 2: intraoperative photo showing perforation of the urinary bladder (arrow)