

Images in clinical medicine

Myelinated retinal nerve fiber layer: an extensive presentation

Zeineb Kallel, Malek Kharrat

Corresponding author: Zeineb Kallel, Ophtalmology Department, Hospital of Mohamed Taher Maamouri, Nabeul, Tunisia. zeineb.kallel611@gmail.com

Received: 04 Apr 2022 - **Accepted:** 08 Apr 2022 - **Published:** 18 May 2022

Keywords: Myelinated retinal fibers, amblyopia, strabismus

Copyright: Zeineb Kallel et al. Pan African Medical Journal (ISSN: 1937-8688). This is an Open Access article distributed under the terms of the Creative Commons Attribution International 4.0 License (<https://creativecommons.org/licenses/by/4.0/>), which permits unrestricted use, distribution, and reproduction in any medium, provided the original work is properly cited.

Cite this article: Zeineb Kallel et al. Myelinated retinal nerve fiber layer: an extensive presentation. Pan African Medical Journal. 2022;42(51). 10.11604/pamj.2022.42.51.34665

Available online at: <https://www.panafrican-med-journal.com//content/article/42/51/full>

Myelinated retinal nerve fiber layer: an extensive presentation

Zeineb Kallel^{1,&}, Malek Kharrat¹

¹Ophtalmology Department, Hospital of Mohamed Taher Maamouri, Nabeul, Tunisia

&Corresponding author

Zeineb Kallel, Ophtalmology Department, Hospital of Mohamed Taher Maamouri, Nabeul, Tunisia

Image in medicine

Myelinated retinal nerve fiber layer is rare. It is estimated to occur in 0.5% to 1% of the population and is often detected on routine examination without symptoms. It consists of white or gray-white well-demarcated patches on the outermost surface of the retina that obscure the underlying retinal vessels. It can be associated with axial myopia, amblyopia, and strabismus. A 12-year-old girl with normal development presented with ocular deviation of the right eye. There was no past medical or ocular history. Automatic refraction found in the right eye -9 PD and -1 PD in the left eye. The best Visual acuity was 20/600 in the right

eye and 20/20 in the left one. Slit lamp examination of the right eye (A) revealed two vast whitish zones extending from the papilla towards the temporal sector sparing the posterior pole. These lesions covered the temporal vessels with fuzzy and scalloped boundaries. Fundus examination of the

left eye was without abnormalities (B). Scan of Spectral Domain Optical Coherence Tomography (SD OCT) showed isolated hyper reflectivity of the fiber optic layer, an abnormality of the vitreoretinal interface with posterior shadow cone effect (C).

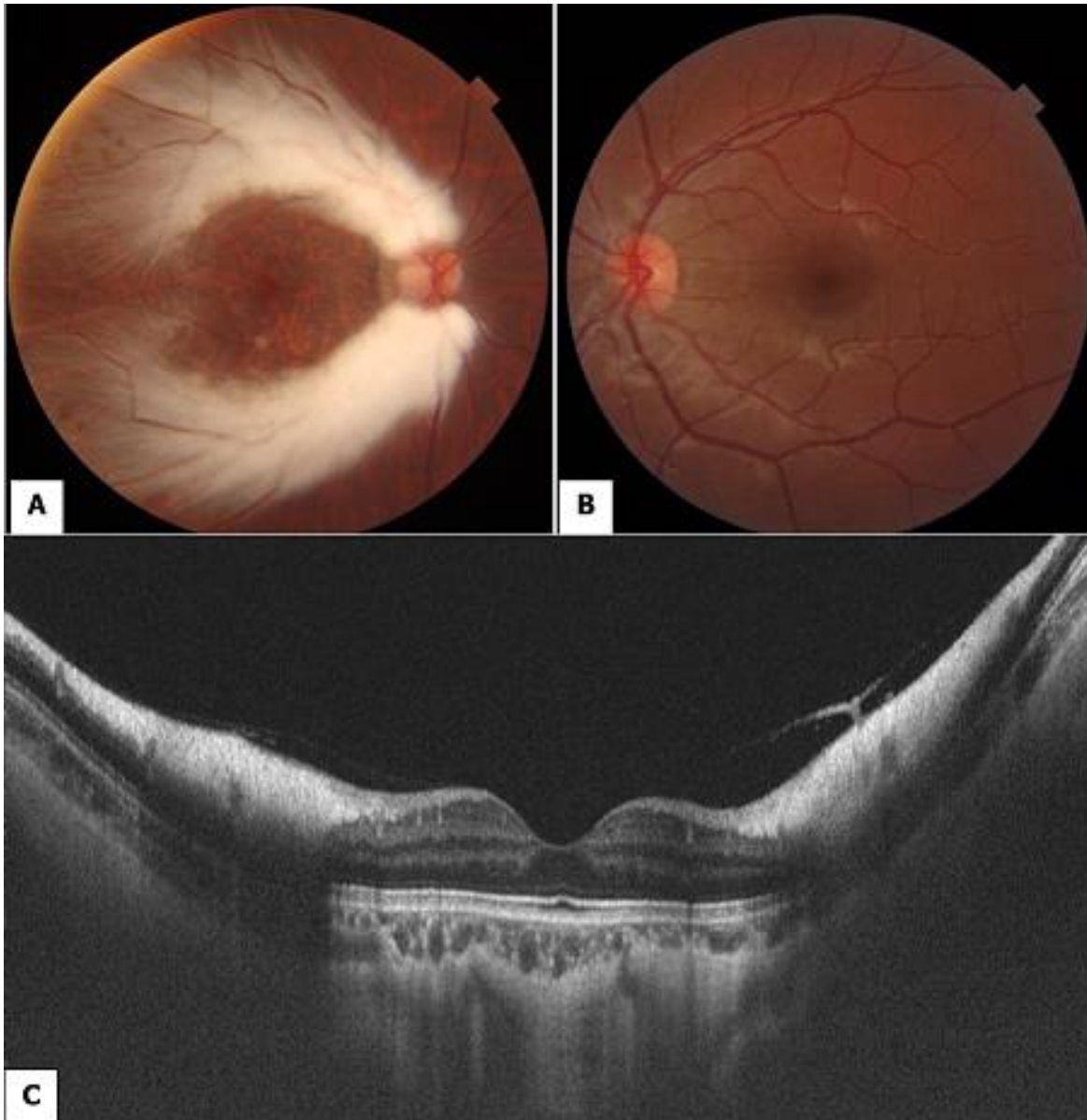


Figure 1: fundus examination of both eyes and SD-OCT scan: A (RE): two vast whitish zones extending from the papilla towards the temporal sector sparing the posterior pole; B (LE): without abnormalities; C (SD-OCT): hyper reflectivity of the retinal nerve fiber layer with posterior shadow cone effect