

## Images in clinical medicine



# Monomelic amyotrophy: a rare disease with unusual features (Hirayama disease)

 Chaitanya Kulkarni,  Waqar Mohsin Naqvi

**Corresponding author:** Waqar Mohsin Naqvi, Community Physiotherapy Department, Ravi Nair Physiotherapy College, Datta Meghe Institute of Medical Sciences, Sawangi (M), Wardha, India. Waqar.naqvi@dmimsu.edu.in

**Received:** 25 Apr 2021 - **Accepted:** 20 Apr 2022 - **Published:** 18 May 2022

**Keywords:** Monomelic amyotrophy, Hirayama disease, UMN and LMN features

**Copyright:** Chaitanya Kulkarni et al. Pan African Medical Journal (ISSN: 1937-8688). This is an Open Access article distributed under the terms of the Creative Commons Attribution International 4.0 License (<https://creativecommons.org/licenses/by/4.0/>), which permits unrestricted use, distribution, and reproduction in any medium, provided the original work is properly cited.

**Cite this article:** Chaitanya Kulkarni et al. Monomelic amyotrophy: a rare disease with unusual features (Hirayama disease). Pan African Medical Journal. 2022;42(48). 10.11604/pamj.2022.42.48.29515

**Available online at:** <https://www.panafrican-med-journal.com//content/article/42/48/full>

Monomelic amyotrophy: a rare disease with unusual features (Hirayama disease)

Chaitanya Kulkarni<sup>1</sup>, Waqar Mohsin Naqvi<sup>2,&</sup>

<sup>1</sup>Community Physiotherapy Department, Ravi Nair Physiotherapy College, Datta Meghe Institute of Medical Sciences, Sawangi (M), Wardha, India,

<sup>2</sup>NKP Salve Institute of Medical Sciences and Research Center, Nagpur, India

**&Corresponding author**

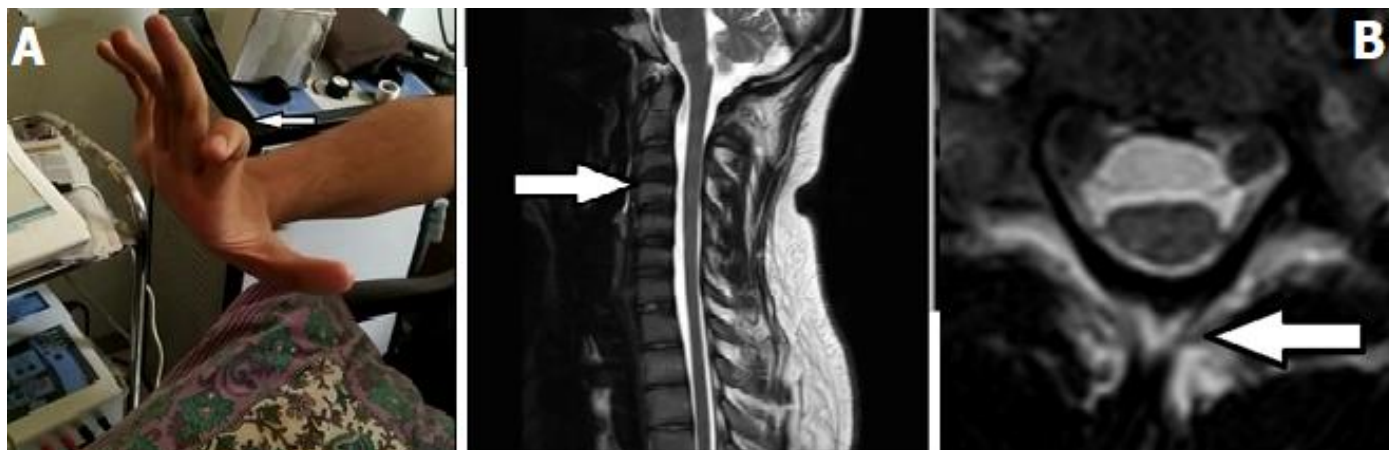
Waqar Mohsin Naqvi, NKP Salve Institute of Medical Sciences and Research Center, Nagpur, India

## Image in medicine

A 36 years old female presented with chief complains of right sided upper limb weakness which was gradual in onset and progressive in nature. When detailed history was taken, it was observed that she was also having complains of altered sensations and hyperhidrosis in both the palms. On further assessment we found that there was no history of trauma to cervical region or any cervical pain. She has no other past history such as allergies or any exposure to toxins. On neurological assessment we found that patient has muscle atrophy with increased tone in upper limb along with tremors (A) and uncertain atrophy like

changes in cervical spine on MRI (Magnetic Resonance Imaging) (B). On further examination clonus was present over left calf with Babinski sign

positive. When further investigations were done it was found out that patient has lower and upper motor neuron lesions.



**Figure 1:** clinical as well as radiological features A) atrophy of the forearm leads to the difficulty of the movements of the hands; B) MRI findings shows unusual atrophy and changes in the cervical spine