

## Images in clinical medicine



# Warts on hand: a rare clinical image

 Mayur Bhaskar Wanjari,  Tejaswee Lohakare

**Corresponding author:** Mayur Bhaskar Wanjari, Department of Research and Development, Jawaharlal Nehru Medical College, Datta Meghe Institute of Medical Sciences, Sawangi, Wardha, Maharashtra, India. wanjari605@gmail.com

**Received:** 11 Apr 2022 - **Accepted:** 15 Apr 2022 - **Published:** 28 Apr 2022

**Keywords:** Warts, papillomavirus, contagious

**Copyright:** Mayur Bhaskar Wanjari et al. Pan African Medical Journal (ISSN: 1937-8688). This is an Open Access article distributed under the terms of the Creative Commons Attribution International 4.0 License (<https://creativecommons.org/licenses/by/4.0/>), which permits unrestricted use, distribution, and reproduction in any medium, provided the original work is properly cited.

**Cite this article:** Mayur Bhaskar Wanjari et al. Warts on hand: a rare clinical image. Pan African Medical Journal. 2022;41(343). 10.11604/pamj.2022.41.343.34821

**Available online at:** <https://www.panafrican-med-journal.com//content/article/41/343/full>

## Warts on hand: a rare clinical image

Mayur Bhaskar Wanjari<sup>1,&</sup>, Tejaswee Lohakare<sup>2</sup>

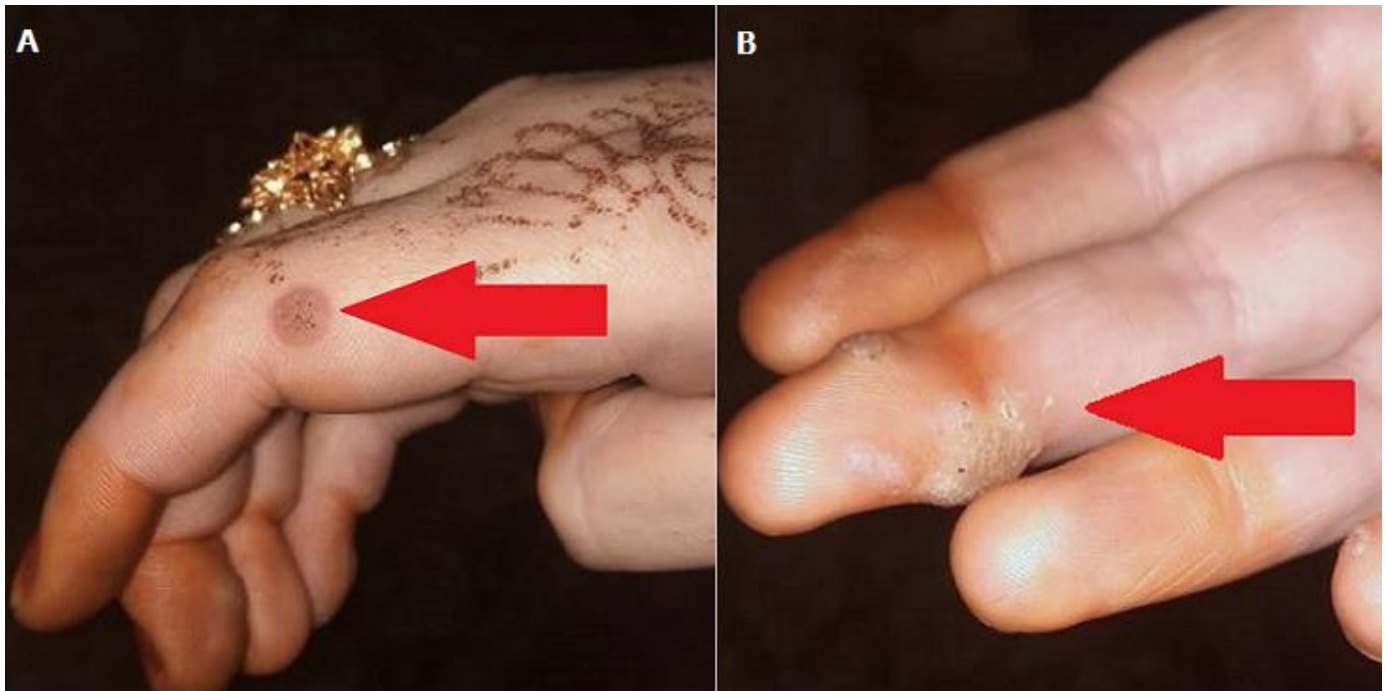
<sup>1</sup>Department of Research and Development, Jawaharlal Nehru Medical College, Datta Meghe Institute of Medical Sciences, Sawangi, Wardha, Maharashtra, India, <sup>2</sup>Department of Child Health Nursing, Smt. Radhikabai Meghe Memorial College of Nursing, Datta Meghe Institute of Medical Sciences, Sawangi, Wardha, Maharashtra, India

### **&Corresponding author**

Mayur Bhaskar Wanjari, Department of Research and Development, Jawaharlal Nehru Medical College, Datta Meghe Institute of Medical Sciences, Sawangi, Wardha, Maharashtra, India

## Image in medicine

Warts are a type of skin infection caused by the human papillomavirus (HPV). The disease causes rough, skin-coloured bumps to form on the skin. The virus is contagious. Warts can be spread by touching someone who has them. We are presenting a case of 21 years old female who comes to the skin outpatient department with the complaint of skin-coloured bumps on the middle finger. The physician inspected the patient hand and suggested a skin biopsy of the infected area. A biopsy sample was taken for the skin growth test for the HPV, and it revealed the patient had an infection of HPV. After all examinations, the patient was diagnosed with warts and given medical management on that.



**Figure 1:** right-hand skin-coloured bumps (A,B)