

**Images in clinical medicine**

# Penile calciphylaxis: rare and unrecognized disease

 Larbi Hamedoun,  Tetou Mohamed

**Corresponding author:** Larbi Hamedoun, Service of Urology, Military Hospital of Instruction Mohamed V, Hay Ryad, Rabat, Morocco. Larbi771@gmail.com

**Received:** 03 Feb 2022 - **Accepted:** 13 Feb 2022 - **Published:** 13 Feb 2022

**Keywords:** Penile necrosis, calciphylaxis, end-stage-renal-disease

**Copyright:** Larbi Hamedoun et al. Pan African Medical Journal (ISSN: 1937-8688). This is an Open Access article distributed under the terms of the Creative Commons Attribution International 4.0 License (<https://creativecommons.org/licenses/by/4.0/>), which permits unrestricted use, distribution, and reproduction in any medium, provided the original work is properly cited.

**Cite this article:** Larbi Hamedoun et al. Penile calciphylaxis: rare and unrecognized disease. Pan African Medical Journal. 2022;41(124). 10.11604/pamj.2022.41.124.33602

**Available online at:** <https://www.panafrican-med-journal.com//content/article/41/124/full>

## Penile calciphylaxis: rare and unrecognized disease

Larbi Hamedoun<sup>1,&</sup>, Tetou Mohamed<sup>1</sup>

<sup>1</sup>Service of Urology, Military Hospital of Instruction Mohamed V, Hay Ryad, Rabat, Morocco

### **&Corresponding author**

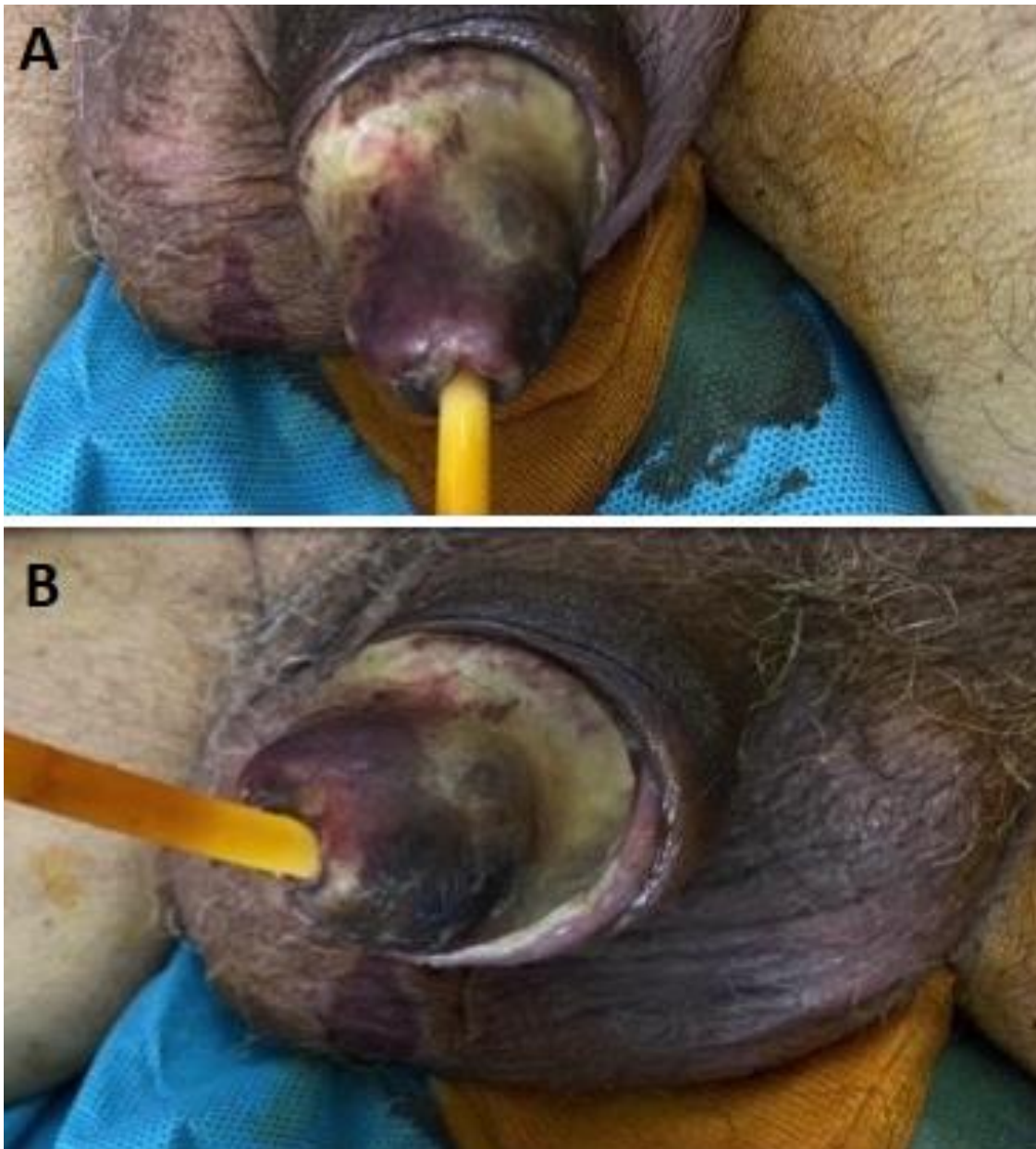
Larbi Hamedoun, Service of Urology, Military Hospital of Instruction Mohamed V, Hay Ryad, Rabat, Morocco

## Image in medicine

The patient was 78 years old, a chronic weaned smoker, a poorly balanced type II diabetic, hypertensive and with end-stage chronic renal failure with preserved diuresis, and had been on haemodialysis for more than 10 years. Examination of the external genitalia revealed a blackish, indurated and painful glans penis with the presence of a crust extending to the balanopreputial groove, suggesting necrosis of the penis, which is in favour of dry penile gangrene. This is penile calciphylaxis of pure clinical diagnosis based on careful questioning and examination of the external genitalia. This location is exceptional as the penis is richly vascularised. It is a serious systemic disorder

that affects elderly subjects with a history of atherosclerosis, diabetes mellitus, intravascular calcification, 1 to 4% patients with chronic renal disease requiring dialysis, obesity or high blood pressure. Treatment may involve sodium thio-sulfate, wound care, and urinary diversion

with a suprapubic catheter to prevent infection, progression of necrosis, and amputation. It is generally of very poor prognosis, with an overall mortality rate of 70%. Patient died the same day following septic shock.



**Figure 1:** A,B) images during physical exam demonstrating dry penile gangrene