

Images in clinical medicine



Poland's syndrome with dextroposition and paradoxical breathing

Ng Kian Seng, Sarvesh Seger

Corresponding author: Sarvesh Seger, School of Medicine, International Medical University, Clinical Campus Kluang, Kluang, Johor, Malaysia. sars2509@gmail.com

Received: 11 Dec 2020 - **Accepted:** 27 Jan 2021 - **Published:** 03 Feb 2021

Keywords: Poland's syndrome, dextroposition, cervical ribs, electrocardiogram, chest radiograph

Copyright: Ng Kian Seng et al. Pan African Medical Journal (ISSN: 1937-8688). This is an Open Access article distributed under the terms of the Creative Commons Attribution International 4.0 License (<https://creativecommons.org/licenses/by/4.0/>), which permits unrestricted use, distribution, and reproduction in any medium, provided the original work is properly cited.

Cite this article: Ng Kian Seng et al. Poland's syndrome with dextroposition and paradoxical breathing. Pan African Medical Journal. 2021;38(110). 10.11604/pamj.2021.38.110.27384

Available online at: <https://www.panafrican-med-journal.com/content/article/38/110/full>

Poland's syndrome with dextroposition and paradoxical breathing

Ng Kian Seng¹, Sarvesh Seger^{2,&}

¹Department of Internal Medicine, International Medical University, Clinical Campus Kluang, Kluang, Johor, Malaysia, ²School of Medicine, International Medical University, Clinical Campus Kluang, Kluang, Johor, Malaysia

&Corresponding author

Sarvesh Seger, School of Medicine, International Medical University, Clinical Campus Kluang, Kluang, Johor, Malaysia

Image in medicine

An asymptomatic 60-year-old woman presented to our outpatient clinic for a routine health screening as part of a government welfare program. Her medical history was unremarkable, however physical examination revealed hypoplasia of the left chest wall muscles, breast tissue, nipple, absence of axillary hair, absence of the costal cartilages of upper ribs on the left side of the chest and brachydactyly in the left hand. There was also paradoxical breathing at the levels of the 2nd, 3rd and 4th rib of the left chest. The rest of the examination was unremarkable. The chest radiograph revealed reduced upper left hemithorax volume with partial

rib agenesis of the 2nd, 3rd and 4th rib, bilateral cervical ribs, dextroposition of the heart and mid thoracic scoliosis with convexity to the left. A 12-lead electrocardiogram revealed a sinus rhythm with a normal axis, lead 1 has upright P, QRS, and T waves and aVR is globally negative. The precordial leads show normal R Waves in V1-4, deep S waves in V1-2, small S waves in V3-4 and no S waves in

V5-6. There is diminution of the precordial complexes in V3, 4, 5 and 6. These findings are consistent with a dextroposition of the heart. The blood investigations were unremarkable. The findings from physical examination, chest radiograph and 12 lead electrocardiogram are consistent with Poland's Syndrome. As the patient was otherwise well and not bothered by her condition, no treatment was initiated for her.

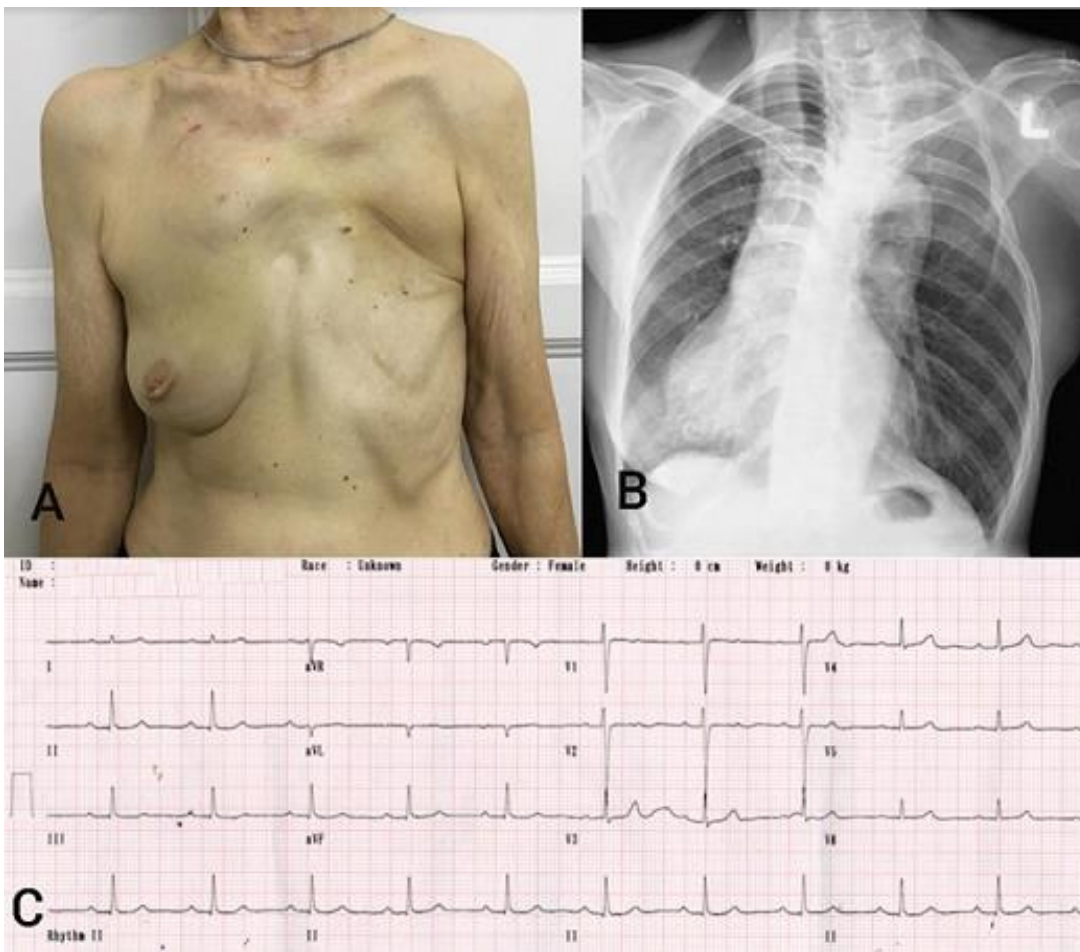


Figure 1: A) photograph of patient's chest with Poland's syndrome; B) chest radiograph of the patient; C) 12-lead electrocardiogram of the patient