

Images in clinical medicine

Urticaria multiforme-like: a COVID-19 infection

Cristiana Canelas Mendes, Rita Pimenta

Corresponding author: Cristiana Canelas Mendes, Department of Internal Medicine 2, Centro Hospitalar Universitário de Lisboa Norte, Hospital de Santa Maria, Lisboa, Portugal. cristianacmm@gmail.com

Received: 29 Oct 2020 - **Accepted:** 17 Nov 2020 - **Published:** 30 Nov 2020

Keywords: COVID-19, cutaneous manifestations, skin

Copyright: Cristiana Canelas Mendes et al. Pan African Medical Journal (ISSN: 1937-8688). This is an Open Access article distributed under the terms of the Creative Commons Attribution International 4.0 License (<https://creativecommons.org/licenses/by/4.0/>), which permits unrestricted use, distribution, and reproduction in any medium, provided the original work is properly cited.

Cite this article: Cristiana Canelas Mendes et al. Urticaria multiforme-like: a COVID-19 infection. Pan African Medical Journal. 2020;37(286). 10.11604/pamj.2020.37.286.26740

Available online at: <https://www.panafrican-med-journal.com//content/article/37/286/full>

Urticaria multiforme-like: a COVID-19 infection

Cristiana Canelas Mendes^{1,&}, Rita Pimenta²

¹Department of Internal Medicine 2, Centro Hospitalar Universitário de Lisboa Norte, Hospital de Santa Maria, Lisboa, Portugal, ²Department of Dermatology, Centro Hospitalar Universitário de Lisboa Norte, Hospital de Santa Maria, Lisboa, Portugal

&Corresponding author

Cristiana Canelas Mendes, Department of Internal Medicine 2, Centro Hospitalar Universitário de Lisboa Norte, Hospital de Santa Maria, Lisboa, Portugal

Image in medicine

An 18-year-old, otherwise healthy woman, presented to the emergency department with a three-day history of acute-onset diffuse rash. She denied recent introduction of new drugs or dermocosmetic products and previously adverse drug reactions or allergies. She hadn't had any known contact with anyone with confirmed SARS-CoV-2 infection. On examination, she had a temperature of 38.6°C. Physical examination showed a disseminated, asymptomatic and not evanescent annular erythematous urticarial papules and plaques, some with targetoid appearance, mostly located at the back (A), chest (B), inguinal zone (C), distal portions of upper (D) and lower limbs and forehead. The palmoplantar

skin and mucous membranes were spared. Laboratory tests showed d-dimer elevation (0.43 $\mu\text{g/ml}$, normal range 0.0-0.25 $\mu\text{g/ml}$). Chest radiography and computed tomographic pulmonary angiography was normal. A reverse-transcriptase-polymerase-chain-reaction test for severe acute respiratory syndrome coronavirus 2, performed on a nasopharyngeal swab, was positive. A diagnosis of COVID-19 infection was

made. On the sixth day of follow-up, fevers and rash were disappeared. The particular interest of this case is the inaugural appearance of a cutaneous manifestation, before any other symptom. It is essential to take into account and promote the recognition among clinicians of this possible skin manifestation of COVID-19, because an early diagnosis, could contribute to break the chain of transmission immediately.

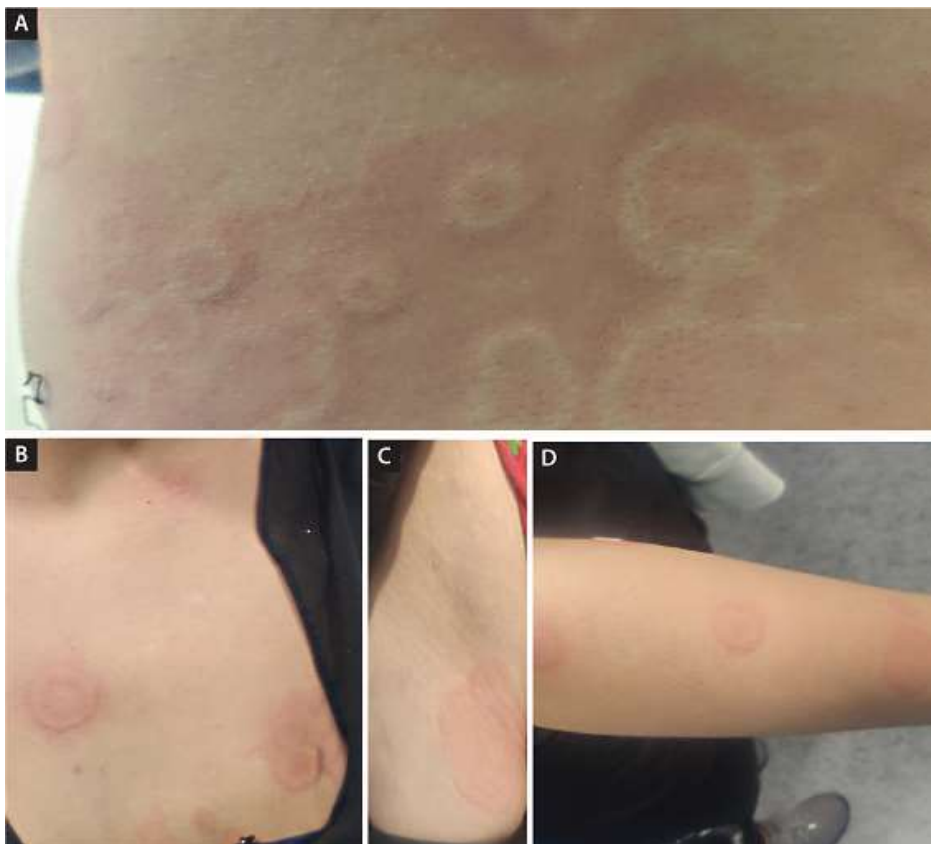


Figure 1: urticaria multiforme-like: a COVID-19 infection