

## Images in medicine

### Hyperparathyroidism related to an ectopic parathyroid adenoma

Attifi Hicham<sup>1, &</sup>, Messary Abdelhamid<sup>1</sup>

<sup>1</sup>Department of UNT, Military Hospital Moulay Ismail, Meknes, Morocco

<sup>&</sup>Corresponding author: Attifi Hicham, Department of UNT, Military Hospital Moulay Ismail, Meknes, Morocco

Key words: Hyperparathyroidism, adenoma, hypercalcemia

Received: 30/06/2014 - Accepted: 27/09/2014 - Published: 08/10/2014

**Pan African Medical Journal. 2014; 19:135 doi:10.11604/pamj.2014.19.135.4931**

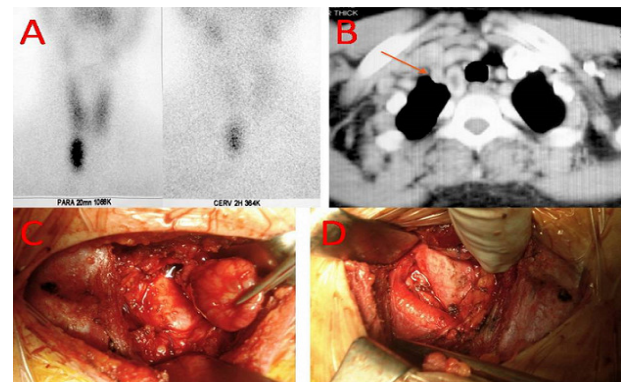
This article is available online at: <http://www.panafrican-med-journal.com/content/article/19/135/full/>

© Attifi Hicham et al. The Pan African Medical Journal - ISSN 1937-8688. This is an Open Access article distributed under the terms of the Creative Commons Attribution License (<http://creativecommons.org/licenses/by/2.0>), which permits unrestricted use, distribution, and reproduction in any medium, provided the original work is properly cited.

#### Image in medicine

A 46-year-old female with a history of muscle weakness, nephrolithiasis and peptic ulcer. She was found to have hypercalcemia (115 mg/l), hypophosphoremia (16 mg/l) and increased PTH serum level (1090 pg/l). In order to discriminate between PH and pseudohyperparathyroidism, a solid-phase, two site chemiluminescent enzyme-labeled immunometric assay directed towards the intact PTH molecule was used and a diagnosis of primary hyperparathyroidism was made. Several studies were performed with the purpose to achieve a pre-operative localization of the oversecreting parathyroid tumor. A cervical sonography showed a normal thyroid gland and no evidence of the tumor was found in the neck. Therefore a 99-Tc sesta MIBI was carried out and an accumulation area projected onto the anterior mediastinum was demonstrated (A). Finally a computed tomography scan of the thorax revealed a 4 cm nodule, in the thymic and paratracheal region of the anterior mediastinum (B). The patient underwent surgical resection of the tumor by a lower cervicotomy approach (C,D). Intraoperative parathyroid hormone measurements show a appropriate decrease in PTH levels. A 4x3x2 cm surgical specimen of a parathyroid tissue mass was removed. The anatomopathological examination confirmed the diagnosis of parathyroid adenoma. The post-operative course was uneventful and the patient was discharged in 4th post-operative day with an excellent functional and cosmetic result. A quarterly follow-up was started. PTH serum

level and calcemia have been within normal ranges all through 18 months after surgery.



**Figure 1:** A) a 99-Tc sestaMIBI demonstrating an accumulation area projected onto the anterior mediastinum; B) a computed tomography scan of the thorax revealing a 4 cm nodule, in the thymic and paratracheal region of the anterior mediastinum; C) operative view objectifying the resection of the parathyroid adenoma; D) operative view demonstrating the ectopic area of the parathyroid adenoma