

## Images in medicine

### Coffee bean sign, whirl sign and bird's beak sign in the diagnosis of sigmoid volvulus

Mehmet Yigit<sup>1,§</sup>, Kenan Ahmet Turkdogan<sup>1</sup>

<sup>1</sup>Bezmialem Vakif University, Department of Emergency Medicine, Istanbul, Turkey

<sup>§</sup>Corresponding author: Mehmet Yigit, Bezmialem Vakif University, Department of Emergency Medicine, Istanbul, Turkey

Key words: Coffee bean, sigmoid volvulus, whirl

Received: 26/07/2014 - Accepted: 01/09/2014 - Published: 23/09/2014

**Pan African Medical Journal. 2014; 19:56 doi:10.11604/pamj.2014.19.56.5142**

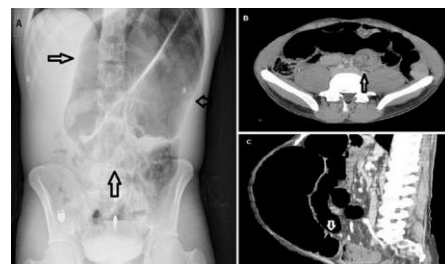
This article is available online at: <http://www.panafrican-med-journal.com/content/article/19/56/full/>

© Mehmet Yigit et al. The Pan African Medical Journal - ISSN 1937-8688. This is an Open Access article distributed under the terms of the Creative Commons Attribution License (<http://creativecommons.org/licenses/by/2.0>), which permits unrestricted use, distribution, and reproduction in any medium, provided the original work is properly cited.

### Image in medicine

The patient, a 28-year-old man who had presented to our Emergency Department (ED) with constant abdominal pain and distension for one day, had no previous medical or surgical history. He denied that he had any nausea, vomiting, diarrhea or constipation. At admission, his physical examination revealed hypertension (TA: 152/97 mmHg) and a distended abdomen with generalised tenderness and hypoactive bowel sounds. There was no fever, abdominal guarding, rebound or rigidity. Laboratory results were within normal limits. A plain radiograph of the abdomen revealed a "coffee bean" sign. We also observed an impressive picture of a typical "whirl" sign and a "bird's beak" sign on an emergent abdominal computed tomography (CT) scan. Also, his CT scan revealed marked distension and a twisted loop of sigmoid colon. Sigmoid volvulus (SV) was diagnosed rapidly with these characteristic radiological signs. Subsequently, with flexible sigmoidoscopy, the patient was successfully decompressed and detorsioned. SV is potentially life-threatening and requires emergency intervention. It is the third leading cause of colon obstruction in adults after cancer and diverticulitis. The primary

emergency therapy for uncomplicated SV is endoscopic detorsion and decompression. Emergency physicians in particular should be aware of the typical radiographic CT signs, "coffee bean," "whirl" and "bird's beak," which are indicative of SV and which will allow them to easily diagnose this condition in cases of acute abdominal obstruction. If emergency physicians delay diagnosis, the patients might require emergency surgical intervention.



**Figure 1:** Coffee bean sign (A), whirl sign (B) and bird's beak sign (C) in the diagnosis of sigmoid volvulus