

Images in clinical medicine



Congenital arteriovenous malformation of upper trunk in a child

 Rohan Kumar Singh,  Prerna Anup Patwa

Corresponding author: Rohan Kumar Singh, Department of Radiodiagnosis, Jawaharlal Nehru Medical College, Datta Meghe Institute of Medical Sciences, Sawangi (Meghe), Wardha, India. rohan.singh@dmimsu.edu.in

Received: 02 Jun 2021 - **Accepted:** 24 Jun 2021 - **Published:** 06 Jul 2021

Keywords: Arteriovenous malformation, trunk, congenital, pediatric

Copyright: Rohan Kumar Singh et al. Pan African Medical Journal (ISSN: 1937-8688). This is an Open Access article distributed under the terms of the Creative Commons Attribution International 4.0 License (<https://creativecommons.org/licenses/by/4.0/>), which permits unrestricted use, distribution, and reproduction in any medium, provided the original work is properly cited.

Cite this article: Rohan Kumar Singh et al. Congenital arteriovenous malformation of upper trunk in a child. Pan African Medical Journal. 2021;39(170). 10.11604/pamj.2021.39.170.30143

Available online at: <https://www.panafrican-med-journal.com//content/article/39/170/full>

Congenital arteriovenous malformation of upper trunk in a child

Rohan Kumar Singh^{1,&}, Prerna Anup Patwa¹

¹Department of Radiodiagnosis, Jawaharlal Nehru Medical College, Datta Meghe Institute of Medical Sciences, Sawangi (Meghe), Wardha, India

&Corresponding author

Rohan Kumar Singh, Department of Radiodiagnosis, Jawaharlal Nehru Medical College, Datta Meghe Institute of Medical Sciences, Sawangi (Meghe), Wardha, India

Image in medicine

A 2-year-old male child was brought by his mother to outpatient Department of Surgery with chief complains of a swelling in the upper back on left side since birth. Further history suggested, the swelling was small in size since birth with associated mild tenderness and it gradually started increasing in size. On clinical examination, the swelling was pulsatile in nature, soft in consistency with mild reddish discolouration and ulceration of the overlying skin; however, there was no local rise of temperature. The swelling was superficial to the muscle plane and measured approximately 5.5 x 4.7 cm in size. For further investigation, the child

was referred to the Department of Radiodiagnosis for ultrasonography. On ultrasound, there were

multiple anechoic cystic areas showing increased vascularity on colour Doppler.

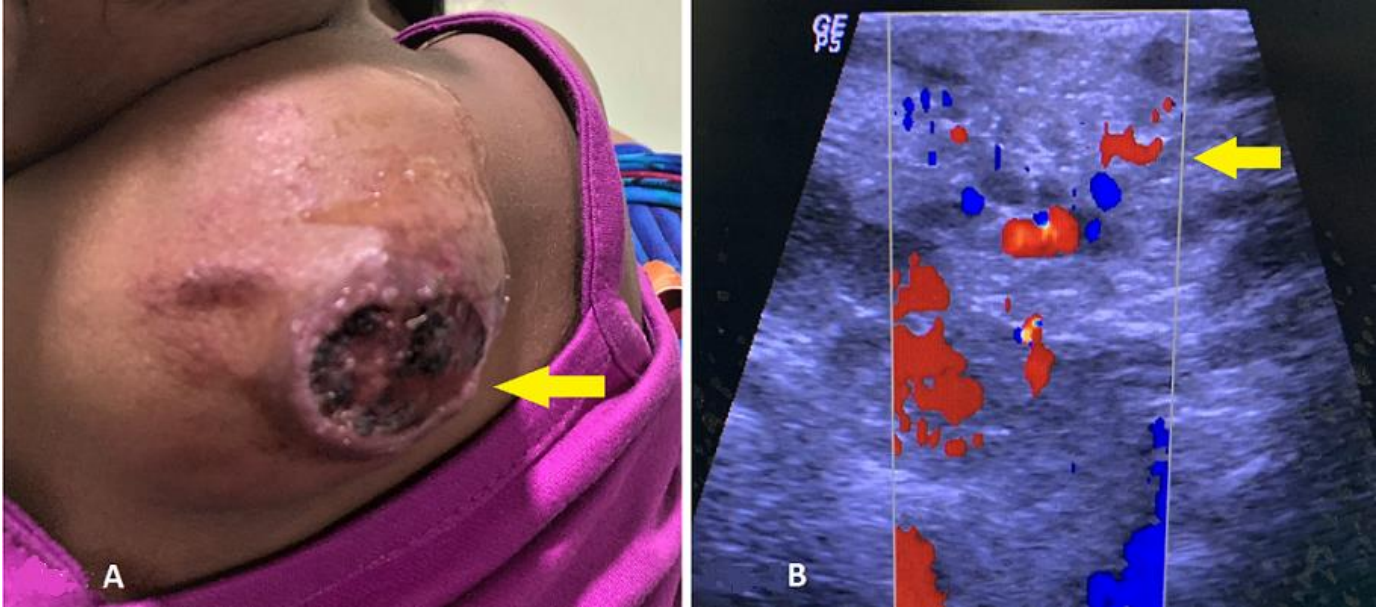


Figure 1: A) clinical image of the upper back of the child showing a large reddish mass lesion with ulceration (arrow); B) ultrasound image showing multiple anechoic cystic areas with Doppler showing increased vascularity (arrow) - arteriovenous malformation