

Images in clinical medicine



Unilateral clubfoot with amniotic band in-utero

 Prerna Anup Patwa,  Gaurav Vedprakash Mishra

Corresponding author: Prerna Anup Patwa, Department of Radiodiagnosis, Jawaharlal Nehru Medical College, Datta Meghe Institute of Medical Sciences, Sawangi (Meghe), Wardha, India. drprernapatwa@gmail.com

Received: 06 Jun 2021 - **Accepted:** 20 Jun 2021 - **Published:** 06 Jul 2021

Keywords: Clubfoot, amniotic band, congenital talipes equinovarus

Copyright: Prerna Anup Patwa et al. Pan African Medical Journal (ISSN: 1937-8688). This is an Open Access article distributed under the terms of the Creative Commons Attribution International 4.0 License (<https://creativecommons.org/licenses/by/4.0/>), which permits unrestricted use, distribution, and reproduction in any medium, provided the original work is properly cited.

Cite this article: Prerna Anup Patwa et al. Unilateral clubfoot with amniotic band in-utero. Pan African Medical Journal. 2021;39(169). 10.11604/pamj.2021.39.169.30215

Available online at: <https://www.panafrican-med-journal.com//content/article/39/169/full>

Unilateral clubfoot with amniotic band in-utero

Prerna Anup Patwa^{1,&}, Gaurav Vedprakash Mishra¹

¹Department of Radiodiagnosis, Jawaharlal Nehru Medical College, Datta Meghe Institute of Medical Sciences, Sawangi (Meghe), Wardha, India

&Corresponding author

Prerna Anup Patwa, Department of Radiodiagnosis, Jawaharlal Nehru Medical College, Datta Meghe Institute of Medical Sciences, Sawangi (Meghe), Wardha, India

Image in medicine

A 28-year-old primigravida with 22.3 weeks of gestation came for dedicated level II ultrasonography for anomaly scan to the antenatal clinic of AVBRH, Sawangi (India). The previous antenatal check-up was not done. The patient neither had a history of maternal systemic diseases like diabetes or hypertension nor history of any trauma or drug intake during pregnancy. There was no family history of congenital anomalies. On obstetric examination, the uterus was of about 20 weeks in size. On ultrasonography, single live intrauterine foetus with an average gestational age of 21 weeks 5 days corresponding to effective foetal weight of 396 grams showing right foot abnormality with persistent adduction and inward

rotation suggestive of clubfoot with mild pyelectasis of left kidney was noted. However, there was no obvious abnormality of left foot. There was

amniotic band in right lower quadrant of gravid uterus.

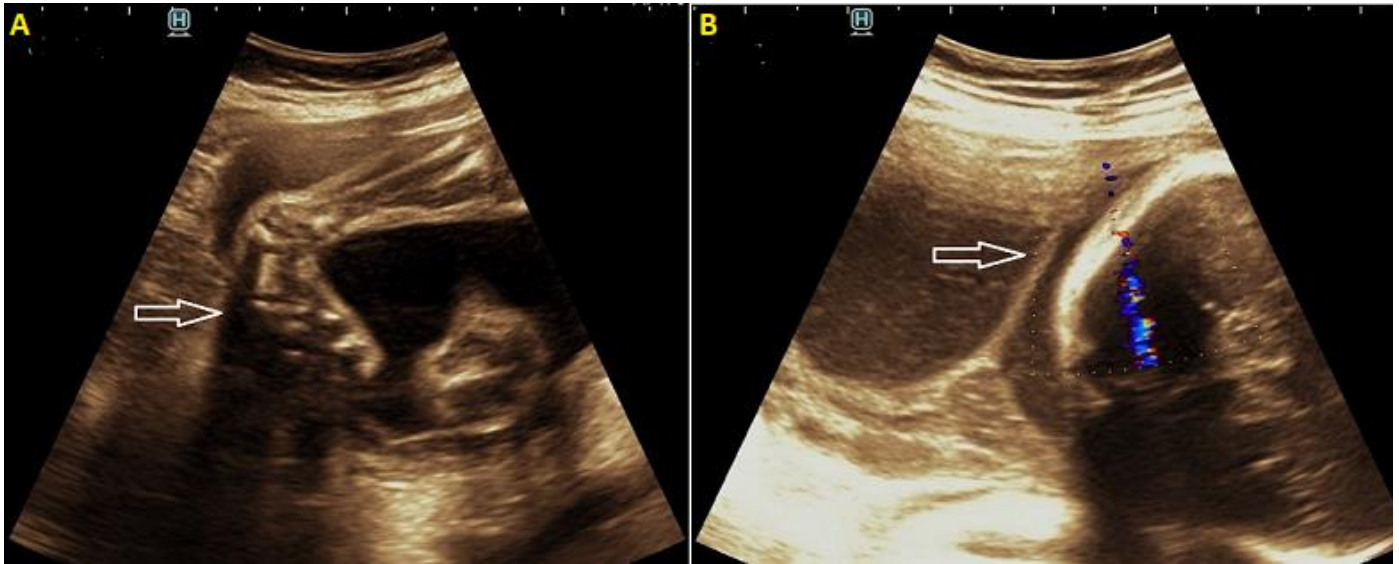


Figure 1: (A) ultrasound image showing medially rotated right foot suggesting club foot/CTEV; (B) ultrasound image showing a linear echogenic band at the lower end of uterus - amniotic band with an intact chorionic membrane