

Images in clinical medicine

Newborn with massive right eye proptosis revealing quintessence cystic orbital teratoma

Rohan Kumar Singh,  Gaurav Vedprakash Mishra

Corresponding author: Rohan Kumar Singh, Department of Radiodiagnosis, Jawaharlal Nehru Medical College, Datta Meghe Institute of Medical Sciences, Sawangi (Meghe), Wardha, India. rohan.singh@dmimsu.edu.in

Received: 26 May 2021 - **Accepted:** 29 May 2021 - **Published:** 07 Jun 2021

Keywords: Orbital teratoma, ultrasonography, orbital mass, neonate

Copyright: Rohan Kumar Singh et al. Pan African Medical Journal (ISSN: 1937-8688). This is an Open Access article distributed under the terms of the Creative Commons Attribution International 4.0 License (<https://creativecommons.org/licenses/by/4.0/>), which permits unrestricted use, distribution, and reproduction in any medium, provided the original work is properly cited.

Cite this article: Rohan Kumar Singh et al. Newborn with massive right eye proptosis revealing quintessence cystic orbital teratoma. Pan African Medical Journal. 2021;39(110). 10.11604/pamj.2021.39.110.30023

Available online at: <https://www.panafrican-med-journal.com//content/article/39/110/full>

Newborn with massive right eye proptosis revealing quintessence cystic orbital teratoma

Rohan Kumar Singh^{1,&}, Gaurav Vedprakash Mishra¹

¹Department of Radiodiagnosis, Jawaharlal Nehru Medical College, Datta Meghe Institute of Medical Sciences, Sawangi (Meghe), Wardha, India

&Corresponding author

Rohan Kumar Singh, Department of Radiodiagnosis, Jawaharlal Nehru Medical College, Datta Meghe Institute of Medical Sciences, Sawangi (Meghe), Wardha, India

Image in medicine

A full-term 2-day-old female neonate weighing about 2.17 kilogram, born by normal delivery at 37 weeks of gestation was referred to the ophthalmology with a massive mass of the right eye. On clinical examination, there was severe proptosis of the right eye with a positive transillumination test with normal left eye. The orbital mass was hard in consistency with few soft areas and it was covering the right midface. The eyeball was pushed on anteroinferior side with severe conjunctival chemosis and corneal erosion due to exposure to keratopathy with absent papillary reflex. For further routine investigation

the baby was referred to the Department of Radiology for a B-scan ultrasound. On ultrasound, multiple anechoic cystic areas were seen anterior

to globe pushing it anteroinferior, the hetero-echoic lesion was seen filling right eyeball and lesion was involving ocular muscles.

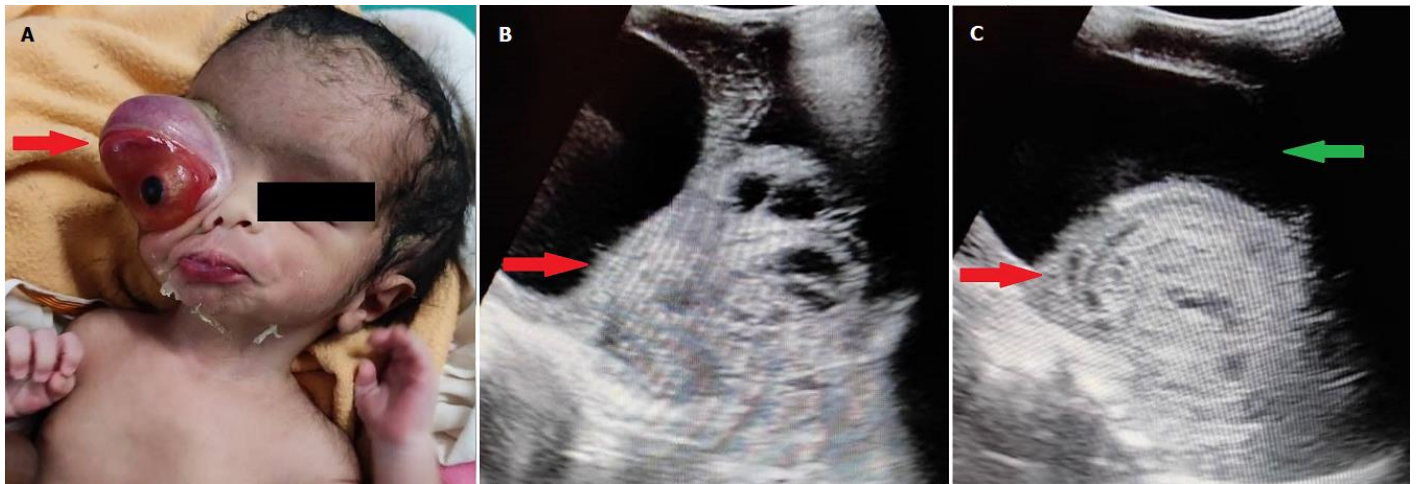


Figure 1: A) severe right eye proptosis with eyeball pushed out (red arrow); heterogeneous lesion with multiple anechoic cystic areas (red arrow); B) ultrasound images; C) heterogeneous well-defined lesion (red arrow), globe is pushed anteriorly (green arrow)