

Images in clinical medicine



A 60-year-old female with giant retroperitoneal liposarcoma

 Danilo Coco,  Silvana Leanza

Corresponding author: Danilo Coco, Department of General Surgery, Ospedali Riuniti Marche Nord, Pesaro, Italy. webcostruction@msn.com

Received: 10 May 2021 - **Accepted:** 17 May 2021 - **Published:** 26 May 2021

Keywords: Giant, retroperitoneal, liposarcoma

Copyright: Danilo Coco et al. Pan African Medical Journal (ISSN: 1937-8688). This is an Open Access article distributed under the terms of the Creative Commons Attribution International 4.0 License (<https://creativecommons.org/licenses/by/4.0/>), which permits unrestricted use, distribution, and reproduction in any medium, provided the original work is properly cited.

Cite this article: Danilo Coco et al. A 60-year-old female with giant retroperitoneal liposarcoma. Pan African Medical Journal. 2021;39(77). 10.11604/pamj.2021.39.77.29777

Available online at: <https://www.panafrican-med-journal.com//content/article/39/77/full>

A 60-year-old female with giant retroperitoneal liposarcoma

Danilo Coco^{1,&}, Silvana Leanza²

¹Department of General Surgery, Ospedali Riuniti Marche Nord, Pesaro, Italy, ²Department of General Surgery, Carlo Urbani Hospital, Jesi, Ancona, Italy

&Corresponding author

Danilo Coco, Department of General Surgery, Ospedali Riuniti Marche Nord, Pesaro, Italy

Image in medicine

Retroperitoneal tumors give non-specific symptoms until they have reached a substantial size. Liposarcoma and leiomyosarcoma are the most common retroperitoneal carcinoma amount of 70% and 15% respectively. Hodgkin's and non-Hodgkin lymphoma and epithelial tumors or metastatic disease are less common. We present a 60-year-old female who was referred to the Emergency Department with acute onset of abdominal distension, nausea, vomiting, right back pain and lipothymia. She had a medical history of essential hypertension and diabetes mellitus. On physical examination, she had a good performance

status, arterial blood pressure was 90/60 mmHg, pulse rate was 120 b/min, oxygen saturation of 93%. Blood exams demonstrated no lymphocytes $4 \times 10^3/\text{mmc}$, hemoglobin 7g/dl. Physical examination of the abdomen revealed a giant non-tender mass in the left and midline quadrants. The patient was transfused with 4 units of blood. Abdomen computed tomography (CT) scan revealed a retroperitoneal mass of 35 cm involving the stomach, the spleen, the kidney and surrounding the vena cava (A). He was referred to a Multidisciplinary Team (MDT) to perform a CT scan

Fine-Needle-Aspiration (FNA) which confirms a well differentiated liposarcoma. A laparotomy was performed with total excision of retroperitoneal mass (B). At 6th day, the patient was in good clinical condition and he was discharged. Hystopathological finding: well differentiated liposarcoma. French Federation of Cancer Centers Sarcoma Group: Grade 1 tumor differentiation: 1; mitotic count: 1; tumor necrosis: 0 (C).

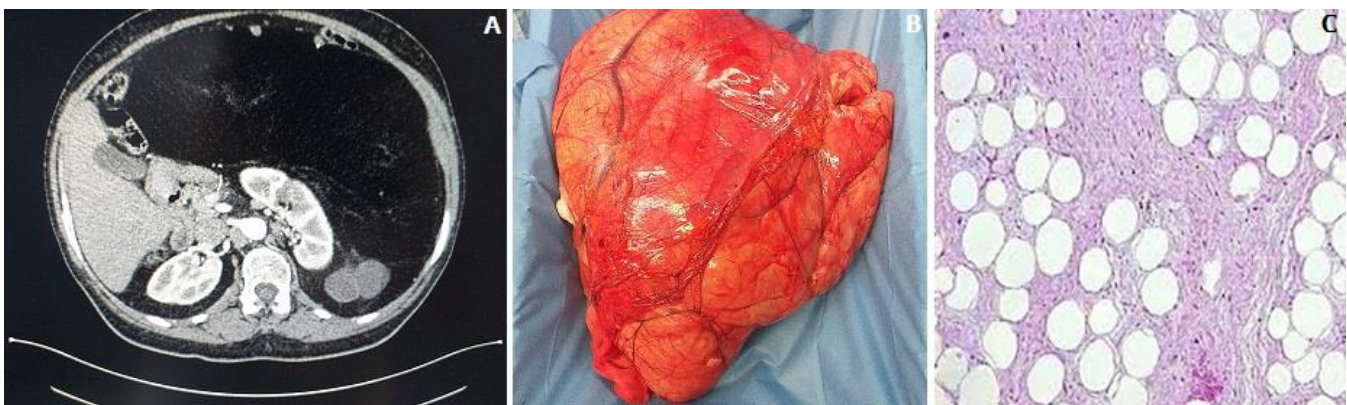


Figure 1: abdomen CT scan revealed a retroperitoneal mass of 30 cm involving the stomach, the spleen, the kidney and surrounding the vena cava (A); total excision of retroperitoneal mass (B); well differentiated liposarcoma, French Federation of Cancer Centers Sarcoma Group: Grade 1 Tumor differentiation: 1; Mitotic count: 1; Tumor necrosis: 0 (C)