

**Images in clinical medicine**

# A 77 year old man with gangrenous cholecystitis and incidental findings of multiple bilobar liver lipomatosis

Danilo Coco, Silvana Leanza

**Corresponding author:** Danilo Coco, Department of General Surgery, Ospedali Riuniti Marche Nord, Pesaro, Italy. webcostruction@msn.com

**Received:** 24 Apr 2020 - **Accepted:** 04 May 2020 - **Published:** 08 Sep 2020

**Keywords:** Old man, liver-disease, steato-hepatitis, Madelung's disease

**Copyright:** Danilo Coco et al. Pan African Medical Journal (ISSN: 1937-8688). This is an Open Access article distributed under the terms of the Creative Commons Attribution International 4.0 License (<https://creativecommons.org/licenses/by/4.0/>), which permits unrestricted use, distribution, and reproduction in any medium, provided the original work is properly cited.

**Cite this article:** Danilo Coco et al. A 77 year old man with gangrenous cholecystitis and incidental findings of multiple bilobar liver lipomatosis. Pan African Medical Journal. 2020;37(31). 10.11604/pamj.2020.37.31.23071

**Available online at:** <https://www.panafrican-med-journal.com//content/article/37/31/full>

## A 77 year old man with gangrenous cholecystitis and incidental findings of multiple bilobar liver lipomatosis

Danilo Coco<sup>1,&</sup>, Silvana Leanza<sup>2</sup>

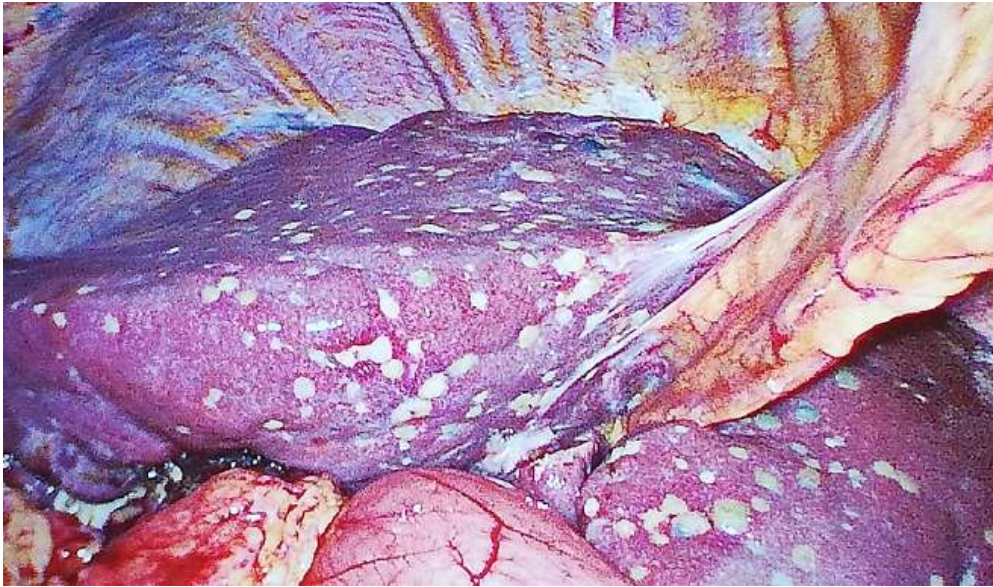
<sup>1</sup>Department of General Surgery, Ospedali Riuniti Marche Nord, Pesaro, Italy, <sup>2</sup>Department of General Surgery, Carlo Urbani Hospital, Jesi, Ancona, Italy

### **&Corresponding author**

Danilo Coco, Department of General Surgery, Ospedali Riuniti Marche Nord, Pesaro, Italy

## *Image in medicine*

*A 77-year-old man was evaluated at the hospital because of fever, vomiting and upper right quadrant pain. CT evaluation revealed acute cholecystitis with peri-cholecystic fluid. The patient was admitted in the operating room where an emergency laparoscopic cholecystectomy was performed. During laparoscopy an incidental finding of bilobar liver lipomatosis was found. Non-Alcoholic-Fatty-Liver-Disease (NAFLD) or Non-Alcoholic-Steato-Hepatitis (NASH) or Madelung's disease. A diagnosis was not made.*



**Figure 1:** incidental findings of multiple bilobar liver lipomatosis during laparoscopic cholecystectomy