

## Case report

### Isolated schwannoma of the urinary bladder: a case report and review of the literature



Hamid Nasrollahi<sup>1</sup>, Ali Ariaifar<sup>2</sup>, Faisal Ahmed<sup>3</sup>, Maral Mokhtari<sup>4</sup>, Ali Eslahi<sup>2,8</sup>, Mansour Ansari<sup>5</sup>, Umayir Chowdhury<sup>6</sup>

<sup>1</sup>Radiation Oncology Department, Shiraz University of Medical Sciences, Shiraz, Iran, <sup>2</sup>Department of Urology, Shiraz University of Medical Sciences, Shiraz, Iran, <sup>3</sup>Urology Research Center, Al-Thora General Hospital, Department of Urology, Ibb University of Medical Sciences, Ibb, Yemen, <sup>4</sup>Pathology Department, Shahid Faghihi Hospital, Shiraz University of Medical Sciences, Shiraz Iran, <sup>5</sup>Radiation Oncology, Breast Diseases Research Center, Shiraz University of Medical Sciences, Shiraz Iran, <sup>6</sup>Student Research Committee, Shiraz University of Medical Sciences, Shiraz, Iran

<sup>8</sup>Corresponding author: Ali Eslahi, Department of Urology, Shiraz University of Medical Sciences, Shiraz, Iran

Key words: Bladder, transurethral resection, schwannoma

Received: 22 Nov 2018 - Accepted: 17 Mar 2020 - Published: 08 Apr 2020

#### Abstract

The urinary bladder schwannoma is an extremely rare primary urologic tumor. Schwannoma arises from the Schwann's cells in the nerve sheaths and is almost associated with von Recklinghausen's disease. We report a case of schwannoma in a 35-year old female who presented with urinary frequency for 2 months with absence of evidence of von Recklinghausen disease and successfully treated with transurethral resection of bladder lesion (TUR\_B). To the best of our knowledge, this represents only the 10<sup>th</sup> case of benign schwannoma of the urinary bladder in a patient without von Recklinghausen disease. We report a case of an isolated schwannoma of the urinary bladder, and also searched the English literature as we had access to bladder schwannoma.

**Pan African Medical Journal. 2020;35:108. doi:10.11604/pamj.2020.35.108.17745**

This article is available online at: <http://www.panafrican-med-journal.com/content/article/35/108/full/>

© Hamid Nasrollahi et al. The Pan African Medical Journal - ISSN 1937-8688. This is an Open Access article distributed under the terms of the Creative Commons Attribution License (<http://creativecommons.org/licenses/by/2.0>), which permits unrestricted use, distribution, and reproduction in any medium, provided the original work is properly cited.

## Introduction

---

Peripheral nerve tumors are rare and may arise from the Schwann cells, ganglion cell or capillaries of the nerve cells tumors; among them, schwannoma which is the most common tumor of the peripheral nerves is a benign tumor [1,2]. These tumors may occur intracranially and the most common type of them are acoustic schwannoma [2]. It can occur in every part of the body and the most common location of peripheral schwannoma is lower extremities [3,4]. The majority of bladder cancer cases are transitional cell carcinoma and other less common tumors are squamous cell carcinoma (SCC) and adenocarcinoma [5]. Bladder schwannoma is a rare disease, and herein we report a case of isolated schwannoma of the urinary bladder; we also searched the English literature as we had access to bladder schwannoma.

## Patient and observation

---

The patient was a 35-year old female who presented with urinary frequency for 2 months. Her past medical history showed a nonsmoking history and no significant family history. The physical examination was unremarkable. She was treated as urinary tract infection, but there was no improvement in her symptoms. Urine analysis and culture were performed several times that was negative for infection. Other laboratory data were also insignificant. Through a routine evaluation, urinary system ultrasonography (US) revealed a bladder lesion measuring 7 mm. In order to confirm the diagnosis, magnetic resonance imaging (MRI) of the abdomen and pelvic cavity was done; it revealed a lesion in the dome of the bladder (Figure 1). To confirm the diagnosis and for histopathological examination, the patient underwent Transurethral Resection of Bladder Tumor (TURBT) in April 2018. Before starting the procedure, the urethra was dilated till Fr: 28; at first, the tumor location was specified by cystoscopy. Then, it was resected by monopolar cautery from superficial to deeper parts with removal of the muscle layers. Proper bleeders were taken and three way Foley catheter was applied for a continuous irrigation. The patient was transferred to the recovery room with complete stability. The histopathology slides show a well-defined mass composed of bland looking spindle cells. Subsequent immunohistochemistry (IHC) was done which showed diffuse immunoreactivity for S100, but other markers including smooth muscle actin (SMA), desmin, cytokeratin, CD34 and beta catenin were negative. Ki67 was 2-3%, so the diagnosis of schwannoma was confirmed (Figure 2, Figure 3, Figure 4). Then, the neck, abdomen,

pelvic and chest computed tomography (CT) scans were done that were normal. Brain and spine MRI and physical examination showed no evidence of other schwannoma or evidence of neurofibromatosis. She had no history of neurofibromatosis in her family. Skin examination was normal and had no café au lait spot. She was not a case of von Recklinghausen disease.

## Discussion

---

The nerve tumors are named peripheral neural sheath tumors (PNSTs) and it may be benign or malignant. Benign PNST are schwannoma and neurofibroma [4]. Schwannoma which is a component of neurofibromatosis 2 (NF2) may occur incidentally without other criteria of NF [6]. Most of these tumors are sporadic and can occur in both sexes throughout the life and its peak incidence is the 3<sup>rd</sup> to 6<sup>th</sup> decades of life [6]. Sporadic schwannoma may occur intracranially or extracranially. The extremities, head, and neck are the most common site of sporadic cases [6,7]. Extracranial lesions may arise from the peripheral nerves, most commonly in the head and neck [7]. Patients usually have complaints that are related to a specific nerve involvement or mass effect. Sometimes, infiltration of adjacent tissues may cause the problem [2]. Treatment of extracranial schwannoma consists of observation or tumor resection, while chemotherapy is not effective in these tumors [2]. Schwannoma of the bladder is extremely rare. Treatment of this type of bladder lesions consists of transurethral or partial resection, and sometimes radiotherapy [3,8]. We found 9 cases of bladder schwannoma in the English literature (Table 1). Most patients (including our case) were females (7:11) with a mean age of 42 years old. Most of them were detected by ultrasonography and the main chief complaints were hematuria, frequency, and pain. Although MRI might be better than CT scan in detecting schwannoma, none can differentiate different types of cancers. The mean tumor size was 2.1 cm. The location of the bladder lesions in 2 cases including our case was in the dome of bladder, and in 1 case it was in the neck of the bladder. Other locations were in the bladder walls. The longest survival was 36 months and no recurrence was reported. None of the patients had received adjuvant treatment [3, 5, 8-14]. It seems that bladder schwannoma is rare with a good prognosis and the best treatment may be surgical tumor removal.

## Conclusion

---

Schwannoma of the bladder is rare as a primary urologic tumor and the optimal treatment is surgery with excellent prognosis.

## Competing interests

---

The authors declare no competing interests.

## Authors' contributions

---

Ali Ariafar: clinical, endoscopic resection of the bladder tumor, case discussion and decision on monitoring. Hamid Nasrollahi, Faisal Ahmed, Maral Mokhtari, Ali Eslahi, Mansour Ansari, Umayir Chowdhury: case discussion and decision on monitoring. All the authors have read and approved the final version of the manuscript.

## Acknowledgments

---

The authors would like to thank Shiraz University of Medical Sciences, Shiraz, Iran and also Center for Development of Clinical Research of Nemazee Hospital and Dr. Nasrin Shokrpour for editorial assistance.

## Table and figures

---

**Table 1:** characteristics of 10 cases of schwannoma of the bladder

**Figure 1:** intramural mass of 7 mm in size located in the upper posterior bladder roof which appears high/low signal on T2/T1W images, uniformly and strongly enhancing on post-contrast images

**Figure 2:** A,B) histopathology slides showing a well-defined spindle mass with bland looking nuclei, H&E, X40 and X400

**Figure 3:** diffuse S100 immunoreactivity

**Figure 4:** Ki67 immuno-labeling

## References

---

1. Skovronsky DM, Oberholtzer JC. Pathologic classification of peripheral nerve tumors. *Neurosurg Clin N Am.* 2004 Apr;15(2):157-66. **PubMed | Google Scholar**
2. Mrugala MM, Batchelor TT, Plotkin SR. Peripheral and cranial nerve sheath tumors. *Curr Opin Neurol.* 2005 Oct;18(5):604-10. **PubMed | Google Scholar**
3. Srinivasa Y, Bhat S, Paul F. Isolated Primary Schwannoma of Urinary Bladder. *J Clin Diagn Res: JCDR.* 2016 May;10(5):Pd12-3. **PubMed | Google Scholar**
4. Kim DH, Murovic JA, Tiel RL, Kline DG. Operative outcomes of 546 Louisiana State University Health Sciences Center peripheral nerve tumors. *Neurosurg Clin N Am.* 2004 Apr;15(2):177-92. **PubMed | Google Scholar**
5. Mosier AD, Leitman DA, Keylock J, Nguyen D, Grant D. Bladder schwannoma- a case presentation. *J Radiol Case Rep.* 2012 Dec;6(12):26-31. **PubMed | Google Scholar**
6. MacCollin M, Chiocca EA, Evans DG, Friedman JM, Horvitz R, Jaramillo D *et al.* Diagnostic criteria for schwannomatosis. *Neurology.* 2005 Jun 14;64(11):1838-45. **PubMed | Google Scholar**
7. El-Sherif Y, Sarva H, Valsamis H. Clinical reasoning: an unusual lung mass causing focal weakness. *Neurology.* 2012 Jan 10;78(2):e4-7. **PubMed | Google Scholar**
8. Mazdar A, Asseban M, Aboussalah H, Motia H, Elsayegh H, Iken A *et al.* Schwannoma of the urinary bladder: a case report. *Pan Afr Med J.* 2014;18:84. **PubMed | Google Scholar**
9. Cummings JM, Wehry MA, Parra RO, Levy BK. Schwannoma of the urinary bladder: a case report. *Int J Urol : official journal of the Japanese Urological Association.* 1998 Sep;5(5):496-7. **PubMed | Google Scholar**
10. Bakurov EE, Krakhotkin DV, Kucherenko OB. Isolated primary schwannoma of the urinary bladder- a case presentation. *Urol Case Rep.* 2018 May;18:29-30. **PubMed | Google Scholar**

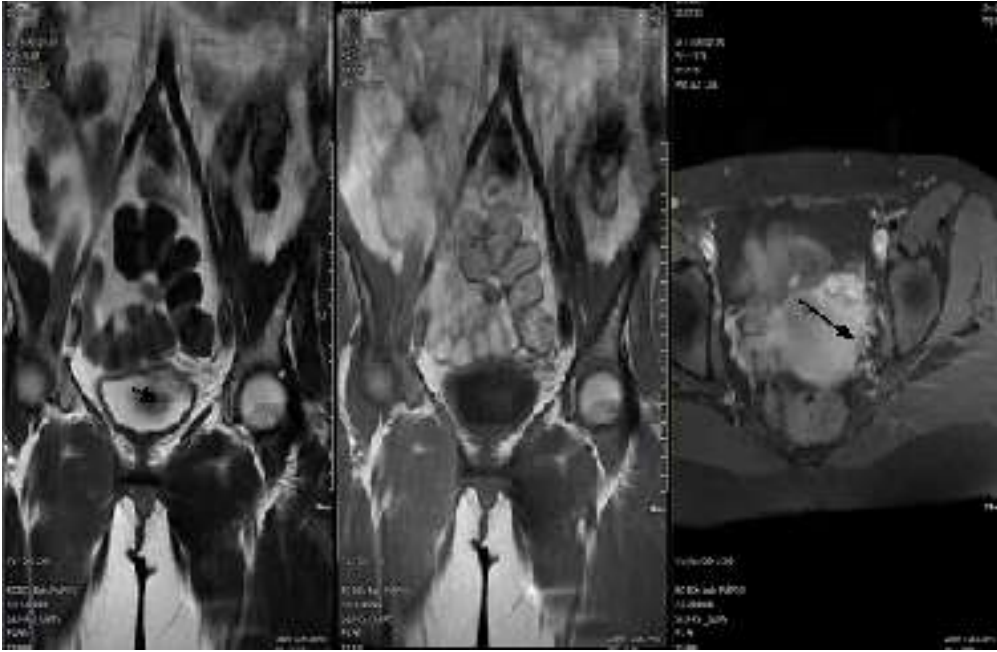
11. Geol H, Kim DW, Kim TH, Seong YK, Cho WY, Kim SD *et al.* Laparoscopic partial cystectomy for schwannoma of urinary bladder: case report. *J Endourol.* 2005 Apr;19(3):303-6. **PubMed | Google Scholar**
12. Gafson I, Rosenbaum T, Kubba F, Meis JM, Gordon AD. Schwannoma of the bladder: a rare pelvic tumour. *J Obstet Gynaecol: the journal of the Institute of Obstetrics and Gynaecology.* 2008 Feb;28(2):241-3. **PubMed | Google Scholar**
13. Ng KJ, Sherif A, McClinton S, Ewen SW. Giant ancient schwannoma of the urinary bladder presenting as a pelvic mass. *Br J Urol.* 1993 Oct;72(4):513-4. **PubMed | Google Scholar**
14. Jallad S, Ghani S, Omar MA, Motiwala H. Isolated bladder schwannoma: a rare presentation. *BMJ case reports.* 2018 Feb 14;2018. **PubMed | Google Scholar**

**Table 1:** characteristics of 10 cases of schwannoma of the bladder

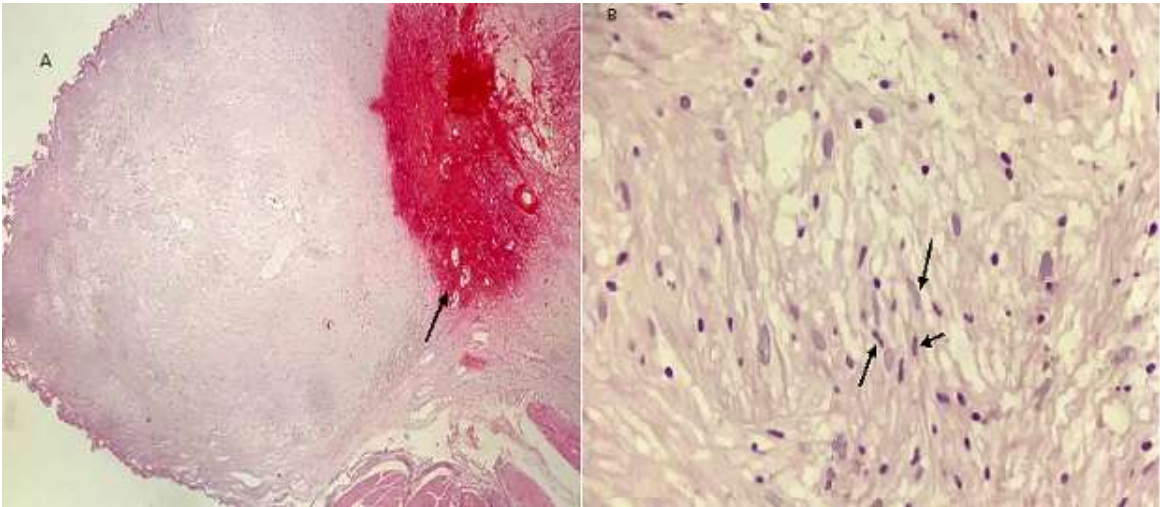
	Age/sex	Presentation	Diagnostic tool	Tumor shape	Size (cm)	Tumor location	Intervention	Survival* (Months)
Srinivasa <i>et al.</i> [3]	45/M	Hematuria	US	Polypoid	1.6	Dome of bladder	TURBT	9
Cummings <i>et al.</i> [9]	58/F	Pain, Urgency, frequency	US	Cystic lesion	4.5	Lt lateral wall	PC	36
Mosier <i>et al.</i> [5]	31/M	Pain, Hematuria	CT	Pedunculated mass	1.7	Lt lateral wall	Surgery	8
Mazdar <i>et al.</i> [8]	50/F	Hematuria	US	Solid mass	5.8	Rt lateral wall	TU	5
Bakurov <i>et al.</i> [10]	53/M	Hematuria, urgency,	MRI	Solid mass	3.5	Bladder Neck	TU	12
Geol <i>et al.</i> [11]	35/M	No symptom	US	Solid mass	3.5	Left lateral wall	PC	12
Gafson <i>et al.</i> [12]	52/F	Pain, vomiting, frequency	US	Solid mass	7	Anterior superior wall	Surgery	NA
Ng <i>et al.</i> [13]	88/F	Urgency, incontinency	US	Solid mass	20	Left side	No surgery	NA
Jallad <i>et al.</i> [14]	25/F	Dyspareunia	NA	NA	NA	NA	NA	NA
Our case	35/F	Frequency	US	Solid	1	Dome of bladder	TURBT	6

**Abbreviations:** TURBT: transurethral resection of bladder tumor; PC: partial cystectomy; US: ultrasonography; M: male; F: female; NA: not available; CT: computed tomography; MRI: magnetic resonance imaging; LT: left; RT: right

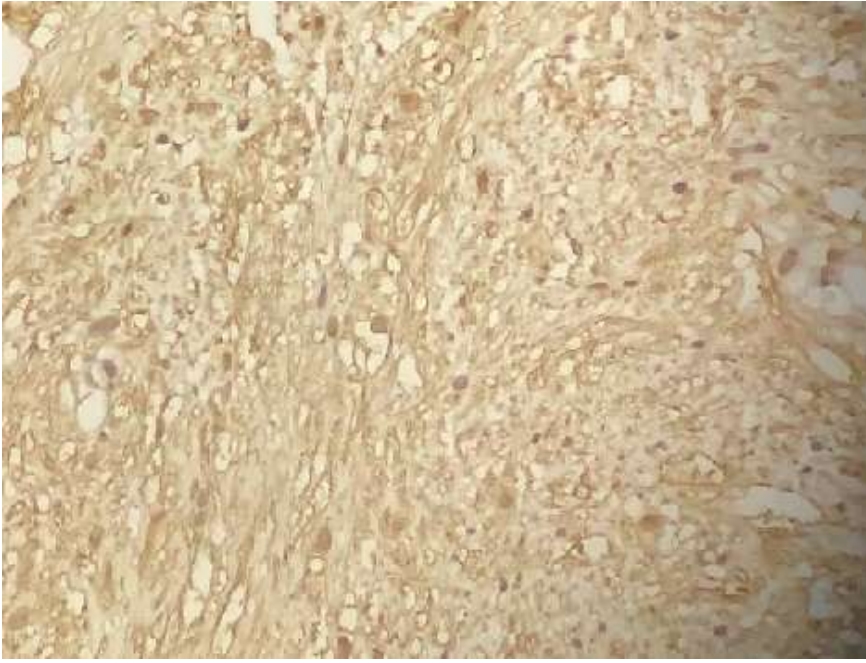
\*No recurrence detected in all the patients



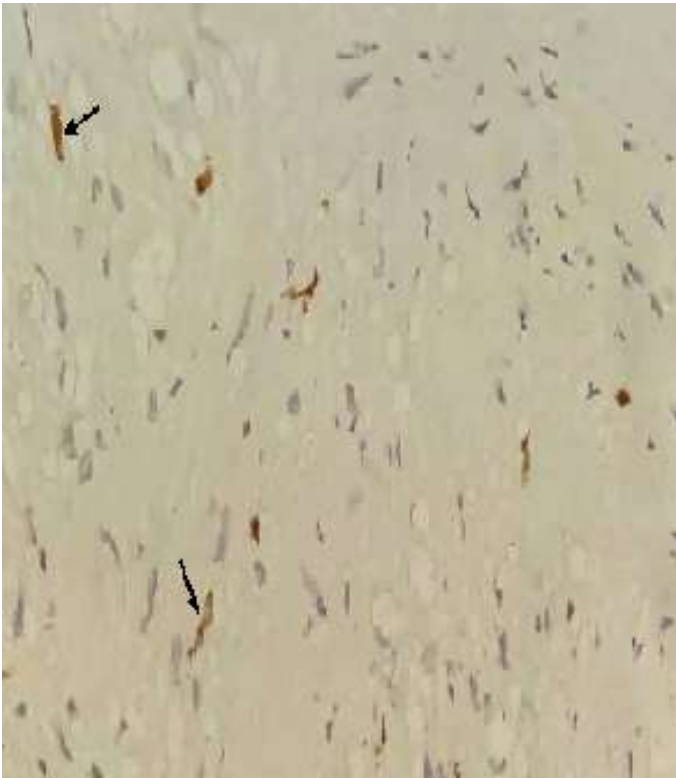**Figure 1:** intramural mass of 7 mm in size located in the upper posterior bladder roof which appears high/low signal on T2/T1W images, uniformly and strongly enhancing on post-contrast images



**Figure 2:** A,B) histopathology slides show a well-defined spindle mass with bland looking nuclei, H&E, X40 and X400



**Figure 3:** diffuse S100 immunoreactivity



**Figure 4:** Ki67 immuno-labeling