

# Images in clinical medicine

## Partners in crime: two prisoners with foreign body insertion

Androniki Kozana<sup>1,\*</sup>, Gerardina Cavallo<sup>1</sup>



<sup>1</sup>Radiology Department, Venizeleion General Hospital of Heraklion, Heraklion, Greece

\*Corresponding author: Androniki Kozana, Radiology Department, Venizeleion General Hospital of Heraklion, Heraklion, Greece

Key words: Emergency, foreign body, prisoner

Domain: Radiology, Emergency medicine

Received: 23 Apr 2020 - Accepted: 26 Apr 2020 - Published: 08 May 2020

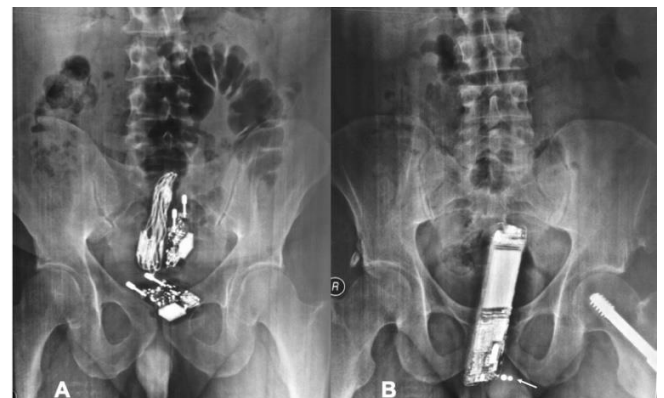
Images in clinical medicine | Volume 36, Article 10, 08 May 2020 | 10.11604/pamj.2020.36.10.23027

This article is available online at: <http://www.panafrican-med-journal.com/content/article/36/10/full/>

© Androniki Kozana et al. Pan African Medical Journal (ISSN: 1937-8688). This is an Open Access article distributed under the terms of the Creative Commons Attribution International 4.0 License (<https://creativecommons.org/licenses/by/4.0/>), which permits unrestricted use, distribution, and reproduction in any medium, provided the original work is properly cited.

### Image in clinical medicine

Two prisoners, a 35-year-old and a 42-year-old man, were admitted to the Emergency Department (ED), following court order. Upon clinical evaluation, their vital signs were normal, while digital rectal examination was suspicious for foreign bodies. Abdominal radiographs were performed and revealed that the first bore rectally two smartphone chargers with their cables (A) and the second a smartphone (B) for communication purposes. Penis pearlying is also incidentally noted (B) not unusual among prisoners to increase intercourse stimulation. Following mild sedation, all rectal foreign bodies were manually extracted and both were discharged in good health after 2-hour monitoring. It is common for prisoners to present with foreign body ingestion or insertion which may be associated with escape or self-destruction attempts, drug-dealing, acts of physical stimulation/assault. Admission may be involuntary and essential history information may be concealed. The emergency physician needs to be vigilant and familiar with the radiographic appearances of commonly encountered foreign bodies.



**Figure 1:** abdominal x-rays of(A) first prisoner bearing two smartphone chargers rectally; (B) second prisoner bearing a smartphone rectally; incidental penis pearlying (arrow)