



# Images in medicine

## Traumatic pulmonary pseudocyst: a rare complication of blunt thoracic injury

Ouissal Aissaoui<sup>1,&</sup>, Rachid Alharrar<sup>1</sup>

<sup>1</sup>Surgical ICU and Resuscitation Department P33, University Hospital of Ibn Rochd, Casablanca, Morocco

<sup>&</sup>Corresponding author: Ouissal Aissaoui, Surgical ICU and Resuscitation Department P33, University Hospital of Ibn Rochd, Casablanca, Morocco

Key words: Traumatic pulmonary pseudocyst, traumatic pneumatocele, blunt chest trauma

Received: 03/03/2019 - Accepted: 10/03/2019 - Published: 11/04/2019

**Pan African Medical Journal. 2019;32:180. doi:10.11604/pamj.2019.32.180.18592**

This article is available online at: <http://www.panafrican-med-journal.com/content/article/32/180/full/>

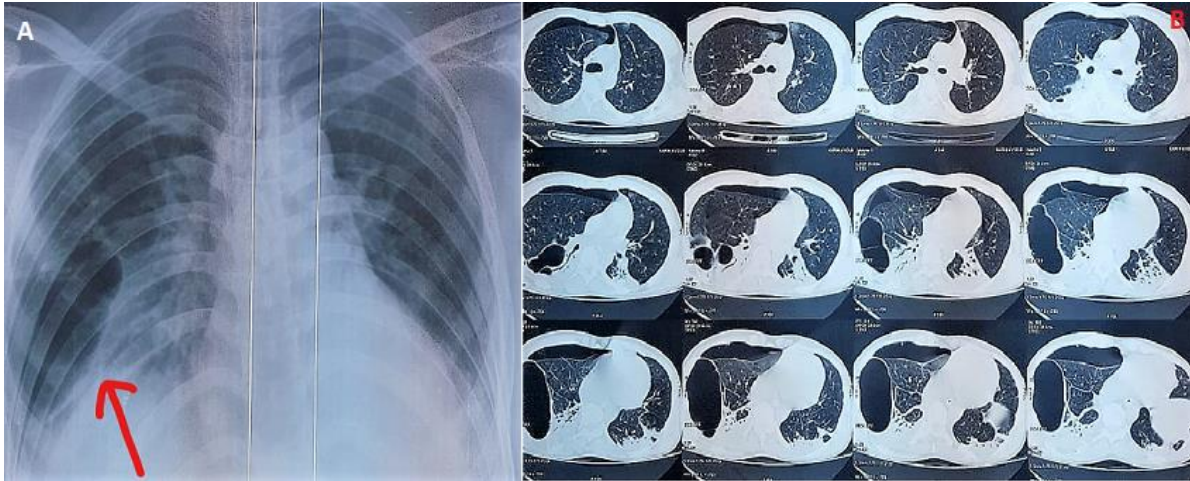
© Ouissal Aissaoui et al. The Pan African Medical Journal - ISSN 1937-8688. This is an Open Access article distributed under the terms of the Creative Commons Attribution License (<http://creativecommons.org/licenses/by/2.0>), which permits unrestricted use, distribution, and reproduction in any medium, provided the original work is properly cited.

### Image in medicine

---

Traumatic pulmonary pseudocyst is a rare and underreported complication of blunt chest trauma. It represents air trapped within a pulmonary laceration. It generally appears on radiographs as a thin-walled, air-filled cavity, with or without air-fluid levels. It is very important for emergency physicians and pediatricians to be familiar with this condition because it generally represents a benign, self-

limited condition that only requires observation. We report a case of a young man admitted in our ICU for thoracic injury consecutive to a motor vehicle accident. The chest X-Ray showed multiple large thin-walled cystic lesions. The Chest CT identified several large cavities on the right lung confirming the diagnosis of traumatic pulmonary pseudocysts. He was treated by oxygen therapy and analgesia. His condition was relatively stable and improved after few days. He was discharged 10 days later and a follow-up chest CT showed spontaneous resolution of the pseudocyst.



**Figure 1:** A) chest X-Ray: thin walled cavities; B) chest CT scan: multiple and large air filled cavities in the right lung