



Case report

Desmoplastic infantile ganglioglioma

Salma Kamoun^{1,&}, Heifa Azouz¹, Marwa Zemali², Slim Haouet¹, Nidhameddine Kchir¹

¹Department of Pathology, Rabta Hospital, Faculty of Medicine of Tunis, University of Tunis el Manar, Tunisia, ²Department of Neurosurgery, National Institute of Neurology, Tunis, Tunisia

[&]Corresponding author: Salma Kamoun, Department of Pathology, Rabta Hospital, Faculty of Medicine of Tunis, University of Tunis el Manar, Tunisia

Key words: Tumor, central nervous system, infantile desmoplastic ganglioglioma

Received: 06/05/2017 - Accepted: 02/02/2019 - Published: 11/03/2019

Abstract

The term desmoplastic infantile ganglioglioma was coined by Vandenberg et al in 1987. In their first report these authors referred to a rare, distinct brain tumor. About 60 cases of desmoplastic infantile ganglioglioma have been described in the literature since its first description. We report a case of a 6-year-old girl who was admitted for seizure without family history. Magnetic resonance imaging scan showed a hypodense area in the right temporal region. A right temporal craniotomy was performed and the tumor was excised. The pathologic examination revealed the diagnosis of desmoplastic infantile ganglioglioma.

Pan African Medical Journal. 2019;32:113. doi:10.11604/pamj.2019.32.113.12669

This article is available online at: <http://www.panafrican-med-journal.com/content/article/32/113/full/>

© Salma Kamoun et al. The Pan African Medical Journal - ISSN 1937-8688. This is an Open Access article distributed under the terms of the Creative Commons Attribution License (<http://creativecommons.org/licenses/by/2.0>), which permits unrestricted use, distribution, and reproduction in any medium, provided the original work is properly cited.

Introduction

The term desmoplastic infantile ganglioglioma (DIG) was coined by Vandenberg et al in 1987 [1]. In their first report these authors referred to a rare, distinct brain tumor. About 60 cases of DIG have been described in the literature since its first description [2]. In this work, we describe the histologic, immunohistochemical and differential diagnoses of DIG.

Patient and observation

A 6-year-old girl was admitted for seizure without family history. Neurological examination was normal. Magnetic resonance imaging scan showed a hypodense area in the right temporal region, with contrast enhancing solid as well as large cystic components (Figure 1). A right temporal craniotomy was performed and the tumor was excised. The pathologic examination revealed a markedly desmoplastic tumor, showing deposition of dense collagen fibers. The neoplastic cell population was heterogenous, composed of spindle-shaped astrocytes with a fascicular arrangement (Figure 2). These cells show intense immunoreactivity for GFAP (Figure 3). Scattered ganglion cells with copious cytoplasm and irregular nuclei were also observed, indicating neuronal differentiation (Figure 4). These neuronal cells express synaptophysin (Figure 5). No mitosis or necrosis was present.

Discussion

DIG is a supratentorial brain tumor occurring before 2 years. It has similar clinical and neuroimaging features with desmoplastic infantile astrocytoma (DIA), including a favourable prognosis, but DIA lacks ganglion cells. DIG and DIA have been categorized together as desmoplastic infantile astrocytoma/ganglioglioma in the last editions of the WHO classification. They are WHO grade 1 tumors [3]. The main histologic differential diagnoses are pleomorphic xanthoastrocytoma, gliofibroma, ganglioglioma [4] and other small blue cell tumors of the central nervous system (medulloblastoma, central nervous system primitive neuroectodermal tumors, pineoblastomas) [5]. Total resection is the best treatment and offers long term survival [6]. Dissemination of these tumors through the cerebrospinal fluid has been reported, but is rare event [7].

Anaplastic histological features as high mitotic rate, microvascular proliferation and perinecrotic palisading tumor cells had no influence over survival [3, 8].

Conclusion

DIA and DIG are tumors of the same family. They occur in children under 2-year-old. Their diagnosis should be rendered only after correlation between neuropathologic, clinical and neuroimaging features. They have favorable prognosis if completely resected.

Competing interests

The authors declare no competing interest.

Authors' contributions

Salma Kamoun wrote the manuscript; Heifa Azouz took the photos and corrected the final version; Marwa Zemmal collected the data; Slim Haouet established the diagnosis; Nidhameddine Kchir supervised the manuscript. All the authors have read and agreed to the final manuscript.

Figures

Figure 1: Magnetic resonance imaging scan showing an area with contrast enhancing in the right temporal region

Figure 2: Spindled portion of the tumor, the cells have obviously eosinophilic cytoplasm and glial appearance

Figure 3: GFAP is strongly positive in the glial portion of the tumor, but negative in blood vessel and mesenchymal cells in the desmoplastic areas

Figure 4: Neuronal portion of tumor, cells range from atypical ganglionic cells to small polygonal cell types

Figure 5: Synaptophysin is positive in ganglion cells

References

1. VandenBerg SR, May EE, Rubinstein LJ, Herman MM, Perentes E, Vinores S et al. Desmoplastic supratentorial neuroepithelial tumors of infancy with divergent differentiation potential ("desmoplastic infantile gangliogliomas") Report on 11 cases of a distinctive embryonal tumor with favorable prognosis. *Journal of neurosurgery*. 1987; 66(1): 58-71. **PubMed**
2. Iwami K-i. Desmoplastic infantile ganglioglioma. *Child's Nervous System*. 2007; 23(6): 619-20. **PubMed**
3. Louis DN, Ohgaki H, Wiestler OD, Cavenee WK, Burger PC, Jouvet A, Scheithauer BW, Kleihues P. WHO Classification of tumours of the central nervous system. *Acta Neuropathol*. 2007 Aug; 114(2): 97-109. **PubMed**
4. Craver RD, Nadell J, Nelson JS. Desmoplastic infantile ganglioglioma. *Pediatr Dev Pathol*. 1999 Nov-Dec; 2(6): 582-7. **PubMed**
5. Prayson RA, Cohen ML, Kleinschmidt-De Masters B. Brain Tumors. 2009 **Google Scholar**
6. Sugiyama K, Arita K, Shima T, Nakaoka M, Matsuoka T, Taniguchi E et al. Good clinical course in infants with desmoplastic cerebral neuroepithelial tumor treated by surgery alone. *Journal of neuro-oncology*. 2002; 59(1): 63-9. **PubMed | Google Scholar**
7. De Munnynck K, Van Gool S, Van Calenbergh F, Demaerel P, Uyttebroeck A, Buyse G et al. Desmoplastic infantile ganglioglioma: a potentially malignant tumor. *The American journal of surgical pathology*. 2002; 26(11): 1515-22. **PubMed | Google Scholar**
8. Kuchelmeister K, Steinhauser A, Korf B, Wagner D, Prey N, Schachenmayr W. Anaplastic desmoplastic infantile ganglioglioma. *Clin Neuropathol*. 1998; 17: 269-70.

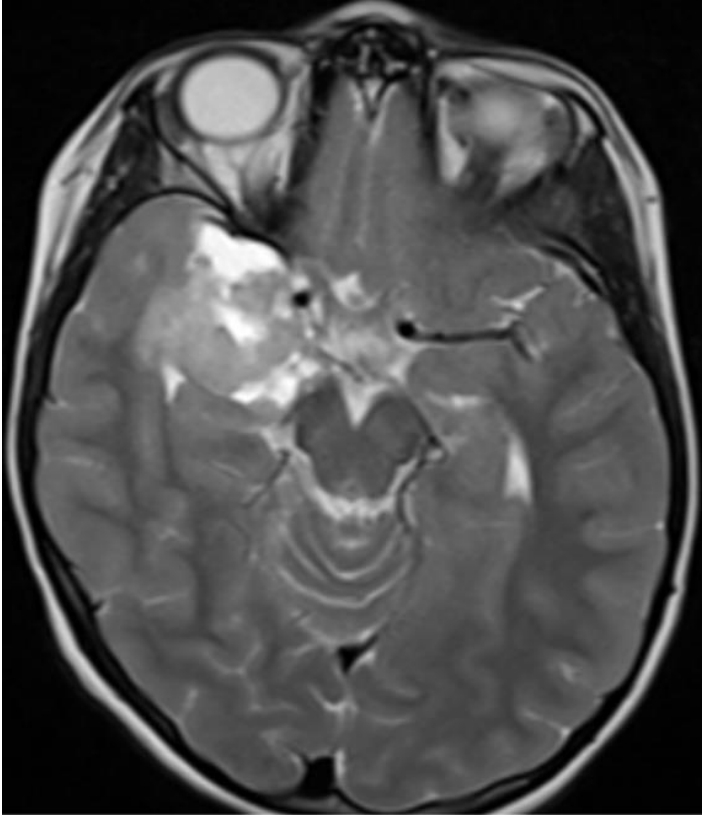

Figure 1: Magnetic resonance imaging scan showing an area with contrast enhancing in the right temporal region

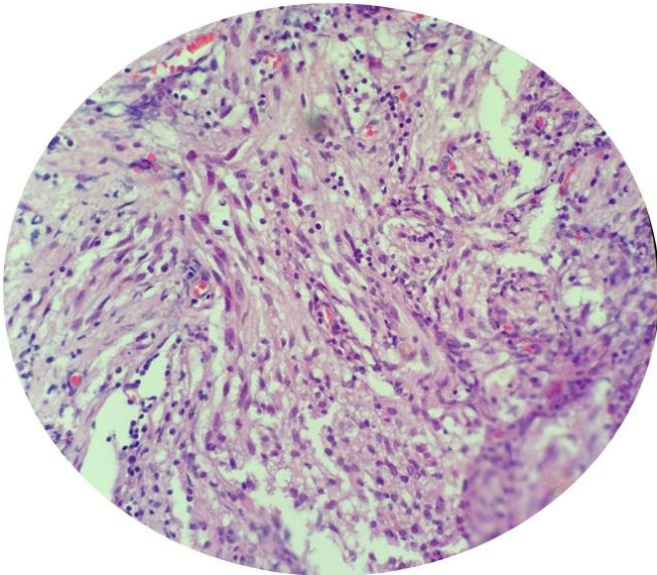


Figure 2: Spindled portion of the tumor, the cells have obviously eosinophilic cytoplasm and glial appearance

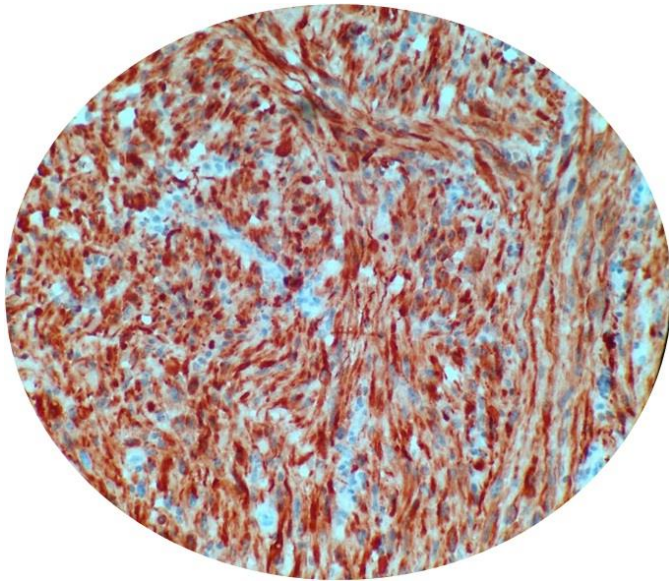


Figure 3: GFAP is strongly positive in the glial portion of the tumor, but negative in blood vessel and mesenchymal cells in the desmoplastic areas

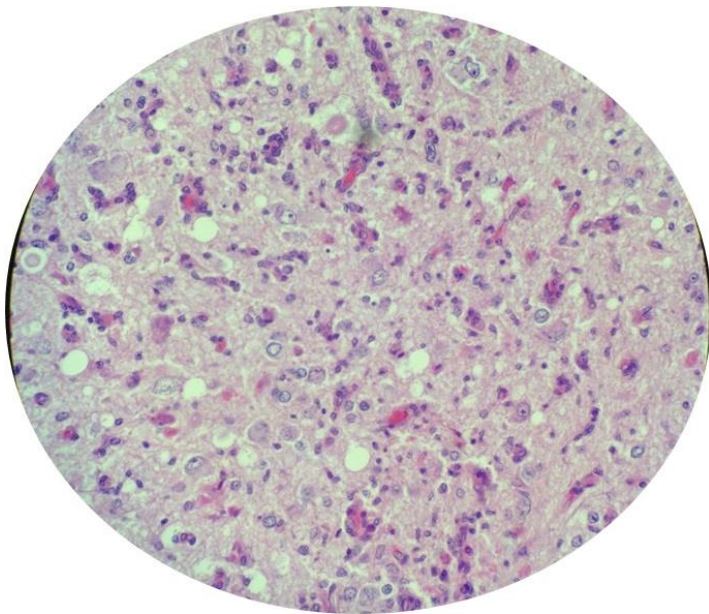


Figure 4: Neuronal portion of tumor, cells range from atypical ganglionic cells to small polygonal cell types

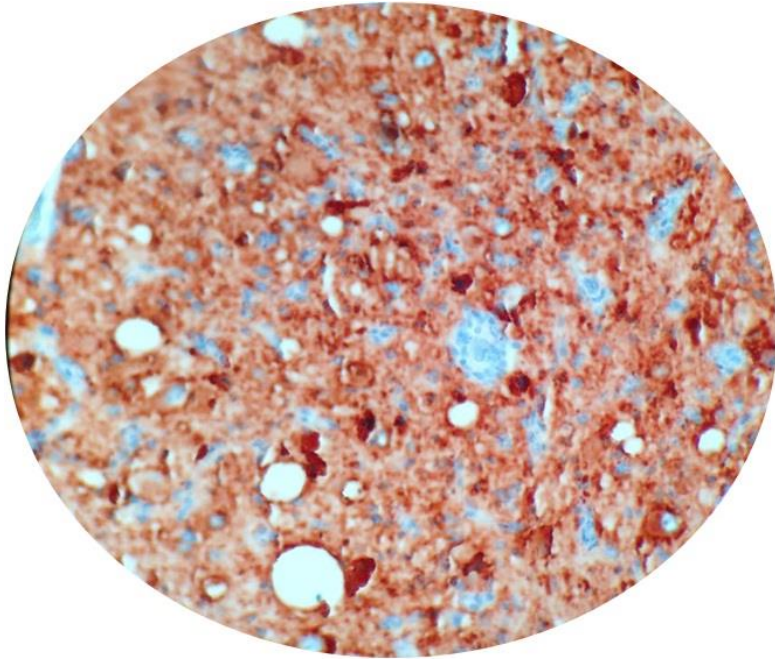


Figure 5: Synaptophysin is positive in ganglion cells