

# Images in medicine

## A case of idiopathic giant megacolon in an obese patient

Pietro Fransvea<sup>1,\*</sup>, Francesco Cortese<sup>2</sup>

<sup>1</sup>Faculty of Medicine and Psychology, "La Sapienza" University of Rome-St Andrea's Hospital, Rome, Italy, <sup>2</sup>Emergency Surgery and Trauma Care Unit, St Filippo Neri Hospital, Rome, Italy

\*Corresponding author: Pietro Fransvea, Faculty of Medicine and Psychology, "La Sapienza" University of Rome-St Andrea's Hospital, Rome, Italy

Key words: Megacolon idiopathic obese, obese patient, Rome

Received: 01/09/2018 - Accepted: 07/11/2018 - Published: 26/11/2018

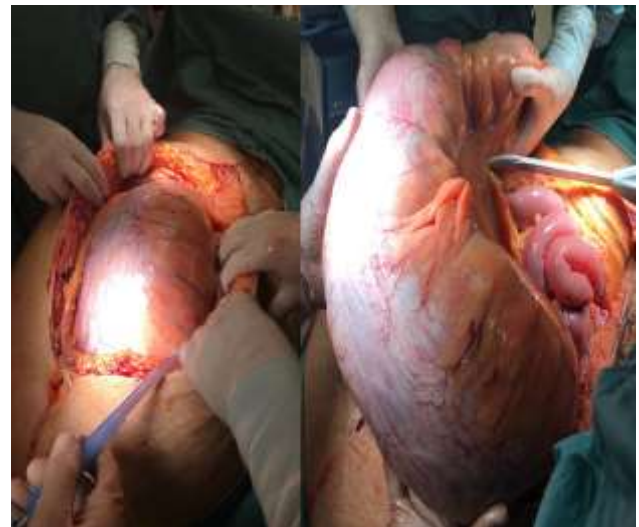
**Pan African Medical Journal. 2018;31:206. doi:10.11604/pamj.2018.31.206.16982**

This article is available online at: <http://www.panafrican-med-journal.com/content/article/31/206/full/>

© Pietro Fransvea et al. The Pan African Medical Journal - ISSN 1937-8688. This is an Open Access article distributed under the terms of the Creative Commons Attribution License (<http://creativecommons.org/licenses/by/2.0>), which permits unrestricted use, distribution, and reproduction in any medium, provided the original work is properly cited.

### Image in medicine

43-year-old man complaining of abdominal nausea starting 15 days earlier and vomiting was admitted to our emergency department. The patient was affected by severe obesity with a BMI of 55.5; there was also a history of diabetes and hypertension. The abdomen was distended, diffusely painful, tympanic to percussion and the Blumberg sign was intensely positive; WBC count was  $24,000 \times 10^3$  with marked neutrophilia, hemoglobin 9.6 g/dl, with haematocrit 30.6%. A distended colon was present at plain RX abdomen while the CT could not be performed due to the high BMI of the patient. At laparotomy a giant idiopathic megacolon was found and a Hartmann procedure was performed. The patient was discharged 15 postop with no complication. The anatomopathological examination documented a normal colon tissue. Diagnosis in obese patients is often difficult because they are paucisintomatic and the physical examination is difficult to achieve.



**Figure 1:** findings at laparotomy, giant megacolon