

Case report

Proximal-type epithelioid sarcoma: a new case report and literature review

Abdelmoughit Echchaoui^{1&}, Yassine Sadrati², Youssef Elbir², Abderrahim Elktaibi³, Malika Benyachou¹, Samir El Mazouz¹, Nour-eddine Gharib¹, Abdellah Abbassi¹

¹Department of Plastic Surgery and Burns, Avicenna University Hospital, Rabat, Morocco, ²Department of Orthopaedic Surgery & Traumatology, Ibn Sina University Hospital, Rabat, Morocco, ³Department of Pathology, Avicenna Military Hospital, Marrakech, Morocco

[&]Corresponding author: Abdelmoughit Echchaoui, Department of Plastic Surgery and Burns, Avicenna University Hospital, Rabat, Morocco

Key words: Epithelioid sarcoma, proximal-type, diagnosis, prognosis

Received: 02/12/2015 - Accepted: 02/07/2016 - Published: 14/07/2016

Abstract

Proximal-type epithelioid sarcoma is a rare soft tissue neoplasm which arises from the more proximal part of body and occurs more often in young people; the definite diagnosis depends mainly on the pathological examination; early detection and complete excision remain the foundation of treatment. Due to its aggressive behavior, high capacity of recurrence and the great ability to metastasize, a careful clinical long-term monitoring is required. We report a new case of a 20 years old girl, presented with proximal-type epithelioid sarcoma in her right scapular region, confirmed by pathological examination and removed surgically without recurrence or metastasis at eighteen months of follow-up.

Pan African Medical Journal. 2016; 24:238 doi:10.11604/pamj.2016.24.238.8535

This article is available online at: <http://www.panafrican-med-journal.com/content/article/24/238/full/>

© Abdelmoughit Echchaoui et al. The Pan African Medical Journal - ISSN 1937-8688. This is an Open Access article distributed under the terms of the Creative Commons Attribution License (<http://creativecommons.org/licenses/by/2.0>), which permits unrestricted use, distribution, and reproduction in any medium, provided the original work is properly cited.

Introduction

Proximal-type epithelioid sarcoma (PES) is a rare high grade soft-tissue sarcoma (less than 1 of all soft tissue sarcomas), typically presenting as a subcutaneous or deep dermal mass, with slow growing and high potential for distant metastasis in adolescents and young adults [1]. These tumors arise in proximal locations (trunk, axilla, genital area...), **have a much worse prognosis if delayed diagnosis and treatment.** Owing to its rarity, aggressive behavior, high capacity of recurrence and the difficulty of its clinical and histopathological diagnosis, we report a new case of a 20 years old girl, presented with proximal-type epithelioid sarcoma in her right scapular region removed and treated successfully.

Patient and observation

A 20 years old girl presented with a red and firm nodule since 2 years in her right scapular region; a first simple excision was performed and was in favor of a benign lesion (fibrous histiocytoma). The lesion recurred clinically six months later as two firm painless nodules and a solid plaque measuring 3.5cm in diameter (Figure 1). There was no lymphadenopathy. The rereading of the histopathological slides made the diagnosis of superficial subcutaneous epithelioid sarcoma and a chest and abdominal computed tomography ruled out metastasis. Wide excision with surgical margins of 4 cm was performed taking the deep fascial plane (Figure 2). The histological examination confirmed the diagnosis with complete resection limits (Figure 3). In immunohistochemical staining, the tumor cells were immunoreactive for vimentin and epithelial markers (cytokeratin, CD34). The loss of substance left in granulation for a few days, was grafted by thin skin (Figure 4). There was no recurrence or metastasis at eighteen months of follow-up.

Discussion

Epithelioid sarcoma was first described by Enzinger in 1970 [2]; usually arises in the distal extremities in adolescents and young adults with male prevalence; the proximal-type variant, first described in 1997 as an aggressive form of sarcoma with a great ability to metastasize and high capacity of recurrence, usually arises

more proximally [3]. Proximal-type epithelioid sarcomas (PES), occur 94% in the chest wall, inguinal region, thigh and perineum, Its size at presentation varies from 0.5 to 19 cm [4], and growth duration ranges from 6 months to 5 years [5]. This uncommon neoplasm is a pitfall in clinical diagnosis and it is likely to be confused with benign lesions resulting in delayed diagnosis and treatment [6]. PES can be diagnosed only through histological examination [7] showing a pleomorphic epithelioid and oval spindled malignant cells with numerous mitoses exhibiting slight nuclear atypia, vesicular nuclei and small nucleoli, transition between the two cell types is gradual and intercellular collagen deposition usually marked [4, 8]; it can be distinguished from poorly differentiated carcinoma, rhabdomyosarcoma, synovial sarcoma, malignant mesothelioma, and melanoma using immunohistochemistry [9]. Immunohistochemically, PES is characteristically immunoreactive for vimentin and epithelial markers: low and high molecular weight cytokeratins, keratin 8, keratin 19 and/or EMA. Half of the cases are also positive for CD34 [10]. Several publications about misdiagnosis and prognosis of PES have been raised currently. Fisher et al [11] emphasize the importance of using immunohistochemicals markers to the diagnostic of specific soft tissue tumors specially co-expression of CD34 and cytokeratins in PES cells. Mannan et al [12] report a case of PES in a 47-year-old man, to emphasize the importance of diagnosing of this challenging tumor and the role of immunohistochemistry in establishing the diagnosis. Wide local excision with adequate margins (at least 2 cm) is recommended [13]; adjuvant radiotherapy is advocated in high-grade tumors or inadequate surgical margins [14], and also due to high incidence of local recurrence and distant metastasis [10]. However it is controversial and it did not show statistically significant reduction in mortality [15]. The role of chemotherapy in the adjuvant setting appears marginally effective at best in the treatment of metastatic disease [16]. The prognosis for PES remains worse; despite negative surgical margins, tendency to recur is highly possible and distant metastasis eventually occurs in up to 60% of cases [14] Ulbright et al. [17] reported in their review of the literature that all patients with local recurrence ultimately died from distant metastasis. Our patient had initially a 2- years history of a progressively growing nodule over the right scapular region, which could be considered as a proximal type variant. As the lesion was recurrent a wider excision with surgical margins of 4 cm was performed. The histological examination and immunohistochemistry confirmed the diagnosis of PES. She underwent no postoperative adjuvant therapy and she is well without recurrence at eighteen months of follow-up.

Conclusion

PES is a rare disease with aggressive behavior and poor prognosis. Early detection, radical surgical excision and histopathological examination are crucial to provide a chance of a cure. The wide variability of clinical expressions and totally unpredictable evolutionary nature require regular long-term monitoring in detecting local recurrence and distant metastasis.

Competing interests

Authors declare no competing interest.

Authors' contributions

The authors have read the final version of this manuscript.

Figures

Figure 1: The two farms painless nodules and a solid plaque on the right scapular region

Figure 2: A loss of substance in granulation after wide excision

Figure 3: Microscopic appearance of the surgical specimen showing weakly eosinophilic epithelioid and elongated cells exhibiting slight nuclear atypia (Hematoxylin and Eosin × 250)

Figure 4: Coverage of the loss of substance by graft of thin skin

References

1. Armah HB, Parwani AV. Epithelioid sarcoma. Arch Pathol Lab Med. 2009; 133(5): 814-9. **PubMed | Google Scholar**
2. Enzinger FM. Epithelioid sarcoma: A sarcoma simulating a granuloma or a carcinoma. Cancer. 1970(5); 26:1029-1041. **PubMed | Google Scholar**
3. Guillou L, Wadden C, Coindre JM, Krausz T, Fletcher CM. "Proximal-type" epithelioid sarcoma, a distinctive aggressive neoplasm showing rhabdoid features. Am J Surg Pathol. 1997; 21(2):130-46. **PubMed | Google Scholar**
4. Tateishi U, Hasegawa T, Kusumoto M, Yokoyama R, Noriyuki M. Radiologic manifestations of proximal-type epithelioid sarcoma of the soft tissue. AJR Am J Roentgenol. 2002; 179(4):973-7. **PubMed | Google Scholar**
5. Dion E, Forest M, Brasseur J, Amoura Z, Grenier P. Epithelioid sarcoma mimicking abscess: review of the MRI appearances. Skeletal Radiol. 2001; 30:173 -7. **PubMed | Google Scholar**
6. Adrian HO, Louis SL, Howard AO, Kenneth WA, John RG. Epithelioid sarcoma of the penis: Report of an unusual case and review of the literature. Ann Diagn Pathol. 2000; 14(2):88-94. **PubMed | Google Scholar**
7. Kim HJ, Kim MH, Kwon J, Kim JY, Park K, Ro JY. Proximal-type epithelioid sarcoma of the vulva with INI1 diagnostic utility. Ann Diagn Pathol. 2012 Oct; 16(5):411-5. **PubMed | Google Scholar**
8. Miettinen M, Fanburg-Smith JC, Virolainen M, Shmookler BM, Fetsch JF. Epithelioid sarcoma: an immunohistochemical analysis of 112 classical and variant cases and a discussion of the differential diagnosis. Hum Pathol. 1999; 30(8) 934-942. **PubMed | Google Scholar**
9. Brand A, Covert A. Malignant rhabdoid tumor of the vulva: case report and review of the literature with emphasis of the clinical management and outcome. Gynecol Oncol. 2001; 80(1):99-103. **PubMed | Google Scholar**
10. Hasegawa T, Matsuno Y, Shimoda T, Umeda T, Yokoyama R, Hirohashi S. Proximal-type epithelioid sarcoma: A clinicopathologic study of 20 cases. Mod Pathol. 2001; 14(7): 655-63. **PubMed | Google Scholar**
11. Fisher C. Immunohistochemistry in diagnosis of soft tissue tumours. Histopathology. 2011; 58(7):1001-12. **PubMed | Google Scholar**

12. Mannan AA, Rifaat AA, Kahvic M, et al. Proximal-type epithelioid sarcoma in the groin presenting as a diagnostic dilemma. *Pathol Oncol Res.* 2010; 16(2):181-8. **PubMed | Google Scholar**
13. Bos GD, Pritchard DJ, Reiman HM, Dobyms JH, Ilstrup DM, Landon GC. Epithelioid sarcoma: an analysis of 51 cases. *J Bone Joint Surg.* 1988; 70A: 862-70. **PubMed | Google Scholar**
14. Casanova M, Ferrari A, Collini P, Bisogno G, Alaggio R, Cecchetto G, et al. Epithelioid sarcoma in children and adolescents: a report from the Italian soft tissue sarcoma committee. *Cancer.* 2006; 106(3):708-717. **PubMed | Google Scholar**
15. Evans HL, Baer SC. Epithelioid sarcoma: A clinicopathologic and prognostic study of 26 cases. *Semin Diagn Pathol.* 1993; 10:286-291. **PubMed | Google Scholar**
16. Argenta PA, Thomas S, Chura JC. Proximal-type epithelioid sarcoma vs malignant rhabdoid tumor of the vulva: A case report, review of the literature, and an argument for consolidation. *Gynecol Oncol.* 2007; 107(1):130-135. **PubMed | Google Scholar**
17. Ulbright TM, Brokaw SA, Stehman FB, Roth LM. Epithelioid sarcoma of the vulva. Evidence suggesting a more aggressive behavior than extragenital epithelioid sarcoma. *Cancer.* 1983; 52:1462-9. **PubMed | Google Scholar**

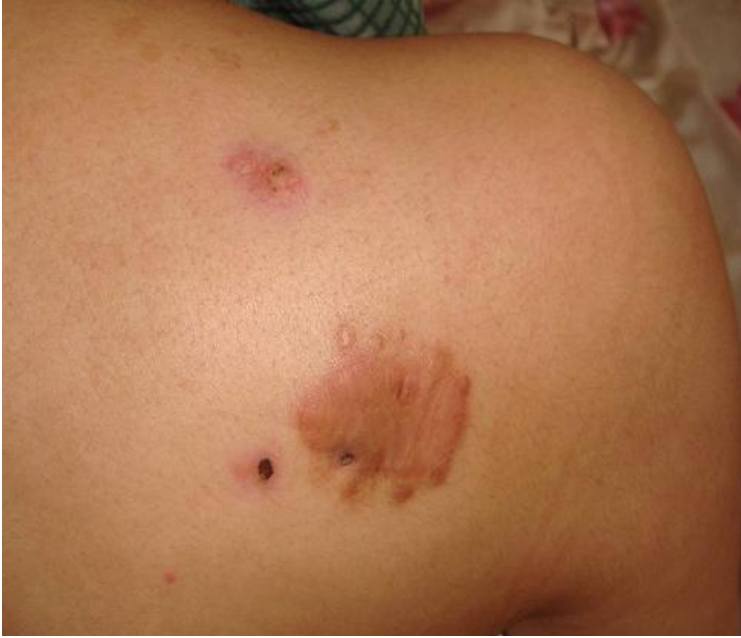

Figure 1: The two farms painless nodules and a solid plaque on the right scapular region

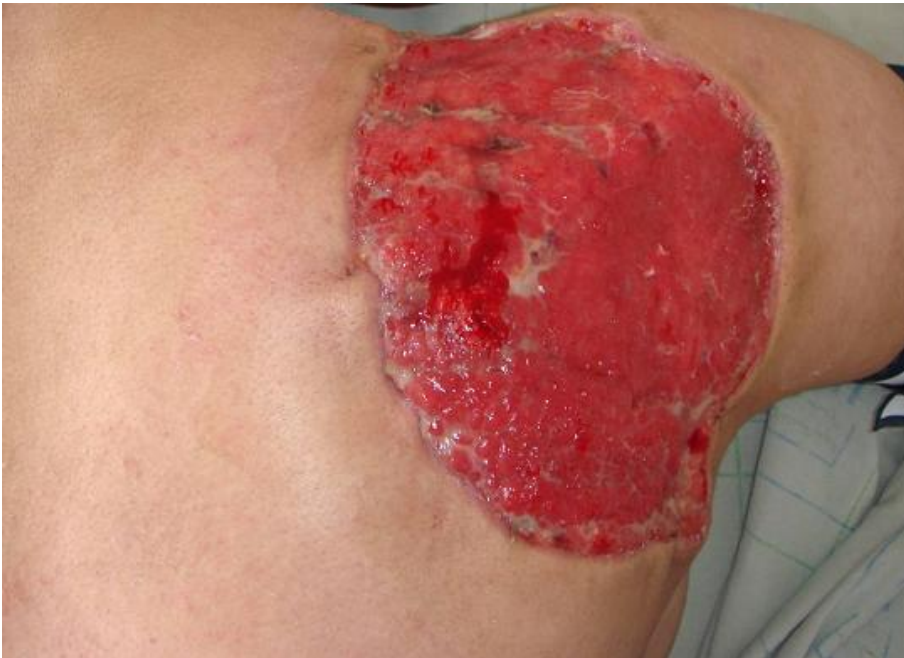

Figure 2: A loss of substance in granulation after wide excision

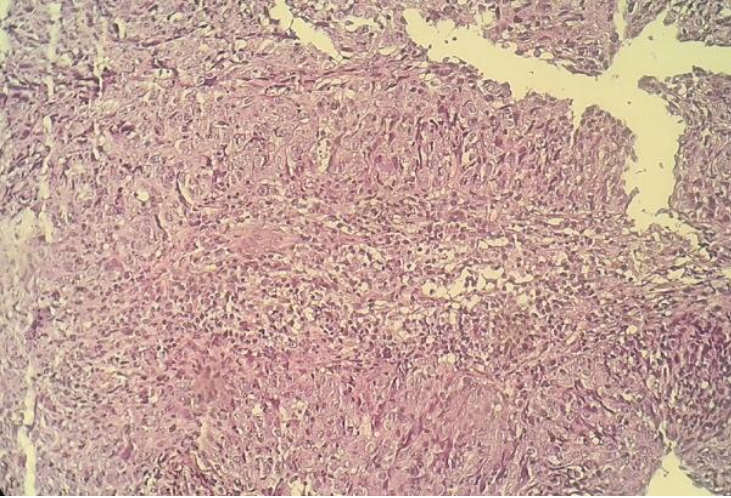


Figure 3: Microscopic appearance of the surgical specimen showing weakly eosinophilic epithelioid and elongated cells exhibiting slight nuclear atypia (Hematoxylin and Eosin × 250)

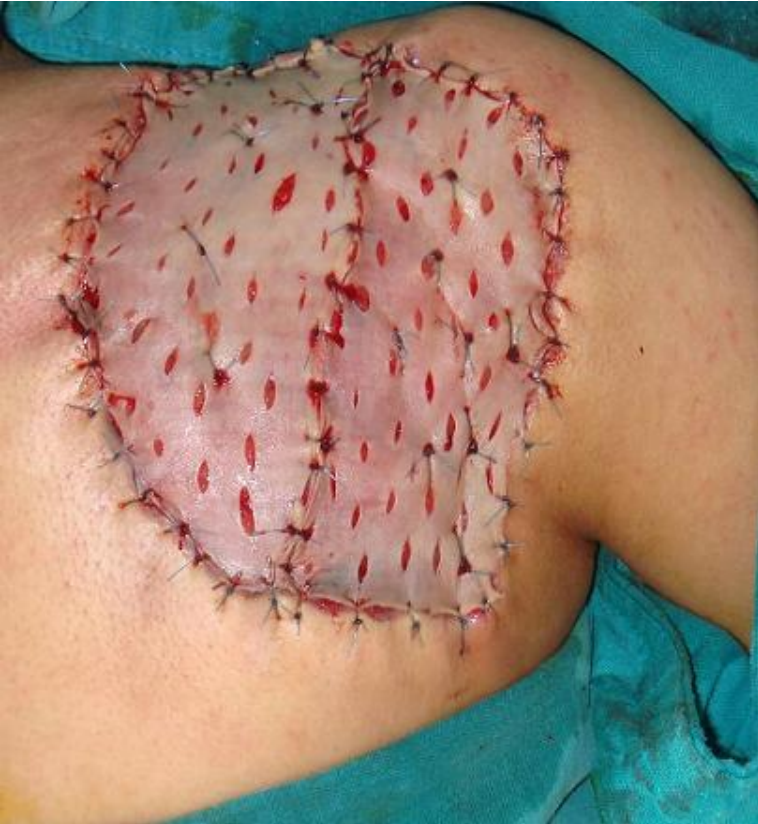

Figure 4: Coverage of the loss of substance by graft of thin skin