

Images in medicine

Bruns Syndrome: a deadly sign

Mohammed Yassaad Oudrhiri^{1,*}, Nabil Raouzi¹

¹Neurosurgery Department, Al Farabi Regional Hospital Center, Oujda, Morocco

^{*}Corresponding author: Mohammed Yassaad Oudrhiri, Neurosurgery Department, Al Farabi Regional Hospital Center, Oujda, Morocco

Key words: Bruns syndrome, colloid cyst, hydrocephalous

Received: 06/10/2015 - Accepted: 26/10/2015 - Published: 11/11/2015

Pan African Medical Journal. 2015; 22:229 doi:10.11604/pamj.2015.22.229.8140

This article is available online at: <http://www.panafrican-med-journal.com/content/article/22/229/full/>

© Mohammed Yassaad Oudrhiri et al. The Pan African Medical Journal - ISSN 1937-8688. This is an Open Access article distributed under the terms of the Creative Commons Attribution License (<http://creativecommons.org/licenses/by/2.0>), which permits unrestricted use, distribution, and reproduction in any medium, provided the original work is properly cited.

Image in medicine

Bruns syndrome was first described in 1902, as a sudden onset of severe headaches and vomiting associated to a vestibular syndrome provoked by abrupt change in head position. It is related to an episodic obstructive hydrocephalous caused by an intraventricular mass that acts like a ball-valve mechanism. A 52 years old man was admitted to the intensive care unit for a sudden onset coma. His Glasgow Coma Scale was 4/15 with fixed dilated pupils. He has been experiencing paroxysmic episodes of headaches, vomiting and vertigo for 6 months that went undiagnosed. Diagnoses include acute hydrocephalous, syncopes, and stroke. The CT scan showed a globally iso-dense rounded mass of the anterior roof of the third ventricle, with hyperdense areas suggestive of hemorrhage, obstructing both foramen of Monro and causing acute hydrocephalous. The patient underwent an urgent placement of an external ventricular drainage; the intracranial pressure was above 25mmHg, and the CSF gin-clear. Unfortunately, the patient did not survive this episode and died 24hours later. Colloid cysts are rare, benign, and curable lesions located at the anterior part of the roof of the third ventricle, and contain colloid material. Their clinical

presentation varies from incidentally found cysts to sudden death. Rapid deterioration may also be caused by an intrinsic hemorrhage. Such condition has only been reported in the literature in 16 publications. Through this observation we would like to bring attention concerning this syndrome that may be preceding fulminant and lethal deterioration from a benign and surgically curable lesion.

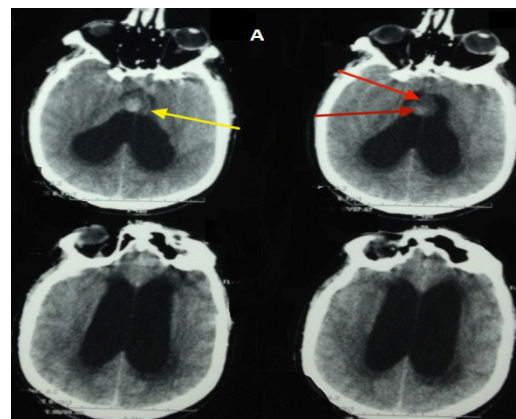


Figure 1: hemmorrhagic colloid cyst with acute hydrocephalous