

Images in medicine

Acalculous cholecystitis in patient with hepatic hypogenesis and chilaiditi sign

Adriá Rosat^{1, &}, Daniel Eiroa²

¹Department of General Surgery, Hospital Universitario Nuestra Señora de Candelaria, Tenerife, Spain, ²Radiodiagnostic Service, Hospital Universitario Nuestra Señora de Candelaria, Tenerife, Spain

[&]Corresponding author: Adriá Rosat, Department of General Surgery, Hospital Universitario Nuestra Señora de Candelaria, Tenerife, Spain

Key words: Acaculous Cholecystitis, hepatic hypogenesis, chilaiditi sign

Received: 04/08/2015 - Accepted: 17/08/2015 - Published: 24/08/2015

Pan African Medical Journal. 2015; 21:297 doi:10.11604/pamj.2015.21.297.7675

This article is available online at: <http://www.panafrican-med-journal.com/content/article/21/297/full/>

© Adriá Rosat et al. The Pan African Medical Journal - ISSN 1937-8688. This is an Open Access article distributed under the terms of the Creative Commons Attribution License (<http://creativecommons.org/licenses/by/2.0/>), which permits unrestricted use, distribution, and reproduction in any medium, provided the original work is properly cited.

Image in medicine

A 66-year-old male patient was admitted in our outside hospital's emergency room after 4 days of epigastric pain, nausea and vomiting. No fever, dysthermia or respiratory symptoms were related. The pain irradiated to right hypochondria and even to right chest. Laboratory tests showed slight elevation of liver enzymes and leukocytosis. Abdominal CT revealed hepatodiaphragmatic colonic interposition, segmental agenesis of the right hepatic lobe (A) and a gallbladder with thickened walls and inflammatory changes without any stone (B). The patient did well with antibiotic treatment and was discharged home. Hepatodiaphragmatic interposition of the intestine, known as Chilaiditi sign or syndrome, was first described by Demetrius Chilaiditi in 1910, with an incidence of 0.025-0.28%. Predisposing factors include absence of the normal suspensory ligaments of the transverse colon, redundant colon, right hemidiaphragm elevation, atrophy or hypogenesis of the right hepatic lobe, etc. Agenesis or hypogenesis of the right liver lobe is an extremely rare congenital anomaly and one of the rare causes of Chilaiditi sign or syndrome. It is considered to be caused by a failure of the right portal vein to develop, or an error of mutual induction between the primitive diaphragm and the endodermal diverticulum

representing the primitive liver. The differential diagnoses of Chilaiditi syndrome include pneumoperitoneum, diaphragmatic hernia, subdiaphragmatic abscess, bowel obstruction and volvulus. No chirurgic intervention is required for a patient with Chilaiditi sign, they respond to medical management, and surgery is reserved for those who do not respond to usual conservative line of management.

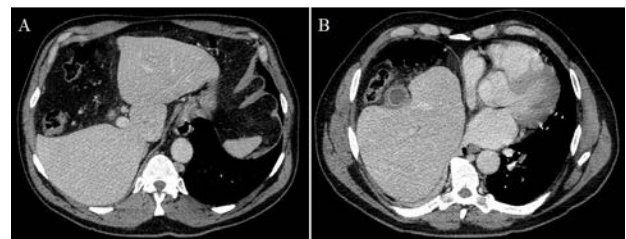


Figure 1: (A) colonic interposition between the liver and the diaphragm, in the place left by a segmental agenesis of the right hepatic lobe; (B) thickened walls gallbladder and inflammatory changes in surrounding fat without any stones nor bile duct dilatation