

Case report

Iatrogenic pharyngoesophageal perforation and diverticulum formation conservatively managed in an adult patient

Mohammed Amine Benatta^{1,&}

¹Digestive Endoscopy Unit, Military Central Hospital , Algiers, Algeria

[&]Corresponding author: Mohammed Amine Benatta, Digestive Endoscopy Unit, Military Central Hospital, Algiers, Algeria

Key words: Pharyngoesophageal perforation, diverticulum, conservative management

Received: 22/11/2015 - Accepted: 05/04/2016 - Published: 22/04/2016

Abstract

Iatrogenic pharyngoesophageal perforations represent serious problems that are difficult to diagnose and manage. We report a case of pharyngoesophageal diverticulum formation due to perforation after external transcervical polypectomy. The patient was referred to our endoscopy unit by otorhinolaryngologist 9 days after a surgical cervical polyp resection. He was in stable general condition, without sepsis. A nonoperative management was attempted with percutaneous endoscopic gastrostomy placement and broad-spectrum antibiotics. Nine weeks later esophagography demonstrated a complete regression of both the perforation and the diverticulum.

Pan African Medical Journal. 2016; 23:217 doi:10.11604/pamj.2016.23.217.8473

This article is available online at: <http://www.panafrican-med-journal.com/content/article/23/217/full/>

© Mohammed Amine Benatta et al. The Pan African Medical Journal - ISSN 1937-8688. This is an Open Access article distributed under the terms of the Creative Commons Attribution License (<http://creativecommons.org/licenses/by/2.0>), which permits unrestricted use, distribution, and reproduction in any medium, provided the original work is properly cited.

Introduction

Iatrogenic pharyngoesophageal perforations represent serious problems that are difficult to diagnose and manage. Pharyngoesophageal diverticulum is an acquired pouch which is located proximally to the upper esophageal sphincter, usually on the posterior hypopharyngeal wall. It has been reported as a rare complication of anterior spine surgery [1]. The mortality rate of non-operative treatment of esophagus perforations is 20-38% [2]. This is a conservatively managed case of iatrogenic pharyngoesophageal perforation due to external transcervical polypectomy complicated with diverticulum formation.

Patient and observation

A 57-year-old woman was referred to our digestive endoscopy unit by otorhinolaryngologist for cervical diverticulum. During the last 3 years she experienced an intermittent dysphagia to solid materials, odynophagia and anxiety. At laryngoscopy a polyp was seen at the piriform sinus and confirmed by cervical computed tomography, pharyngoesophageal magnetic resonance imaging. Nine days earlier she underwent an external transcervical polyp resection. Surgery included cervicoesophagotomy, polyp resection and esophageal repair. Subsequently, she experienced a localized cutaneous infection at the cervicotomy site without fever or leucocytosis. At barium contrast esophagography a diverticulum extending from the cervical esophagus down to the left side was diagnosed (Figure 1, A). Flexible esophagoscopy revealed a 20-mm tear at the piriform sinus (Figure 1, B) leading to access into a 7 x 3 cm pharyngoesophageal diverticulum (Figure 1, C). However the patient was in stable general condition without progressive sepsis. A decision was made to manage the case with conservative approach. Oral intake was stopped, a percutaneous endoscopic gastrostomy (PEG) was placed with aid of a biliary guidewire (0.035-inch-diameter) advanced in the esophagus, to avoid accidental passage in the diverticulum. Administration of broad-spectrum antibiotics was continued. The patient remained stable during hospitalization. Nine weeks later barium contrast esophagography demonstrated a complete regression of the diverticulum (Figure 2) and endoscopy revealed complete resolution of the pharyngeal tear. The PEG was extracted and the patient was initiated on oral feeds. At the 1-year follow-up, the patient had no signs of dysphagia or any other complaints.

Discussion

Pharyngoesophageal perforations represent serious problems that have considerable morbidity and potential mortality especially in delayed diagnosed cases. They may be due to endotracheal intubations and to oesophagoscopies when used for extraction of foreign bodies and stenosis dilation. They occur most frequently in the piriform sinus and in Killian's triangle. In our case the diagnostic of the perforation and its extent were made by contrast esophagography. The site of the injury was defined and the diverticulum seen accurately by flexible endoscopy. Currently, there are no published guidelines to manage these patients. Surgical, endoscopic or conservative approaches for the management of the esophageal perforation have been reported. A case of transoral laparoscopic suturing for a pharyngeal perforation has been recently reported [3]. Endoscopic clipping was not attempted in our patient because of technical difficulties given the tear's location at the piriform sinus a narrowing site. A successful treatment with fully covered self-expandable metallic stents for iatrogenic pharyngoesophageal perforations was recently reported in two patients [4]. It is known that conservative approach can be acceptable in selected patients with well-contained perforations and minimal cervical and mediastinal contamination [5,6] also small perforations tend to seal without sequelae. In this patient, without apparent progressive sepsis, iatrogenic pharyngoesophageal perforation with diverticulum formation was conservatively and effectively managed.

Conclusion

Our conservative attitude to treat this patient, with iatrogenic pharyngoesophageal perforation and diverticulum formation but without apparent progressive sepsis was effective. Therefore this attitude should be considered before any other aggressive treatment, in the absence of management recommendations of such cases.

Competing interests

The authors declare no competing interest.

Figures

Figure 1: A) cervical diverticulum that extended from the cervical esophagus down to the left side at barium contrast esophagography , B): esophagosopic view of the 20-mm tear at the pyriform sinus ;C): esophagosopic view of the 7 x 3 cm pharyngoesophageal diverticulum with barium contrast at the bottom

Figure 2: Regression of the pharyngoesophageal diverticulum at barium contrast esophagography

References

1. Tian H, Yuan W, Johnson J S , Chen H, Chen D. Pharyngoesophageal diverticulum: a delayed complication of anterior cervical spine surgery. *European Spine Journal*.2011;20 (2):211-216. **PubMed | Google Scholar**
2. Altorjay A, Kiss J, Vörös A, Bohák A. Nonoperative management of esophageal perforations. Is it justified?. *Ann Surg*.1997; 225 (4):415-421. **PubMed | Google Scholar**
3. Wasano K, Hashiguchi S, Suzuki N et al. Transoral closure of pharyngeal perforation caused by gastrointestinal endoscopy. *Auris Nasus Larynx*.2014; 41 (1):113-117. **PubMed | Google Scholar**
4. Kumbhari V, Azola A A , Tieu A H et al. Iatrogenic pharyngoesophageal perforations treated with fully covered self-expandable metallic stents (with video). *Surgical endoscopy*.2015: 29(4): 987-991.**PubMed | Google Scholar**
5. Wu JT, Mattox KL, Wall MJ Jr. Esophageal perforations: new perspectives and treatment paradigms. *J Trauma*.2007; 63 (5):1173-1184. **PubMed | Google Scholar**
6. Brinster CJ, Singhal S, Lee L, Marshall MB, Kaiser LR, Kucharczuk JC. Evolving options in the management of esophageal perforation. *Ann Thorac Surg*. 2004; 77(4):1475-1483. **PubMed | Google Scholar**

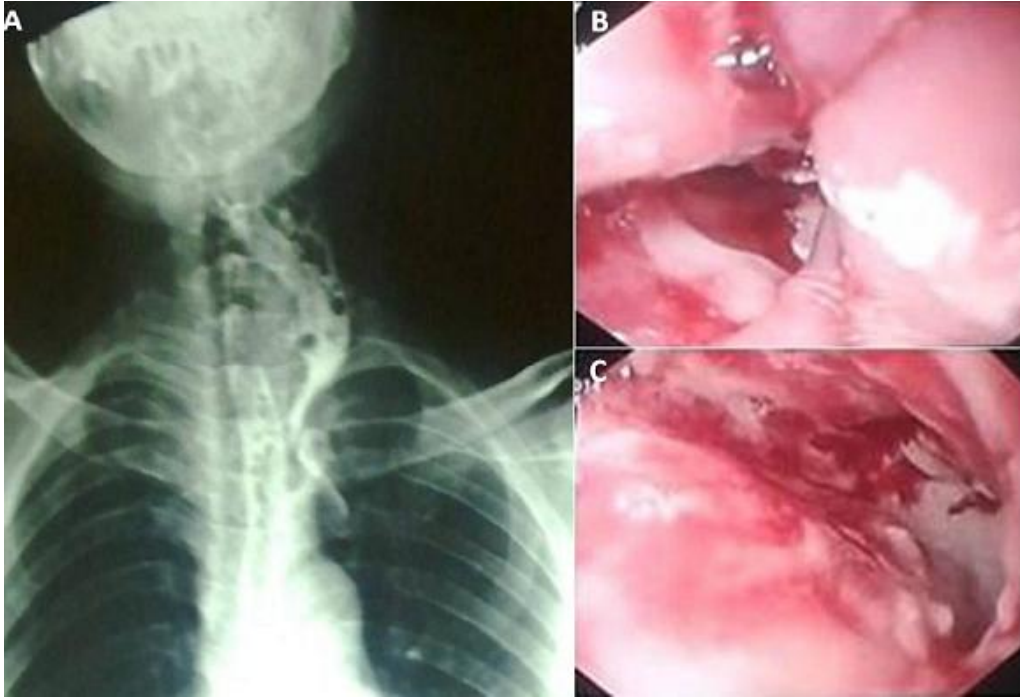


Figure 1: A) cervical diverticulum that extended from the cervical esophagus down to the left side at barium contrast esophagography , B): esophagosopic view of the 20-mm tear at the pyriform sinus ;C): esophagosopic view of the 7 x 3 cm pharyngoesophageal diverticulum with barium contrast at the bottom

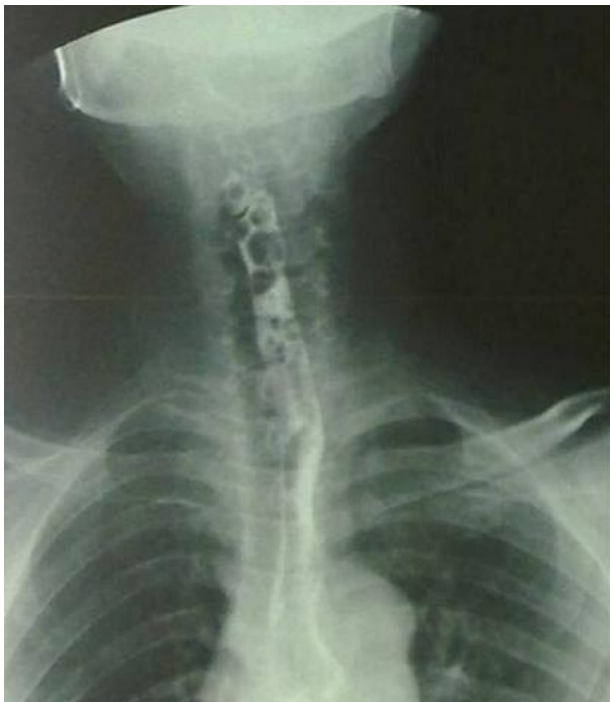

Figure 2: Regression of the pharyngoesophageal diverticulum at barium contrast esophagography