

Brief

Unilateral multifocal choroidal ischemia revealing a giant cell arteritis: a case report

Zouheir Hafidi^{1,*}, Hanan Handor¹, Hamid Elmoussaif¹, Mina Laghmari¹, Abdelouahed Karmane¹, Samira Tachfouti¹, Rajae Daoudi¹

¹Université Mohammed V Souissi, Service d'Ophtalmologie A de l'Hôpital des Spécialités, Centre Hospitalier Universitaire, Rabat, Maroc

^{*}Corresponding author: Zouheir Hafidi, Université Mohammed V Souissi, Service d'Ophtalmologie A de l'Hôpital des Spécialités, Centre Hospitalier Universitaire, Rabat, Maroc

Key words: Giant cell arteritis, choroidal ischemia, multi focal, unilateral

Received: 22/07/2013 - Accepted: 29/10/2014 - Published: 30/10/2014

Pan African Medical Journal. 2014; 19:228 doi:10.11604/pamj.2014.19.228.3132

This article is available online at: <http://www.panafrican-med-journal.com/content/article/19/228/full/>

© Zouheir Hafidi et al. The Pan African Medical Journal - ISSN 1937-8688. This is an Open Access article distributed under the terms of the Creative Commons Attribution License (<http://creativecommons.org/licenses/by/2.0>), which permits unrestricted use, distribution, and reproduction in any medium, provided the original work is properly cited.

Brief

The authors report an unusual case of multifocal choroidal ischemia revealing a giant cell arteritis. A 70 year-old woman presented for a sudden blurry vision in her right eye. The medical anamnesis revealed a previous history of recurrent bilateral fugax amaurosis; she experienced jaw claudication and headache in the few past days, with febricula and generalized weakness.

Physical examination, revealed a visual acuity of 6/30 in the right eye and 6/6 in the left eye. Fundoscopy of both eyes was unremarkable, there was, particularly, no optic disk swelling (**Figure 1, A**). General examination showed a decreased temporal artery pulse on the right side. Fluorescein angiogram of the right eye showed blockage corresponding to a choroidal hypoperfusion (white arrows), and no abnormalities of the left eye (**Figure 1, B**).

The patient had a markedly increased erythrocyte sedimentation rate (ESR) (102 mm/hour), with a high level of C reactive protein (CRP) (45mg/dL). A biopsy of the right temporal artery was performed, and histological examination of the specimen showed a polymorphic inflammatory infiltrate associated with some multinucleated clusters of giant cells.

The patient was diagnosed with Giant cell arteritis, according to the aforementioned histological and clinical data, and received a prompt intravenous three days bolus of methylprednisolone at a dose of 1g per day, relayed by oral corticosteroids at 1 mg/kg/day, during 6 weeks (until normalization of the CRP and ESR) with gradual tapering. Over the next 6 months her visual acuity improved to 6/15 in the right eye.

Temporal arteritis is a subacute systemic panarteritis with predilection over cranial arteries

Anterior ischemic optic neuropathy with or without the typical sectoral choroidal ischemia is the most common complication, leading to blindness unless it's not treated, with a high rate of bilateralization. Isolated choroidal ischemia without retinal vascular occlusion or acute anterior ischemic neuropathy is a rare manifestation of this disorder [1, 2], and is reported to be rather sectoral.

Unlike sectoral choroidal ischemia, which is, characteristically, due to the occlusion of the posterior ciliary arteries, multifocal choroidal ischemia is caused by the obstruction of the choriocapillaris [3]. Explaining the angiographic findings in this entity; mainly characterized by multifocal unsystematized hypo fluorescein areas, predominating around the optic disc, as noted in our case.

Numerous disorders may be associated to multifocal choroidal ischemia including toxemia of pregnancy [4], malignant hypertension [5], Vogt-Koyanagi-Harada disease [6], polyarteritis nodosa [7], and other systemic disorders [8, 9]. However it's not a common finding in giant cell arteritis, which affects large, medium, and small sized arteries, but not capillaries. Our documented case could reflect a possible involvement of choriocapillaris in giant cell arteritis.

Finally, the treatment should also be considered in such cases, because choroidal ischemia may precede optic nerve involvement [10].

Competing interests

The authors declare no competing interest.

Authors' contributions

All authors contributed in this work. All authors read and approved the final manuscript.

Figures

Figure 1: (A) fundoscopic examination: there is no optic disc abnormalities, the rest of the retina appeared normal; (B) Fluorescein angiogram showing a blockage corresponding to a choroidal infarction in the right eye (white arrows)

References

1. Elluard M, Sitbon A, Barreau E. Acute sectoral choroidal ischemia: a case report. *J Fr Ophtalmol.* 2013 Feb;36(2):124-8. **PubMed | Google Scholar**
2. Olali C, Aggarwal S, Ahmed S, Gupta M. Giant cell arteritis presenting as macular choroidal ischaemia. *Eye (Lond).* 2011 Jan;25(1):121-3. **PubMed | Google Scholar**
3. Gaudric A, Sterkers M, Coscas G. Retinal detachment after choroidal ischemia. *Am J Ophthalmol.* 1987 Oct 15;104(4):364-72. **PubMed | Google Scholar**
4. Chaine G, Attali P, Gaudric A, Colin M.C, Quentel G, Coscas G. Ocular fluorophotometric and angiographic findings in toxemia of pregnancy *Arch. Ophthalmol.* 1986 Nov;104(11):1632-5. **PubMed | Google Scholar**
5. Hayreh SS, Servais GE, Virdi PS. Fundus lesions in malignant hypertension. VI. Hypertensive choroidopathy. *Ophthalmology.* 1986 Nov;93(11):1383-400. **PubMed | Google Scholar**
6. Touitou V, Escande C, Bodaghi B, Cassoux N, Wechsler B, Lemaitre C, et al. Diagnostic and therapeutic management of Vogt-Koyanagi-Harada syndrome. *J Fr Ophtalmol.* 2005 Jan;28(1):9-16. **PubMed | Google Scholar**
7. Abouzahir A, Bennouk Y, El Qatni M, El Omri N, Hammi S, Badaoui M, et al. Ocular involvement in polyarteritis nodosa: two cases. *J Fr Ophtalmol.* 2012 Nov;35(9):724.e1-5. **PubMed | Google Scholar**
8. Coscas G, Gaudric A, Dhermy P, Vernant JP, Cordonnier C. Choriocapillaris occlusion in Moschowitz's disease. *J Fr Ophtalmol.* 1981;4(2):101-11. **PubMed | Google Scholar**
9. Rapoport P, Merle H, Smadja D. Ischemic choroidopathy in primary Sjogren's syndrome. *Acta Ophthalmol Scand.* 1998 Oct;76(5):627-8. **PubMed | Google Scholar**

10. Slavin ML, Barondes MJ. Visual loss caused by choroidal ischemia preceding anterior ischemic optic neuropathy in giant cell arteritis. *Am J Ophthalmol.* 1994 Jan 15;117(1):81-6. [PubMed](#) | [Google Scholar](#)

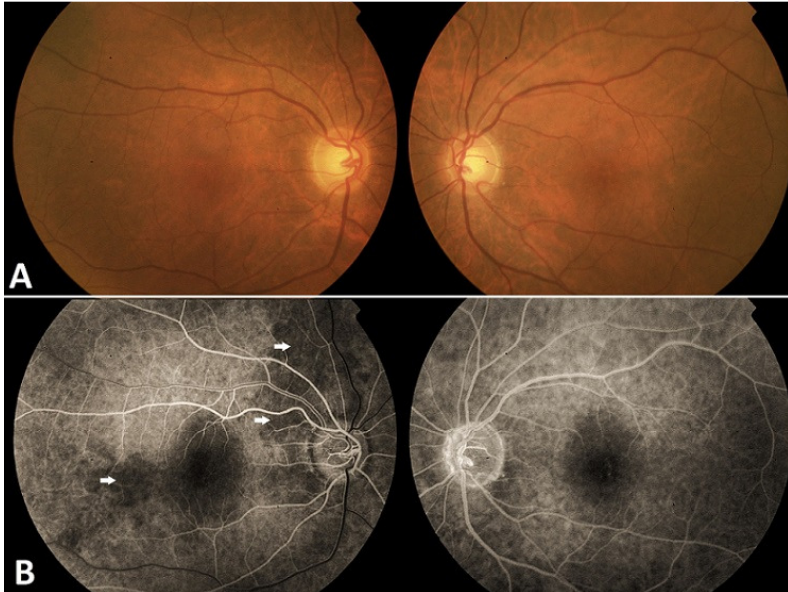


Figure 1: (A) fundoscopic examination: there is no optic disc abnormalities, the rest of the retina appeared normal; (B) Fluorescein angiogram showing a blockage corresponding to a choroidal infarction in the right eye (white arrows)