

## Case report

### **Acute intestinal obstruction revealing synchronous gastrointestinal stromal tumors in a small bowel diverticulum and mucinous adenocarcinoma of the colon: a case report**

**El Ochi Mohamed Reda<sup>1,&</sup>, Jahid Ahmed<sup>1</sup>, El Ktaibi Abderrahim<sup>1</sup>, Znati Kawtar<sup>1</sup>, Zouaidia Fouad<sup>1</sup>, Bernoussi Zakia<sup>1</sup>, Mahassini Najat<sup>1</sup>**

<sup>1</sup>Department of Pathology, Ibn Sina University Hospital, Rabat, Morocco

<sup>&</sup>Corresponding author: El Ochi Mohamed Reda, Department of Pathology, Ibn Sina University Hospital, Rabat, Morocco

Key words: Intestinal obstruction, stromal tumors, colon

Received: 11/05/2013 - Accepted: 26/05/2015 - Published: 02/07/2015

#### **Abstract**

Gastrointestinalstromal tumors are rare neoplasms and represent 0,1% to 3% of all gastrointestinal cancers. They are the most frequent mesenchymal neoplasms of the gastrointestinal tract with a malignant potential and unpredictable behavior. The synchronous association with other primary gastrointestinal carcinoma has been rarely reported in the literature with increasing number in the last ten years. The associated Gastrointestinalstromal tumor is usually discovered incidentally during surgery for carcinoma. The limited number of these cases cannot confirm the existence of a common factor in tumorigenesis of these different tumors and other studies are needed to clarify the possible association. We report the first case in the literature of synchronous primary Gastrointestinalstromal tumors developed in small bowel diverticulum and mucinous adenocarcinoma of the colon. Key words: Synchronous, Gastrointestinalstromal tumors, Adenocarcinoma, Colon.

**Pan African Medical Journal. 2015; 21:172 doi:10.11604/pamj.2015.21.172.2828**

This article is available online at: <http://www.panafrican-med-journal.com/content/article/21/172/full/>

© El Ochi Mohamed Reda et al. The Pan African Medical Journal - ISSN 1937-8688. This is an Open Access article distributed under the terms of the Creative Commons Attribution License (<http://creativecommons.org/licenses/by/2.0>), which permits unrestricted use, distribution, and reproduction in any medium, provided the original work is properly cited.

## Introduction

---

Gastrointestinal stromal tumors (GIST) are rare mesenchymal tumors of the gastrointestinal tract with an incidence of 1,5/100000 habitant/year [1]. They occur in adults especially in the sixth and seventh decades [2]. The concomitant association with other primary gastrointestinal malignancy has been rarely reported. Most of these publications describe gastric stromal tumors synchronous with another gastric malignancy [3]. We report a 60 year old male with synchronous mucinous adenocarcinoma of the colon and gastrointestinal stromal tumor in small bowel diverticulum.

## Patient and observation

---

A 60 year old male without clinical antecedents was admitted to the emergency room complaining of diffuse abdominal pain, vomiting and no evacuation either of fecal matter or of flatus. He presented rectal bleeding and constipation since one month. Physical examination revealed abdominal distension and pain to palpation. Mucocutaneous pallor was detected. Abdominal x-ray evidenced air-fluid levels (**Figure 1**). Laboratory test showed abnormal parameters: anemia with hemoglobin of 8 g/dl, hematocrit of 26% and reticulocyte count of 26 ‰. The patient underwent emergency surgery. Intraoperatively, a tumor of the sigmoid colon had been detected which was infiltrating and stenosing. On exploration, a mass in small bowel diverticulum, 60 cm proximal to the ileocecal valve was encountered. The mass was 5 cm in maximal diameter. A left hemicolectomy and diverticulectomy were performed (**Figure 2**). The tumor of the colon was mucinous adenocarcinoma pT3N1 (**Figure 3**). Histopathological diagnosis for the tumoral diverticulum was low grade GIST (**Figure 4**) and low risk according to Miettinen and Lasoto's scheme. Mitotic count was 3 per 50 high power field. The immunohistochemistry indicated strong staining for ckit/CD117 (**Figure 5**) and CD34 (**Figure 6**) while the expression of smooth muscle actin, desmin and S100 protein were negatives.

## Discussion

---

GISTs are the most common mesenchymal tumors of the gastrointestinal tract [4]. This group of tumors represents about 0,1 to 3% of all gastrointestinal neoplasms. Most of them are located in

the stomach and small intestine [5]. They usually develop in a sporadic fashion. However, familial occurrence has also been reported [4].

The diagnosis is based on morphology and immunohistochemistry. CD117 is positive in 95%, CD34 in 40%-50%, smooth muscle actin in 20%-30%, S100 protein and desmin in 10% of cases [6]. Surgery is typically the first step in the treatment of GISTs. Recurrences, metastatic disease or unresectable tumors can be treated with imatinib [7]. GISTs have been reported to occur synchronously with adenocarcinoma, lymphoma and carcinoid [3].

The simultaneous occurrence of GIST and adenocarcinoma is uncommon [4]. In a series of 200 cases of GISTs, studied by Urbanczyk et al, synchronous tumors were present in seven patients including one adenocarcinoma of the colon [8]. Coexisting GISTs are usually detected incidentally during gastrointestinal surgery for carcinoma [9].

The etiology of this association is still unknown, but some theories exist: the hypothesis that the association is due to a simple coincidence particularly in areas with high rate of digestive cancer is proposed [10]; a possible explanation is represented by the metallothioneins which protect against DNA damage, apoptosis, cell survival, angiogenesis and oxidative stress [11]. Metallothioneins have been reported to be down regulated in some type of cancers including gastric, colorectal, liver and central nervous system [12]. This theory is supported by nucleolar expression of metallothioneins in GIST [13]; the development of these tumors may involve common carcinogenic agent. Sigimura et al [14] revealed that enteral nitrosoguanidine produces adenocarcinoma in rats. In contrast, simultaneous exposure to both nitrosoguanidine and acetylsalicylic acid causes synchronous development of both gastric cancer and leiomyosarcoma [15].

## Conclusion

---

The limited number of these cases cannot confirm the existence of a common factor in tumorigenesis of these different tumors. Further studies are needed to clarify the possible association.

## Competing interests

---

The authors declare no competing interest.

## Authors' contributions

---

AJ and AE contributed to the conception and design of the manuscript. AJ, KZ and FZ analyzed and interpreted the patient data regarding the disease. ZB and NM were major contributors in writing the manuscript. AJ carried out the histology and immunohistochemistry examination. All authors read and approved the final manuscript.

## Figures

---

**Figure 1:** Abdominal X-ray showing the presence of air-fluid levels

**Figure 2:** Macroscopic appearance of GIST in small bowel diverticulum

**Figure 3:** Mucinous adenocarcinoma of the sigmoid (HE stain, ob. x 20)

**Figure 4:** fusiform low grade GIST: (A) invasion of submucosa of small intestine from GIST (HE stain, ob. x 10); (B) the GIST was composed of fascicles of spindle cell with no atypia (HE stain, ob. x 40)

**Figure 5:** GIST: strong positive CD117 immunostaining (ob. x 40)

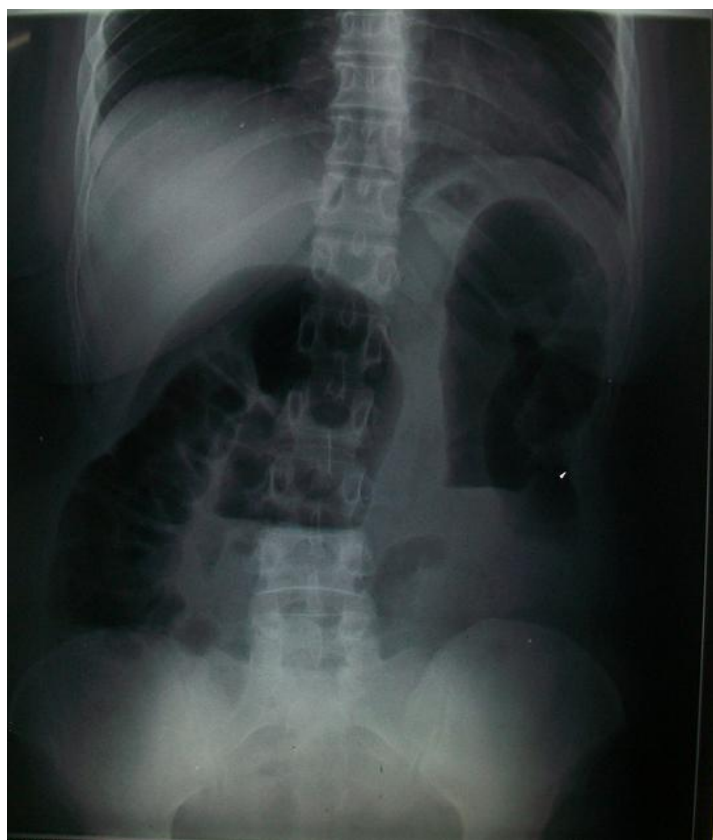**Figure 6:** GIST: CD34 positivity (ob. x 40)

## References

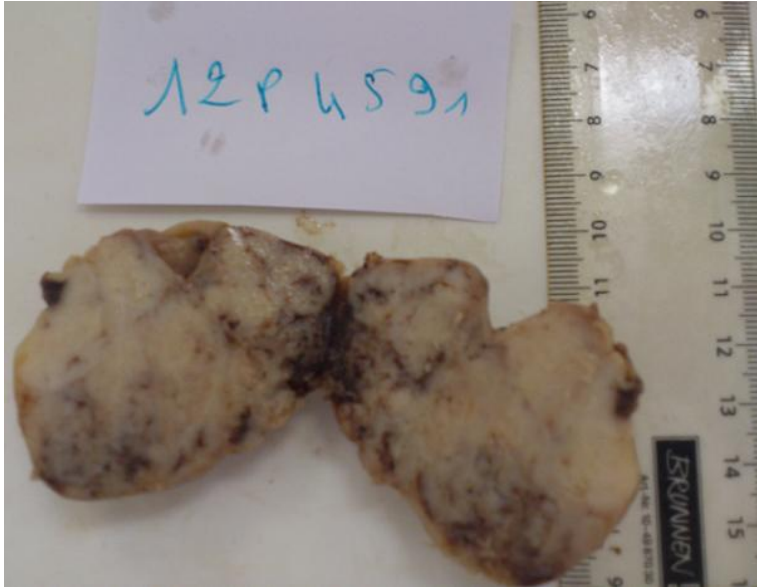---

1. Theodosopoulos T, Dellaportas D, Psychogiou V, Gennatas K, Kondi-Pafiti A, Gkiokas , Papaconstantinou I, Polymeneas G. Synchronous gastric adenocarcinoma and gastrointestinal stromal tumor (GIST) of the stomach: a case report. *World J Surg Oncol.* 2011 May 26;9:60. **PubMed | Google Scholar**
2. Miranda ME, Alberti LR, Tatsuo ES, Piçarro C, Rausch M. Gastrointestinal stromal tumor of the stomach in a child with a 3-year follow-up period: Case report. *Int J Surg Case Rep. Int J Surg Case Rep.* 2011;2(6):114-7. **PubMed | Google Scholar**
3. Wronski M, Ziarkiewicz-Wroblewska B, Gornicka B, Cebulski W, Slodkowski M, Wasiutynski A, Krasnodebski IW. Synchronous occurrence of gastrointestinal stromal tumors and other primary gastrointestinal neoplasms. *World J Gastroenterol.* 2006 Sep 7;12(33):5360-2. **PubMed | Google Scholar**
4. Nemes C, Rogoian L, Surdea-Blaga T, Seicean A, Dumitrascu DL, Ciuce C. Gastrointestinal Stromal Tumor (GIST) Associated with Synchronous Colon adenocarcinoma: a Case Report. *J Gastrointest Liver Dis.* 2012 Mar;21(1):101-3. **PubMed | Google Scholar**
5. Miettinen M, Lasota J. Gastrointestinal stromal tumors: review on morphology, molecular pathology, prognosis and differential diagnosis. *Arch Pathol Lab Med.* 2006 Oct;130(10):1466-78. **PubMed | Google Scholar**
6. Corless CL, Fletcher JA, Heinrich MC. Biology of gastrointestinal stromal tumors. *J Clin Oncol.* 2004 Sep 15;22(18):3813-25. **PubMed | Google Scholar**
7. Neves LR, Oshima CT, Artigiani-Neto R, Yanaguibashi G, Lourenço LG, Forones NM. Ki67 and p53 in gastrointestinal stromal tumors– GIST. *Arq Gastroenterol.* 2009 Apr-Jun;46(2):116-20. **PubMed | Google Scholar**
8. Urbanczyk K, Limon J, Korobowicz E, Chosia M, Sygut J, Karcz D, Iwanik K, Osuch C, Lasota J, Stachura J. Gastrointestinal stromal tumors: a multicenter experience. *Pol J Pathol.* 2005;56(2):51-61. **PubMed | Google Scholar**
9. Agaimy A, Wünsch PH, Sobin LH, Lasota J, Miettinen M. Occurrence of other malignancies in patients with gastrointestinal stromal tumors. *Semin Diagn Pathol.* 2006 May;23(2):120-9. **PubMed | Google Scholar**
10. Maiorana A, Fante R, Cesinario AM, Fano RA. Synchronous occurrence of epithelial and stromal tumors in the stomach: a report of 6 cases. *Arch Pathol Lab Med.* 2000 May;124(5):682-6. **PubMed | Google Scholar**
11. Cherian MG, Jayasurya A, Bay BH. Metallothioneins in human tumors and potential roles in carcinogenesis. *Mutat Res.* 2003 Dec 10;533(1-2):201-9. **PubMed | Google Scholar**

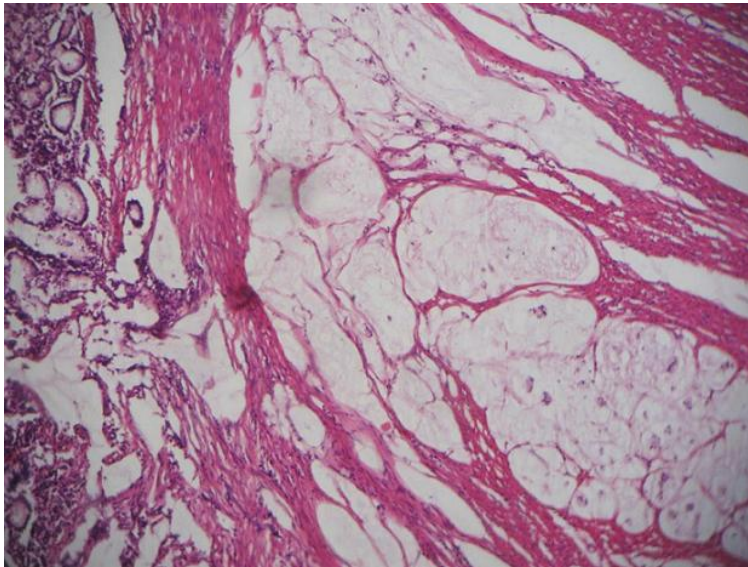
12. Pedersen M, Larsen A, Stoltenberg M, Penkowa M. The role of metallothionein in oncogenesis and cancer prognosis. *Prog Histochem Cytochem.* 2009;44(1):29-64. **PubMed | Google Scholar**
13. Thirumoorthy N, Shyam Sunder A, Manisenthil Kumar K, Senthil Kumar M, Ganesh G, Chatterjee M. A review of metallothionein isoforms and their role in pathophysiology. *World J Surg Oncol.* 2011 May 20;9:54. **PubMed | Google Scholar**
14. Sugimura T, Fujimura S, Baba T. Tumor production in the glandular stomach and alimentary tract of the rat by N-methyl-N'-nitro-N-nitrosoguanidine. *Cancer Res.* 1970 Feb;30(2):455-65. **PubMed | Google Scholar**
15. Cohen A, Geller SA, Horowitz I, Toth LS, Werther JL. Experimental models for gastric leiomyosarcoma: the effects of N-methyl-N'-nitro-N-nitrosoguanidine in combination with stress, aspirin, or sodium taurocholate. *Cancer.* 1984 Mar 1;53(5):1088-92. **PubMed | Google Scholar**



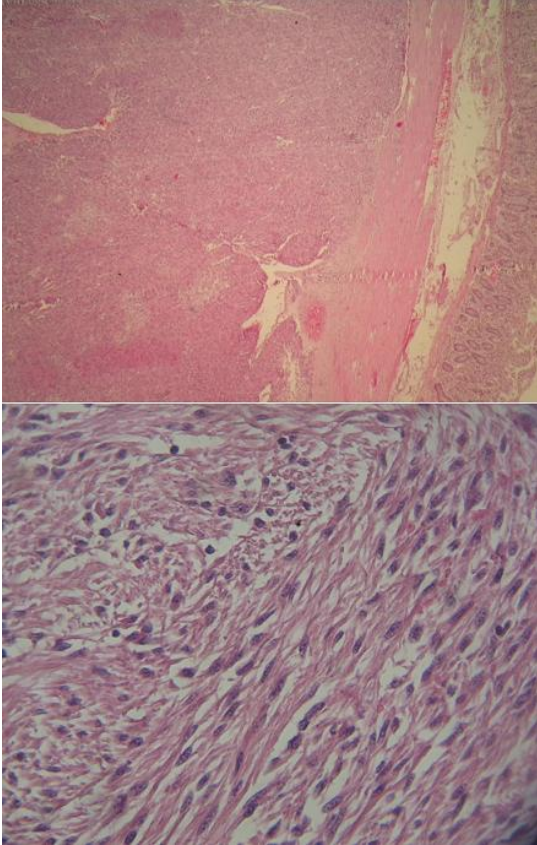
**Figure 1:** Abdominal X-ray showing the presence of air-fluid levels



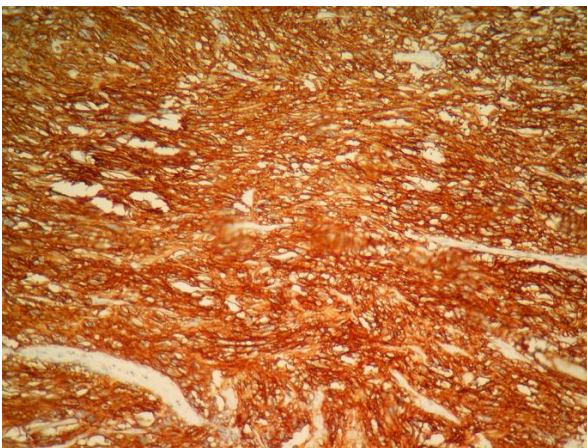
**Figure 2:** Macroscopic appearance of GIST in small bowel diverticulum



**Figure 3:** Mucinous adenocarcinoma of the sigmoid (HE stain, ob. x 20)

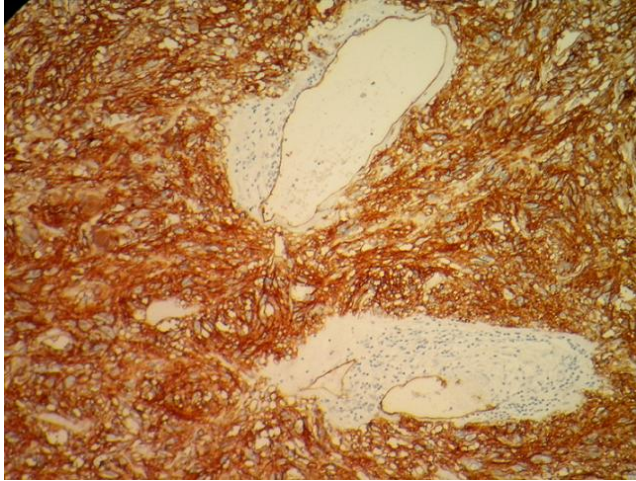


**Figure 4:** fusiform low grade GIST: (A) invasion of submucosa of small intestine from GIST (HE stain, ob. x 10); (B) the GIST was composed of fascicles of spindle cell with no atypia (HE stain, ob. x 40)



**Figure 5:** GIST: strong positive CD117 immunostaining (ob. x 40)





**Figure 6:** GIST: CD34 positivity (ob. x 40)