

## Case report

### Paravertebral extraskeletal myxoid chondrosarcoma: a case report and review of the literature

**Fatima Zahra Farhane<sup>1,\*</sup>, Zineb Alami<sup>1</sup>, Touria Bouhafa<sup>1</sup>, Abderrahmane Elmazghi<sup>1</sup>, Khalid Hassouni<sup>1</sup>**

<sup>1</sup>Department of Radiotherapy, Hassan II University Hospital, Fez, Morocco

<sup>\*</sup>Corresponding author: Fatima Zahra Farhane, Department of Radiotherapy, Hassan II University Hospital, Fez, Morocco

Key words: Extraskeletal myxoid chondrosarcoma, paravertebral, malignant tumour

Received: 21/03/2015 - Accepted: 10/04/2015 - Published: 23/07/2015

#### Abstract

The extraskeletal myxoid chondrosarcoma (CME) is a rare malignant soft tissue tumour described as a distinct clinical, histological, immunohistochemical, genetical and evolutive entity. It represents only 2.5% of soft tissue sarcomas. Its individualization is important because it has a long and indolent clinical course, and tumour-related death often occurs after a long survival period. The diagnostic key is morphological supported by immunohistochemistry and genetics t (9; 22) that allow differentiating it from other tumours with myxoid stroma and from chordoma. This report describes a patient with paravertebral extraskeletal myxoid chondrosarcoma with a high locoregional extension.

**Pan African Medical Journal. 2015; 21:213 doi:10.11604/pamj.2015.21.213.6639**

This article is available online at: <http://www.panafrican-med-journal.com/content/article/21/213/full/>

© Fatima Zahra Farhane et al. The Pan African Medical Journal - ISSN 1937-8688. This is an Open Access article distributed under the terms of the Creative Commons Attribution License (<http://creativecommons.org/licenses/by/2.0>), which permits unrestricted use, distribution, and reproduction in any medium, provided the original work is properly cited.

## Introduction

---

Extraskelatal chondrosarcomas were first described by Stout and Verner in 1953 [1]; however, it was not until 1972 that extraskelatal myxoid chondrosarcoma (EMC) was histopathologically defined as its own entity [2]. EMC is provisionally classified as a tumor of uncertain differentiation in the revised version of the World Health Organization classification of tumors of soft tissue and bone in 2002 [3]. EMC is a relatively rare but well- characterized tumor [4]. We report a case of paraspinal location with a high locoregional extension.

## Patient and observation

---

A 25-year-old female presenting with 3 months history of cauda equina syndrome progressively worsening. Lumbar spine medical imaging revealed in MRI scan a low signal intensity process on T1 a high signal intensity on T2 (**Figure 1**) and in CT scan a hypodense process extending on a height of 7cm and developing in the left posterior lumbar soft tissues at the height of L5 extending in the left sacral region with infiltration and osteolysis of the sacroiliac joint and the left sacral foramina with nerve root compression at this level. The patient underwent surgery with resection of a left paravertebral lesion + L5 and S1 laminectomy + partial resection of the intraductal portion of the tumor. Histopathological study showed that the tumor is characterized by multilobular structures divided by fibrous septa, and disposed in an abundant myxoid matrix. tumoral cells are isolated or grouped in cords, mitoses are rare. Cells express the protein S100 and NSE and do not express cytokeratin AE1 / AE3 and desmin. Based on these findings, the patient was diagnosed with EMC. Postoperative Spinal MRI showed the persistence of a large tumor mass of the erector muscles of the lumbar spine 68x12mm extending to the gluteal muscles, with persistence of the anterior epidural tumoral component and extension at lumbosacral spinal (**Figure 2**). At his admission to the department of radiotherapy, 4 weeks later, clinical examination found a huge mass in the left buttock and posterior lumbar region. Planning CT and CT scanner found an increase in tumor volume with the same extensions described in the postoperative imaging in addition to extension at the left iliac bone and at the left iliac psoas muscle protruding at the left lateral pelvic region. From these results, a palliative radiotherapy was delivered in the total dose of

20 Gy in 5 fractions of 4Gy. The patient was referred for chemotherapy thereafter.

## Discussion

---

The CME is a rare entity, distinct clinically, histologically, immunohistochemistry, cytogenetics and scalable. It represents 2.5% of soft tissue sarcomas [5]. Approximately 80% of these tumors occur in the extremities, with 20% located in the trunk. The lower extremity is the most common location of EMC [4]. The male to female ratio of EMC is 2:1, with a peak occurrence in the fifth and sixth decades [4]. EMC is a relatively rare neoplasm with no specific findings in the clinic. Patients commonly present with non-specific symptoms, including tenderness and the detection of a palpable mass [3]. The most common manifestation of EMC is an enlarging soft tissue mass; some lesions are accompanied by pain and tenderness, or may restrict the range of motion. Radiological images are not specific; the lesions exhibit low density on CT, low signal intensity on T1-weighted MRI scans and high signal intensity on T2-weighted MRI scans [6]. The tumor ranges from approximately 1-25 cm (mostly 6-13 cm) in size and usually has a multilobular or nodular configuration with a relatively well-defined margin and an incomplete fibrous capsule [2,5,7-12]. The cut surface is gray to tan-brown and shows a gelatinous appearance, often accompanied by intralesional hemorrhage. The tumor is characterized by multilobular structures divided by fibrous septa of variable thickness, which is a consistent morphological configuration of EMC. Each lobule is typically composed of a proliferation of short spindle or oval cells arranged in clusters or short anastomosing cords or strands, often displaying a lacelike appearance and embedded in an abundant myxoid matrix. The tumor cells are generally small and have hyperchromatic or vesicular nuclei and eosinophilic or sometimes vacuolated cytoplasm. These features are somewhat reminiscent of chondroid tissues or lesions. However, the tumor usually lacks discernible cartilaginous histology. Mitotic figures are rare in most cases [5].

Immunohistochemically, the cells express vimentin sometimes SNP, NSE and PS100 [11,5]. Cytokeratin and EMA are sometimes expressed focal manner [11]. Positivity of GFAP was reported. In electron microscopy, the presence of parallel microtubules and abundant REG are quite characteristic but nonspecific [9,13]. Certain studies have shown that they may also be positive for Leu-7

and epithelial membrane antigen. Uniformly, they are negative for keratin, SMA and desmin [14-16]. Genetically, CME is associated in about 80% to recurrent specific chromosome translocation t (9; 22) (q22; q12), leading to a genetic rearrangement between the EWS gene, located on chromosome 22 and the gene TEC, located on chromosome 9 [11]. The rearrangement can be searched by RT-PCR on fixed tissue. Other translocations are rarely observed [5]: t (9; 15) (q22; q12), t (9; 17) (q22; q11.2), t (9; 17; 15) (q22; q11 ; q22), t (2; 13) (q32; p12) and t (11; 22) (q11; p11) [17].

EMCS should be distinguished from a variety of myxoid or cartilage-forming, benign, or malignant, and soft tissue or bone tumors. For example, intramuscular myxoma, nerve sheath myxoma/neurothekeoma, extraskeletal chondroma, myoepithelioma (mixed tumor) of soft parts, parachordoma, metastatic adenocarcinoma, myxoid liposarcoma, low-grade myxofibrosarcoma/myxoid malignant fibrous histiocytoma, epithelioid sarcoma, malignant peripheral nerve sheath tumor, and extraskeletal or skeletal chondrosarcoma with prominent myxoid change. Among them, parachordoma and myoepithelioma of soft parts are occasionally difficult to differentiate from EMCS. Recognition of the histologic features of conventional EMCS that are present, at least in part, is most important for a differential diagnosis. Ancillary approaches such as immunohistochemistry and electron microscopy are also valuable [5]. Treatment is firstly surgery of the initial tumor and / or metastasis, radiotherapy and chemotherapy as first-line have not been proven [18]. This tumor does not respond to chemotherapy and the results concerning radiotherapy are discordant [19].

The development of CMES is difficult to predict. Nearly half of patients have one or more local recurrences within an average of 44 months [20]. Survival after the onset of metastases is very varied in duration, on average 66 months. Although the five-year survival rate is quite high, metastases are common (46-90% of cases) and long-term prognosis is adverse (30-70% survival at ten years) [20,21]. Metastases occur in order of decreasing frequency, in lungs, soft tissue, lymph nodes, bone, and brain. The main poor prognostic factors are the occurrence in man, the late age of onset, tumor size greater than 10 cm, proximal seat, the incompleteness of the initial surgical resection, the absence of surgical resection and discovery of metastases at diagnosis [11,20]. The histoprognostic criteria such as necrosis, mitotic activity, the degree of differentiation does not appear to influence the outcome [22]. In

fact, these criteria are discordant in the literature and are controversial subjects.

---

## Conclusion

The CME is a rare entity, distinct clinically, histologically, immunohistochemistry, cytogenetics and scalable. The diagnostic key is morphological, aided by immunohistochemistry and genetic study.

---

## Competing interests

The authors declare no competing interests.

---

## Authors' contributions

All authors read and approved the final version of the manuscript.

---

## Figures

**Figure 1:** Preoperative MRI shows lesion with low signal in T1WI and heterogeneous high signal in T2WI

**Figure 2:** Postoperative MRI shows lesion with low signal in T1WI and heterogeneous high signal in T2WI

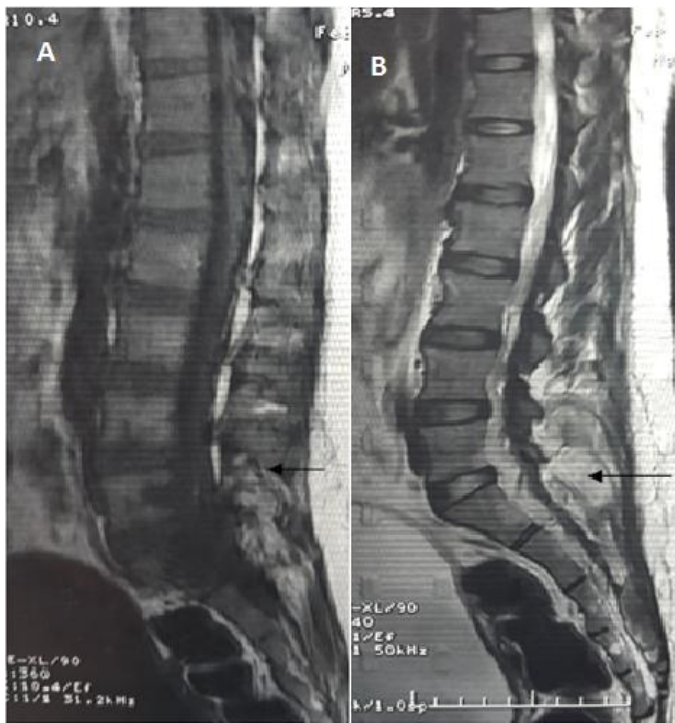
---

## References

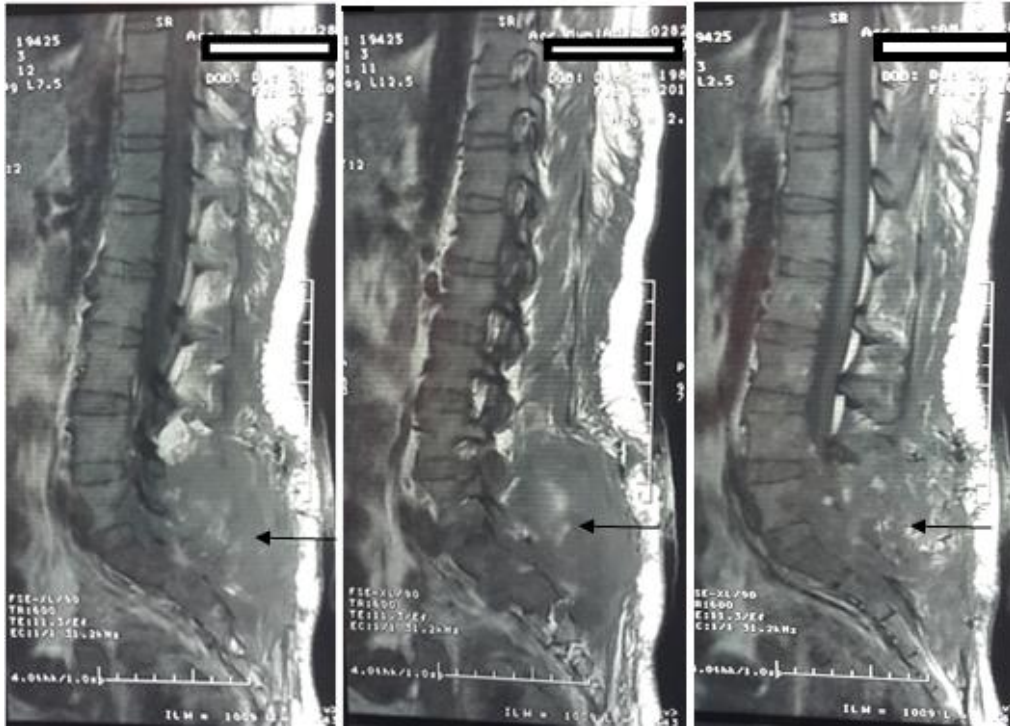
1. Stout AP, Verner EW. Chondrosarcoma of the extraskeletal soft tissues. *Cancer*. 1953 May; 6(3): 581-90. **PubMed | Google Scholar**
2. Enzinger FM, Shiraki M. Extraskeletal myxoid chondrosarcoma: an analysis of 34 cases. *Hum Pathol*. 1972 Sep; 3(3): 421-35. **PubMed | Google Scholar**

3. Hisaoka M, Hashimoto H. Extraskeletal myxoid chondrosarcoma: updated clinicopathological and molecular genetic characteristics. *Pathol Int.* 2005 Aug; 55(8): 453-63. **PubMed | Google Scholar**
4. Smith MT, Farinacci CJ, Carpenter HA, Bannayan GA. Extraskeletal myxoid chondrosarcoma: a clinicopathological study. *Cancer.* 1976 Feb; 37(2): 821-7. **PubMed | Google Scholar**
5. Okamoto S, Hisaoka M, Ishida T et al. Extraskeletal myxoid chondrosarcoma: a clinicopathologic, immunohistochemical, and molecular analysis of 18 cases. *Hum Pathol.* 2001 Oct; 32(10): 1116-24. **PubMed | Google Scholar**
6. Gebhardt MC, Parekh SG, Rosenberg AE, Rosenthal DI. Extraskeletal myxoid chondrosarcoma of the knee. *Skeletal Radiol.* 1999 Jun; 28(6): 354-8. **PubMed | Google Scholar**
7. Meis-Kindblom JM, Bergh P, Gunterberg B, Kindblom L-G. Extraskeletal myxoid chondrosarcoma: a reappraisal of its morphological spectrum and prognostic factors based on 117 cases. *Am J Surg Pathol.* 1999 Jun; 23(6): 636-50. **PubMed | Google Scholar**
8. Antonescu CR, Argani P, Erlandson RA, Healey JH, Ladanyi M, Huvos AG. Skeletal and extraskeletal myxoid chondrosarcoma: a comparative clinicopathological, ultrastructural, and molecular study. *Cancer.* 1998 Oct 15; 83(8): 1504-21. **PubMed | Google Scholar**
9. Lucas DR, Heim S. Extraskeletal myxoid chondrosarcoma. In: Fletcher CDM, Unni K, Martens F, eds. *World Health Organization Classification of Tumour, Pathology and Genetics of Tumours of Soft Tissue and Bone.* Lyon: IARC Press, 2002; 213-15. **Google Scholar**
10. Weiss SW, Goldblum JR. Extraskeletal myxoid chondrosarcoma. In: Weiss SW, Goldblum JR, eds. *Enzinger and Weiss's Soft Tissue Tumors*, 4th edn. St Louis: Mosby, 2001; 1368-78. **Google Scholar**
11. Oliveira AM, Sebo TJ, McGrory JE, Gaffey TA, Rock MG, Nascimento AG. Extraskeletal myxoid chondrosarcoma: a clinicopathological, immunohistochemical, and ploidy analysis of 23 cases. *Mod Pathol.* 2000 Aug; 13(8): 900-8. **PubMed | Google Scholar**
12. Kawaguchi S, Wada T, Nagoya S et al. Extraskeletal myxoid chondrosarcoma: a multi-institutional study of 42 cases in Japan. *Cancer.* 2003 Mar 1; 97(5): 1285-92. **PubMed | Google Scholar**
13. Kempson RL, Fletcher CDM, Evans HL et al (2001) Extraskeletal myxoid chondrosarcoma. *Tumours of soft tissue AFIP:* 400-5. **Google Scholar**
14. Wick MR, Burgess JH, Manivel JC. A reassessment of "chordoid sarcoma"; Ultrastructural and immunohistochemical comparison with chordoma and skeletal myxoid chondrosarcoma. *Mod Pathol.* 1988 Nov; 1(6): 433-43. **PubMed | Google Scholar**
15. Suzuki T, Kaneka H, Kojima K, Takatoh M, Hasebe K. Extraskeletal myxoid chondrosarcoma characterized by microtubular aggregates in the rough endoplasmic reticulum and tubulin immunoreactivity. *J Pathol.* 1988; 156: 51-57. **PubMed | Google Scholar**
16. Guo-Wei Zhang, Ai-Jie Wang, Guang-Hui Zhang, Shan-Na Zhao, Jian-Li Qu. Extraskeletal myxoid chondrosarcoma: a report of two cases. *Oncol Lett.* 2014 Apr; 7(4): 1289-1291. **PubMed | Google Scholar**
17. Oukabli M, Boudhas A, Qamouss O, Charhi H, Mansouri N, Rimani M, Albouzidi A. Extraskeletal myxoid chondrosarcoma of the knee: a clinicopathologic and immunohistochemical analysis of a case. *J Afr Cancer.* 2010; 2: 285-288. **PubMed | Google Scholar**
18. Patel SR, Burgess MA, Papadopoulos NE, Linke KA, Benjamin RS. Extraskeletal myxoid chondrosarcoma: long-term experience with chemotherapy. *Am J Clin Oncol.* 1995 Apr; 18(2): 161-3. **PubMed | Google Scholar**

19. Saint-Blancard P, Jancovici R, Ceccaldi B, Lagace R, Sastre-Garau X. Extraskeletal myxoid chondrosarcoma of the neck: report of a case with lymph nodes metastasis. *Rev Med Interne*. 2006 Feb; 27(2): 160-2, Epub 2005 Nov 10. **PubMed | Google Scholar**
20. Meis-Kindblom JM, Bergh P, Gunterberg B, Kindblom L-G. Extraskeletal myxoid chondrosarcoma: a reappraisal of its morphologic spectrum and prognostic factors based on 117 cases. *Am J Surg Pathol*. 1999 Jun; 23(6): 636-50. **PubMed | Google Scholar**
21. McGrory JE, Rock MG, Nascimento AG, Oliveira AM. Extraskeletal myxoid chondrosarcoma. *Clin Orthop*. 2001 Jan; (382): 185-90. **PubMed | Google Scholar**
22. Algros M-P, Collonge-Rame M-A, Bedgejian I, Tropet Y, Delattre O, Kantelip B. Différenciation neuroectodermique des chondrosarcomes extrasquelettiques myxoïdes : un classique? *Ann Pathol*. 2003 Jun; 23(3): 244-8. **PubMed | Google Scholar**



**Figure 1:** Preoperative MRI shows lesion with low signal in T1WI and heterogeneous high signal in T2WI



**Figure 2:** Postoperative MRI shows lesion with low signal in T1WI and heterogeneous high signal in T2WI