

## Case report

### Leiomyoma: a case report of a rare benign tumor of the female urethra

**Amine Slaoui<sup>1&</sup>, Abdelouahed Lasri<sup>1</sup>, Tarik Karmouni<sup>1</sup>, Khalid Elkhader<sup>1</sup>, Abdelatif Koutani<sup>1</sup>, Ahmed Ibn Attaya<sup>1</sup>**

<sup>1</sup>Urology B, Ibn Sina, University Hospital, Rabat, Morocco

<sup>&</sup>Corresponding author: Amine Slaoui, Urology B, Ibn Sina, University Hospital, Rabat, Morocco

Key words: Leiomyoma, smooth muscle, tumor, urethra

Received: 23/08/2015 - Accepted: 30/09/2015 - Published: 08/10/2015

#### Abstract

Leiomyoma is a benign smooth muscle tumor which is rarely found in urethra. It often appears in females during their reproductive age (from menarche to menopause); the mean age of their appearance is approximately 41 years. Less than 100 cases were reported in the literature. We hereby report a case of a 52-year-old White woman who presented with complaints of dysuria and urinary tract infection. The mass was completely removed by transvaginal excision with a rim of normal tissue. Histopathological studies confirmed the urethral leiomyoma. The patient remained asymptomatic and there was no evidence of recurrence in the followup.

**Pan African Medical Journal. 2015; 22:111 doi:10.11604/pamj.2015.22.111.7785**

This article is available online at: <http://www.panafrican-med-journal.com/content/article/22/111/full/>

© Amine Slaoui et al. The Pan African Medical Journal - ISSN 1937-8688. This is an Open Access article distributed under the terms of the Creative Commons Attribution License (<http://creativecommons.org/licenses/by/2.0>), which permits unrestricted use, distribution, and reproduction in any medium, provided the original work is properly cited.

## Introduction

---

Leiomyoma is a benign smooth muscle tumor which is rarely found in urethra. [1]. It often appear in females during their reproductive age (from menarche to menopause); the mean age of their appearance is approximately 41 years [2]. Less than 100 cases were reported in the literature [3].

## Patient and observation

---

We hereby report a case of a 52-year-old White woman who presented with complaints of dysuria and urinary tract infection and feeling of nodulation in her vagina for the last 3 years. Her medical history revealed that she had no chronic disease. On physical examination, we detected a 2 × 2,5 cm painless hard tumor without signs of inflammation. Blood biochemistry and hemogram were within normal limits. Urinalysis was normal. The MRI revealed normal kidneys and large capacity bladder, with a mass located in the proximal third of the urethra and measuring 19x18 mm (**Figure 1, Figure 2, Figure 3**). The mass was completely removed by transvaginal excision with a rim of normal tissue (**Figure 4**). The urethral mucosa was intact. Patient was catheterized for 48 hours and voided well on catheter removal. Histopathological studies confirmed the urethral leiomyoma. The patient remained asymptomatic and there was no evidence of recurrence in the followup.

## Discussion

---

Buttner described the first case of leiomyoma on 1894. Although mostly observed in females of childbearing age, no age or gender is exempt [3]. Leiomyomas are benign tumors of the smooth muscles. They tend to be relatively common in the genitourinary and gastrointestinal tracts, the occurrences are less frequent in the skin and rare in the deep tissues. In general, soft tissue leiomyomas cause little morbidity. Leiomyomas can be classified under three categories: cutaneous leiomyoma (leiomyoma cutis), angiomyomas (vascular leiomyomas), and leiomyomas of deep soft tissue [1]. Urethral leiomyomas are, in fact, classified under leiomyomas of deep soft tissue and are rare benign mesenchymal tumors that originate from the smooth muscle of the urethra [4]. Leiomyoma of the urethra affects women more often than men [5]. It often appear in females during their reproductive age (from menarche to menopause); the mean age of their appearance is approximately 41 years [3]. Distal urethra can be affected but proximal segment is the most common site [6]. Urinary tract infection, a mass, dyspareunia, urinary retention, and irritative lower urinary tract symptoms are the most commonly reported symptoms. The tumor has been reported to enlarge during pregnancy and shrink after delivery, suggesting a possible hormonal dependence [7]. The differential diagnosis is represented by urethrocele, a urethral diverticulum, caruncle, and malignancy. To distinguish the differential diagnosis of urethral leiomyoma a careful clinical examination, urethroscopy, and radiological examination of the lower urinary tract are essential. However a pathological examination of the surgical pieces is mandatory not to disregard a neoplastic involvement. MRI may also help [8]. It is important to remember that no malignant transformation or recurrence have been reported. The treatment of choice is a local surgical resection [9].

## Conclusion

---

Leiomyoma is a benign smooth muscle tumor which is rarely found in urethra. It often appear in females during their reproductive age. A careful clinical examination, urethroscopy, and radiological examination of the lower urinary tract are essential. The treatment of choice is a local surgical resection. However a pathological examination of the surgical pieces is mandatory not to disregard a neoplastic involvement.

## Competing interests

---

Written consent was taken from the patient for publication of the paper. The authors also disclose that there is no conflict of interests.

## Authors' contributions

---

All authors read and agreed to the final version of this manuscript and equally contributed to its content and to the management of the case.

## Figures

---

**Figure 1:** Sagittal section of a pelvic MRI showing a urethral leiomyoma

**Figure 2 :**Coronal section of a pelvic MRI showing a urethral leiomyoma

**Figure 3 :** Cross section of a pelvic MRI showing a urethral leiomyoma

**Figure 4 :** Surgical specimen after procedure

## References

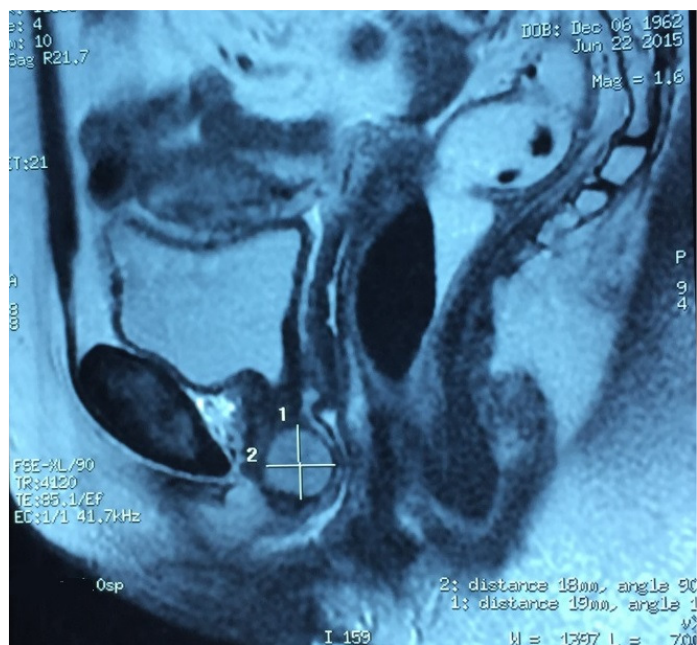
---

1. Rivière P, Bodin R, Bernard G, Deligne E, Peyromaure M, Ponties JE. Leiomyoma of the female urethra. *Prog Urol.* 2004 Dec;14(6):1196-8. **PubMed | Google Scholar**
2. Chong KM, Chuang j, Tsai Y L, Hwang JL. A rapidly growing paraurethral myoma with profuse bleeding from a mucosal vessel: report of a case. *GynecolObstet Invest.* 2006;61(2):87-9. **PubMed | Google Scholar**
3. Pahwa M, Saifee Y, Pahwa AR, Gupta M. Leiomyoma of the female urethra-a rare tumor: case report and review of the literature. *Case RepUrol.* 2012;2012:280816. **PubMed | Google Scholar**
4. Dioszeghy F, Kiss A, Kondas J. Leiomyoma of the female urethra. *Int Urol Nephrol.* 1998;30(5):603-7. **PubMed | Google Scholar**
5. Goldman HB, McAchran SE, MacLennan GT. Leiomyoma of the urethra and bladder. *J Urol.* 2007 May;177(5):1890. **PubMed | Google Scholar**
6. Lee MC, Lee SD, Kuo HT, Huang TW. Obstructive leiomyoma of the female urethra: report of a case. *J Urol.* 1995 Feb;153(2):420-1. **PubMed | Google Scholar**

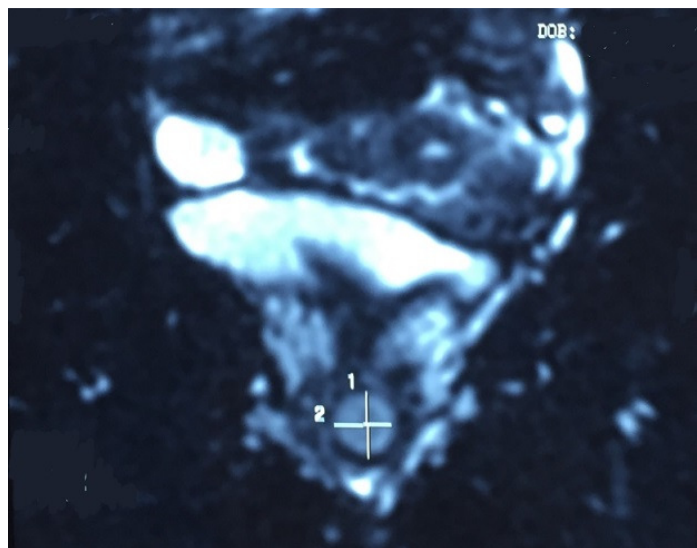
7. Fry M, Wheeler JS, Mata JA Jr, Culkin DJ, St Martin E, Venable DD. Leiomyoma of the female urethra. *J Urol.* 1988 Sep;140(3):613-4. **PubMed** | **Google Scholar**

8. Pavlica P, Bartolone A, Gaudiano C, and Barozzi L. Female paraurethral leiomyoma: ultrasonographic and magnetic resonance imaging findings. *Acta Radiol.* 2004 Nov;45(7):796-8. **PubMed** | **Google Scholar**

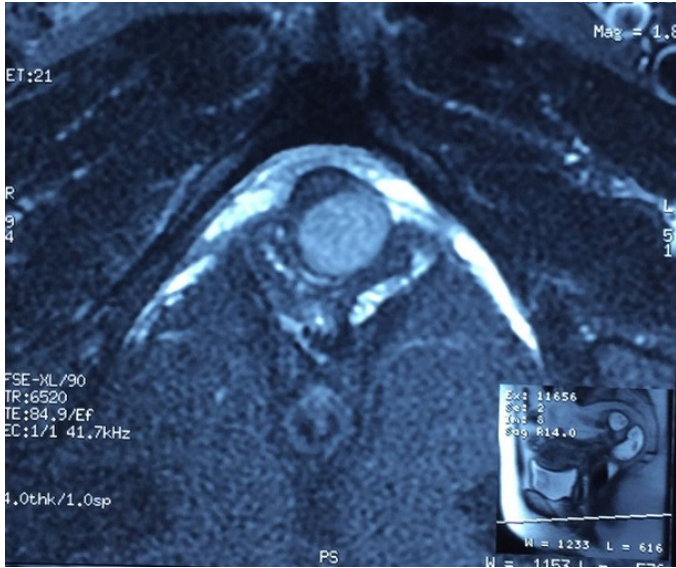
9. Deka PM and Rajeev TP. Leiomyoma of the female urethra: a case report. *Urol Int.* 2003;71(2):224-5. **PubMed** | **Google Scholar**



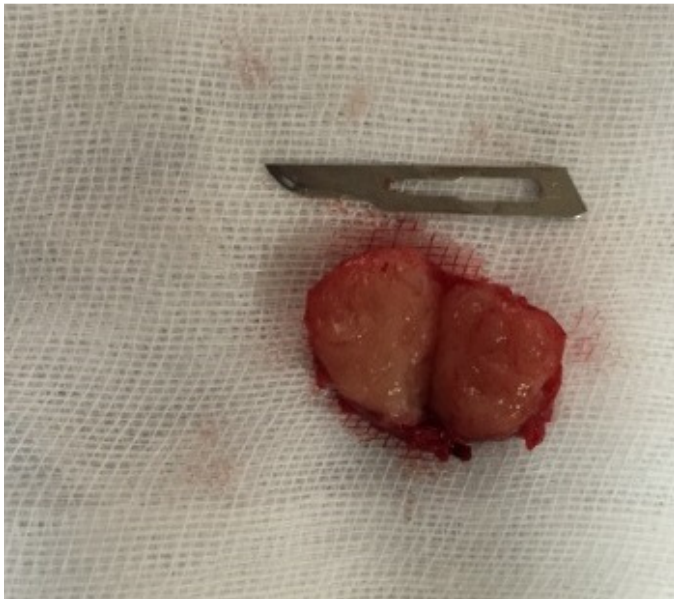**Figure 1:** Sagittal section of a pelvic MRI showing a urethral leiomyoma



**Figure 2 :** Coronal section of a pelvic MRI showing a urethral leiomyoma



**Figure 3 :** Cross section of a pelvic MRI showing a urethral leiomyoma



**Figure 4 :** Surgical specimen after procedure