

Case report

Melorheostosis: a rare entity: a case report

Abdelhakim Kherfani¹, Hachem Mahjoub^{1,&}

¹A Orthopedics adults surgery department, MT Kassab Institute, La Manouba, Tunisia

[&]Corresponding author: Hachem Mahjoub, Orthopedics adults surgery department, MT Kassab Institute, La Manouba, Tunisia

Key words: Melorheostosis, sclerotic bone dysplasias, CT, MRI

Received: 23/05/2014 - Accepted: 09/06/2014 - Published: 26/07/2014

Abstract

Melorheostosis is a rare entity belonging to the group of sclerotic bone dysplasias. Described for the first time in 1922 by Leri, it remains imperfectly known as clinical presentations are highly variable, and the etiological diagnosis is not fully elucidated. We report a case of polyostotic melorheostosis for which radiological investigations were complete, in order to study this disease.

Pan African Medical Journal. 2014; 18:251 doi:10.11604/pamj.2014.18.251.4661

This article is available online at: <http://www.panafrican-med-journal.com/content/article/18/251/full/>

© Hachem Mahjoub et al. The Pan African Medical Journal - ISSN 1937-8688. This is an Open Access article distributed under the terms of the Creative Commons Attribution License (<http://creativecommons.org/licenses/by/2.0>), which permits unrestricted use, distribution, and reproduction in any medium, provided the original work is properly cited.

Introduction

Melorheostosis is a rare benign non hereditary condition. It is known as a mesoderm sclerotic bone dysplasia, characterized by cortical hyperostosis with or without retraction of soft tissue. It was described for the first time in 1922 by Leri and Joanny as a dripping candle wax hyperostosis [1]. Since then, 300 cases have been reported in the literature. Its incidence is estimated 0.9 per million population [2]. It affects both men and women at any age. The locations are highly variable, and mono ostotic forms were more often described. Polyostotic forms localized to the lower limbs are rare. The disease can remain silent and be discovered incidentally. If not, symptoms are made of distortion, variable pain or limitation of joint mobility. It is a disease whose etiology is imperfectly understood, the genetic factors and metabolic predisposition or malformation of the vessels are proposed, but the exact cause is to be determined [3-5]. The diagnosis was facilitated by the recent imaging techniques, CT scan or better, the MRI that provides diagnostic certainty [6,7]. Scintigraphy can detect subclinical lesions and monitor its progress [6,7]. Therapeutic envisaged vary widely, depending on the discomfort and the localization.

Patient and observation

We report the case of a 39 years-old female, with no past medical history, whose complaint was a spontaneous one week evolving isolated left cruralgia. The clinical examination was unremarkable apart from an anterior thigh pain at the mobilization of the left hip. No quadriceps hypotrophy, no fever and no limitations in the joints motion were found. Plain radiographs of the pelvis and proximal femur showed hypercondensation of the medial cortex of the left femur below the calcar, the classic flowing candle wax, combined with condensation of the iliac side of the sacroiliac joints bilaterally (**Figure 1**). Lab tests were normal. The diagnosis of melorheostosis was raised and we completed the explorations by a whole body bone scan that showed increased uptake in the proximal left femur and both sacroiliacs. CT of the pelvis and left femur was performed and showed an hypercondensation in the medial cortex of the left femur, and a bilateral condensation of the iliac side of the sacroiliac joints (**Figure 2, Figure 3**). The patient was put under analgesics and nonsteroidal anti-inflammatory drugs, with improvement of symptoms from J3 of hospitalization. An MRI was performed and showed the same bone condensation without extensions to the soft

tissues (**Figure 4**). Given these findings, biopsy was not performed, and the patient was discharged to be followed in our consultation by standard radiographs every three months, and an annual bone scan. At last follow up, two years of the first consultation, two episodes of left cruralgia have been reported, and yielded by three days anti-inflammatory treatments. Scintigraphy (**Figure 5**) and plain radiographies remained similar to initial assessments.

Discussion

Melorheostosis is still an imperfectly known pathology and many questions remain unanswered. The role of a genetic predisposition has been suggested, but evidence does not yet exist considering that familial cases have not yet been reported. Its association with vascular sector malformations and some observations reported changes in skin pigmentation suggests that a mutation may be responsible [3-5].

In this rare disease, the clinical presentations are highly variable and locations are diverse. Both upper or lower limbs can be affected in addition to the axial skeleton. The lower limbs are affected more often than the upper limbs. Conventional imaging is very characteristic when it shows the flowing candle wax, but this aspect can be seen in other conditions such as osteomyelitis or bone tumor. In some presentations it may be lawful to biopsy and perform bacteriological examinations [7]. In the most common cases, imaging may be sufficient to make the diagnosis. Cross-sectional imaging is very essential: CT shows bone lesions with its classical aspects and quantifies it in the spatial planes [6,7] whereas MRI can describe the extension to the soft tissues and rule out possible differential diagnoses [6,7]. Bone scintigraphy has an important contribution in melorheostosis since it can detect subclinical lesions and monitor progress. It also allows to differentiate the developmental stages according to the intensity of the bone fixation [6,7]. We recommend monitoring by full body scans to detect any changes, especially since the evolution is unpredictable.

The therapeutic is not well codified. It is symptomatic in most cases, in order to control bone pain. Protocols based on Pamidronate [8] have been proposed and appear to improve symptoms but do not slow the progress. Surgery is indicated in cases where there is major axial deformation or consequent limitations of joint mobility.

It is not easy and a knowledge of soft tissues involvement is a prerequisite.

Conclusion

Melorheostosis is a rare, benign with chronic course, often with outbreaks interspersed with remissions. We emphasize the need to ensure the diagnosis by plane radiographies, CT scan or MRI. If any doubt, biopsy may be necessary. Scintigraphy is the best exploration for monitoring the disease. Treatment is symptomatic essentially, based on nonsteroidal anti-inflammatory. Surgery can have its place in large deformations and joint damage, but with great care.

Competing interests

The authors declare no competing interest.

Authors' contributions

All the authors have contributed to this manuscript in ways that comply to ICMJE authorship criteria. All the authors have read and approved the final version of the manuscript.

Figures

Figure 1: Flowing candle wax condensation in the proximal femur on a plane radiography, specific of the Leri's disease

Figure 2: CT scan showing condensation of the iliac sides of sacro iliac joints

Figure 3: The characteristic candle wax condensation of the proximal femur below the calcar in the CT scan

Figure 4: MRI on T2 sequence showing the condensation of the iliac side of the sacro iliac joints with no involvement of the joint nor the soft tissues

Figure 5: scintigraphy showing hyper fixation of the proximal femur and the sacro iliac joints

References

1. Leri A, Joanny J. Une affection non decrite des os: hyperostose «en coulee» sur toute la longueur d'un membre ou "melorheostose". Bull Mem Soc Med Hosp Paris. 1922; 46:1141-5. [PubMed](#) | [Google Scholar](#)
2. Clifford PD, Jose J. Melorheostosis. Am J Orthop (Belle Mead NJ). 2009; 38(7):360-1. [PubMed](#) | [Google Scholar](#)
3. Hellemans J, Preobrazhenska O, Willaert A, Debeer P, Verdonk PC, Costa T, et al. Loss-of function mutations in LEMD3 result in osteopoikilosis. Buschke-Ollendorff syndrome and melorheostosis. Nat Genet. 2004; 36(11):1213-8. [PubMed](#) | [Google Scholar](#)
4. Kessler HB, Recht MP, Dalinka MK. Vascular anomalies in association with osteodystrophies - a spectrum. Skeletal Radiol. 1983; 10(2):95-101. [PubMed](#) | [Google Scholar](#)
5. Kalbermatten NT, Vock P, Rüfenacht D, Anderson SE. Progressive melorheostosis in the peripheral and axial skeleton with associated vascular malformations: imaging findings over three decades. Skeletal Radiol. 2001; 30(1):48-52. [PubMed](#) | [Google Scholar](#)
6. Campbell CJ, Papademetriou T, Bonfiglio M. Melorheostosis: A report of the clinical, roentgenographic, and pathological findings in fourteen cases. J Bone Joint Surg Am. 1968; 50(7):1281-304. [PubMed](#) | [Google Scholar](#)
7. Suresh S, Muthukumar T, Saifuddin A. Classical and unusual imaging appearances of melorheostosis. Clin Radiol. 2010; 65(8):593-600. [PubMed](#) | [Google Scholar](#)
8. Saadallaoui Ben Hamida K, Ksontini I, Rahali H, Mourali S, et al. Atypical form of melorheostosis improved by pamidronate. Tunis Med. 2009; 87(3):204-6. [PubMed](#) | [Google Scholar](#)

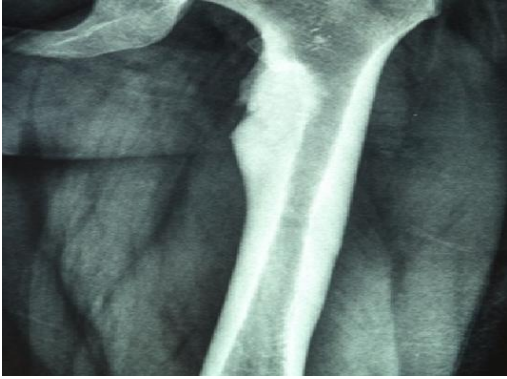

Figure 1: Flowing candle wax condensation in the proximal femur on a plane radiography, specific of the Leri's disease

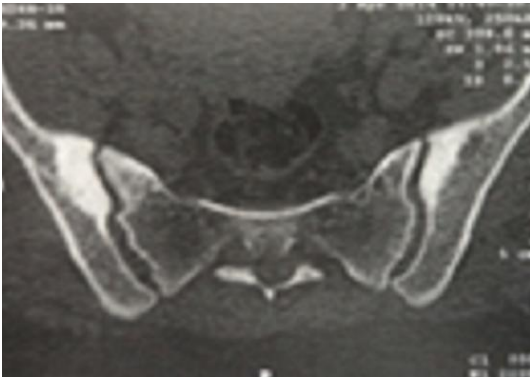

Figure 2: CT scan showing condensation of the iliac sides of sacro iliac joints

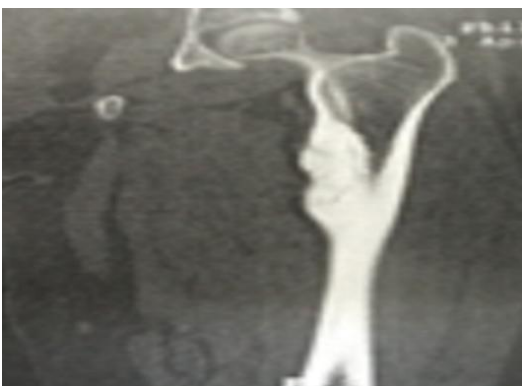

Figure 3: The characteristic candle wax condensation of the proximal femur below the calcar in the CT scan

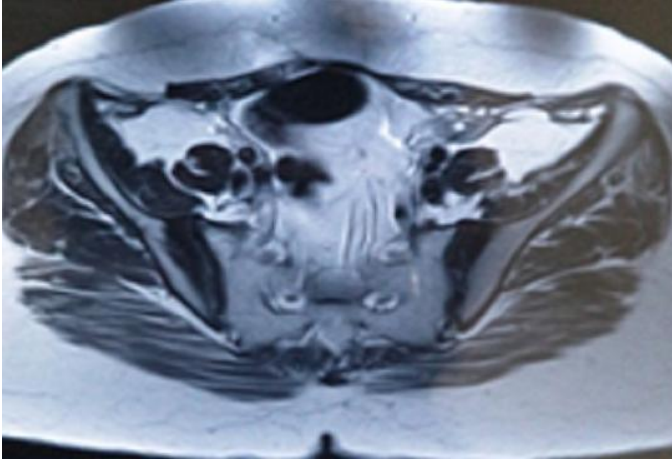


Figure 4: MRI on T2 sequence showing the condensation of the iliac side of the sacro iliac joints with no involvement of the joint nor the soft tissues

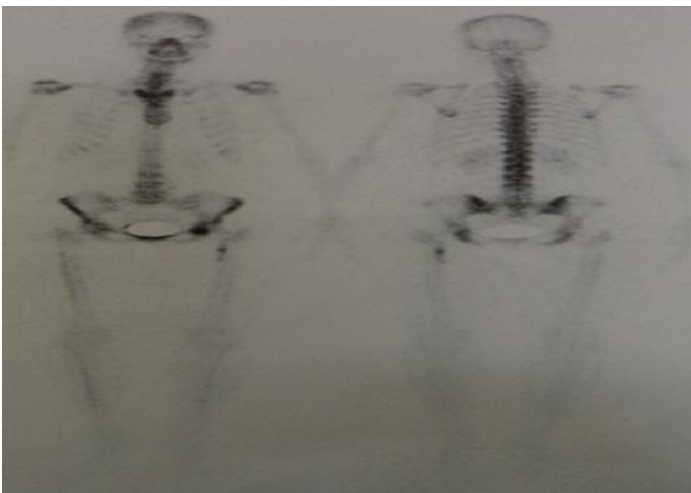

Figure 5: scintigraphy showing hyper fixation of the proximal femur and the sacro iliac joints