

Images in medicine

Skin metastasis of lung carcinoma

Krich Sanaa^{1,&}, Mernissi Fatima Zahra¹

¹Dermatological Department, Hassan II University Hospital, Fes, Morocco

[&]Corresponding author: Krich Sanaa, Dermatological Department, Hassan II University Hospital, Fes, Morocco

Key words: Metastasis, lung, cancer

Received: 17/04/2015 - Accepted: 29/04/2015 - Published: 07/05/2015

Pan African Medical Journal. 2015; 21:13 doi:10.11604/pamj.2015.21.13.6843

This article is available online at: <http://www.panafrican-med-journal.com/content/article/21/13/full/>

© Krich Sanaa et al. The Pan African Medical Journal - ISSN 1937-8688. This is an Open Access article distributed under the terms of the Creative Commons Attribution License (<http://creativecommons.org/licenses/by/2.0>), which permits unrestricted use, distribution, and reproduction in any medium, provided the original work is properly cited.

Image in medicine

A 61-year-old male was admitted to the hospital with tumors in the scalp (A), face (B), and neck (C) that had been present for four months with an acute decrease in visual acuity. These tumors have progressed to ulceration. Clinical examination observed although limited 3 lumps varying sizes from 1,5mm to 2 cm and ulcerated at the center. Dermoscopy was objective polymorphic vessels. The differential diagnosis of keratoacanthoma, epidermoid carcinoma, melanoma, primary adnexal tumour and skin infections was considered. Biopsies of the tumor in the scalp revealed moderately-differentiated epidermoid carcinoma, which were considered to be cutaneous metastases. Cerebral magnetic resonance imaging and thoracoabdominal pelvic scanner objectivated a tumoral mass of lung (D) with ocular, hepatica and bone metastasis. Lung biopsy was objectived a Squamous cell carcinoma. The diagnosis of Skin metastasis of lung carcinoma was made and he is currently under undergoing Chemotherapy. Cutaneous metastasis is caused by primary cancer-derived cells that grow in the skin. The diagnosis

of tumour metastatic to the skin is not usually difficult, but identification of the primary source of the metastasis can sometimes be a problem. According to the published literature, the incidence of cutaneous metastasis is 2.9-5.3% in general, and 1-12% for lung cancer. Certain cases may also manifest as erysipelas-like cancer, vascular dilation or bullous-like lesions, papules, plaques or scarring.

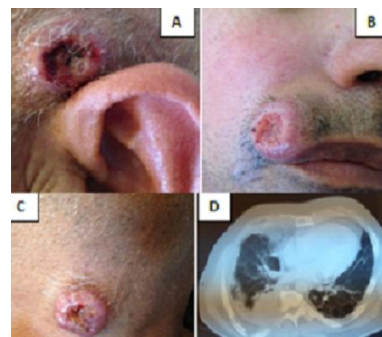


Figure 1: (A) ulcerated tumors in the scalp; (B) face; (C) neck; (D) tumoral mass of lung